

Image in cardiology

Myocardial perfusion improvement by preoperative intra-aortic balloon pump



Mejora de la perfusión miocárdica preoperatoria mediante balón de contrapulsación

Gabriella Locorotondo,* Domenico D'Amario, and Massimo Massetti

Dipartimento di Scienze Cardiovascolari, Fondazione Policlinico Universitario A. Gemelli IRCCS, Rome, Italy

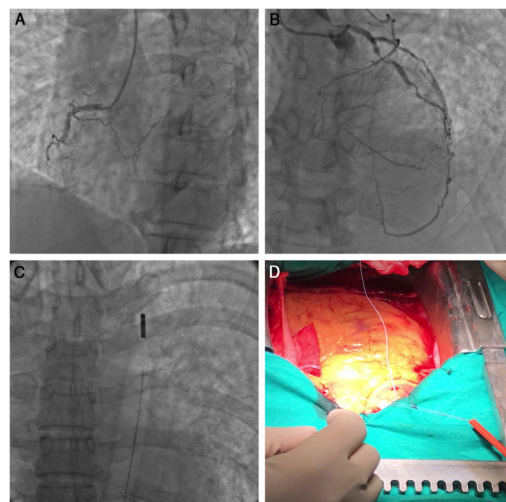


Figure 1.

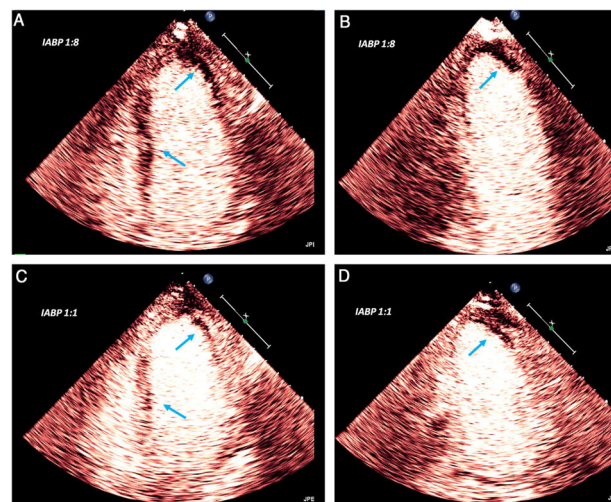


Figure 2.

Intra-aortic balloon pump (IABP) implantation increases myocardial blood supply. IABP use can be evaluated invasively via coronary blood flow or noninvasively via the microvascular perfusion of the sublingual region.

We report the novel use of myocardial contrast echocardiography in a patient admitted with cardiogenic shock after thrombolysis for acute myocardial infarction and with an allergy to aspirin. On admission, the patient's ST-segment elevation was > 50% lower than before thrombolysis. Echocardiography showed a left ventricular ejection fraction of 29% and moderate right ventricular dysfunction. Coronary angiography, performed 6 hours after myocardial infarction onset, revealed subocclusion of the first diagonal branch, which was judged to be the culprit lesion and which provided collateral circulation to chronic occlusions of both the right coronary (figure 1A) and anterior descending (figure 1B) arteries.

We performed coronary artery bypass grafting with preoperative IABP (figure 2C). Dopamine was started, and myocardial contrast echocardiography was performed at the bedside using only 2 mL of ultrasound contrast agent. The gain setting was adjusted and kept constant throughout the study. With IABP transiently set at a 1:8 counterpulsation rate, a complete transmurular perfusion defect was observed in the lateral and anterior apex and extending to the subendocardium of the anterolateral wall, in addition to a patchy transmurular perfusion defect of the interventricular septum (figure 2A,B, arrows). An increase in the counterpulsation rate to 1:1 significantly ameliorated the perfusion defect, which persisted only in the subendocardium within the lateral and anterior apex (figure 2C,D, arrows). Coronary artery bypass grafting was successfully performed 5 days after IABP implantation (figure 1D) and the patient achieved normal right ventricular function and a left ventricular ejection fraction of 38%.

ACKNOWLEDGMENTS

We thank L. Galiuto for providing training in myocardial contrast echocardiography, F. Burzotta for assistance during IABP implantation, A. G. Rebuzzi for the successful clinical management of the patient, and F. Crea for the final revision and approval of the manuscript.

* Corresponding author:
E-mail address: gabryloc@hotmail.it (G. Locorotondo).
Available online 3 October 2020