

Table 1 Percutaneous left atrial appendage closure in the presence of thrombus: patient characteristics, anatomic aspects, and antithrombotic treatments

Patient	Patient characteristics			Anatomic aspects and implantation			Antithrombotic treatments			
	Age, sex	CHA ₂ DS ₂ -VASc	HAS-BLED	Indication for LAAC	Type of LAA	Location of thrombus	Device	Previous regimens	Before LAAC (1 month)	After LAAC (long-term)
1	83 y, F	7	4	Recurrent stroke on anticoagulants	Windsock	Landing zone and tip	Amulet No. 31	Acenocumarol, dabigatran, enoxaparin	Apixaban 5 mg/12 h + aspirin	Apixaban 5 mg/12 h
2	86 y, F	7	3	Recurrent stroke on anticoagulants	Chicken wing	Tip	Amulet No. 28	Acenocumarol	Rivaroxaban 20 mg/24 h + aspirin	Rivaroxaban 20 mg/24 h + aspirin
3	83 y, F	9	4	Stroke on anticoagulants with hemorrhagic transformation	Windsock	Tip	Amulet No. 22	Acenocumarol, apixaban	Rivaroxaban 20 mg/24 h + aspirin	Rivaroxaban 20 mg/24 h + aspirin
4	75, M	5	4	Recurrent embolism on anticoagulants, Gastrointestinal bleeding	Chicken wing	Tip	Amulet No. 20	Acenocumarol	Apixaban 5 mg/12 h	Apixaban 2.5 mg/12 h
5	83 y, F	5	3	Uncontrollable gastrointestinal bleeding	Windsock	Landing zone and tip	Amulet No. 28	Acenocumarol, apixaban	Enoxaparin 40 mg/24 h	Aspirin

CHA₂DS₂-VASc, score for stroke risk assessment in atrial fibrillation (congestive heart failure, hypertension, age ≥ 75 years [double score], diabetes mellitus, stroke [double score] vascular disease, age 65–74 years, and sex [female]); F, female; HAS-BLED, score for bleeding risk assessment in atrial fibrillation (hypertension, abnormal renal and liver function, stroke, bleeding, labile INR, elderly, drugs or alcohol); LAAC, left atrial appendage closure; M, male.

Adolfo Fontenla,^{a,*} Ivan Gómez-Blázquez,^b Cecilia Corros-Vicente,^c Rafael Arboleda-Salazar,^d Rafael Salguero-Bodes,^{a,e,f} and Fernando Arribas^{a,e,f}

^aUnidad de Arritmias, Servicio de Cardiología, Hospital Universitario 12 de Octubre, Madrid, Spain

^bUnidad de Hemodinámica, Servicio de Cardiología, Hospital Universitario 12 de Octubre, Madrid, Spain

^cUnidad de Imagen Cardiaca, Servicio de Cardiología, Hospital Universitario 12 de Octubre, Madrid, Spain

^dServicio de Anestesia y Reanimación, Hospital Universitario 12 de Octubre, Madrid, Spain

^eCentro de Investigación Biomédica en Red de Enfermedades Cardiovasculares (CIBERCV), Spain

^fDepartamento de Medicina, Facultad de Medicina, Universidad Complutense, Madrid, Spain

* Corresponding author:
E-mail address: drfontenla@gmail.com (A. Fontenla).

REFERENCES

- Ojeda S, Romaguera R, Cruz-González I, Moreno R. Spanish Cardiac Catheterization and Coronary Intervention Registry 29th Official Report of the Interventional Cardiology Association of the Spanish Society of Cardiology (1990-2019). *Rev Esp Cardiol.* 2020;73:927–936.
- Tarantini G, D'Amico G, Latib A, et al. Percutaneous left atrial appendage occlusion in patients with atrial fibrillation and left appendage thrombus: feasibility, safety and clinical efficacy. *EuroIntervention.* 2018;13:1595–1602.
- Bocuzzi GG, Montabone A, D'Ascenzo F, et al. Cerebral protection in left atrial appendage closure in the presence of appendage thrombosis. *Catheter Cardiovasc Interv.* 2020. <http://doi.org/10.1002/ccd.29161>
- Seeger J, Kapadia SR, Kodali S, et al. Rate of peri-procedural stroke observed with cerebral embolic protection during transcatheter aortic valve replacement: a patient-level propensity-matched analysis. *Eur Heart J.* 2019;40:1334–1340.

<https://doi.org/10.1016/j.rec.2021.04.011>
1885-5857/© 2021 Sociedad Española de Cardiología. Published by Elsevier España, S.L.U. All rights reserved.

Mid-term outcomes of percutaneous tricuspid annuloplasty with the Cardioband device



Resultados a medio plazo de la anuloplastia tricuspídea percutánea con dispositivo Cardioband

To the Editor,

Significant (severe to torrential) tricuspid regurgitation (TR)¹ is a disease that usually develops in patients with heart failure and carries an unfavorable prognosis.² Recently, several percutaneous techniques have emerged as alternatives to surgery for the treatment of TR. Cardioband (Edwards Lifesciences, USA) is a percutaneous annular reduction system consisting of a Dacron band that is implanted along the tricuspid annulus using a series of anchors (stainless steel screws). Within the band, there is a wire that is then cinched using an adjustment catheter to reduce the tricuspid annulus.³

Very little information is available on the mid-term outcomes in patients treated with this device, coming almost exclusively from the TRI-REPAIR primary registry, with only 30 patients with at least moderate TR and 2-year outcomes.⁴

The aims of the present study were safety (implantation success and mortality) and mid-term efficacy (reduction of TR severity and symptoms). We analyzed 8 patients with congestive symptoms and severe-torrential TR despite optimized medical treatment who underwent Cardioband implantation with the aim of improving their TR and associated symptoms between September 2019 and August 2020. All patients gave informed consent to participate. The clinical and echocardiographic characteristics at baseline and after the procedure are shown in table 1; 75% were women, mean age was 80.6 ± 3.8 years, and mean body mass index was 26.5 ± 4.7 . In all patients the TR etiology was functional. Three patients had had previous cardiac surgery, and the Cardioband was implanted in these 3 patients at 7, 8, and 10 years after surgery. Overall, the median duration of symptoms until intervention was 17.5 [interquartile range, 4–31] months, and all patients had optimized medical treatment. EuroSCORE II was 5.5% and the Society of Thoracic Surgeons risk score was 7.8%. Pulmonary systolic pressure was 40.5 mmHg and left ventricular ejection fraction was 62%. All patients had atrial fibrillation and none had a pacemaker. All had been rejected for surgery due to high surgical risk, frailty, or comorbidities. The procedures were carried out under general anesthetic and with transesophageal echocardiographic and fluoroscopic guidance, with a mean time of 260 ± 68 min.

The technical success rate of the procedure (defined as successful access, deployment, positioning of the implant and septolateral reduction during the procedure and at discharge as previously established)⁴ was 100%, although in 1 procedure it was not possible to implant all the anchors, as toward the end, the device came loose from the catheter due to torsion of the band during implantation, but it was still possible to cinch it, nonetheless. The mean hospital stay was 8 days. Regarding significant complications, 1 patient had occlusion of a posterolateral branch of the right coronary artery due to traction after cinching the Cardioband; this did not affect ventricular function. No patients died or had ischemic or bleeding complications related to the procedure.

After a mean follow-up of 9 ± 3.67 months, all patients were alive except for an 80-year-old man who had cor pulmonale and died at 4 months. At follow-up, 62.5% of the patients were in New York Heart Association functional class I-II after Cardioband implantation compared with 37.5% at baseline (figure 1). Regarding congestive symptoms, all patients had peripheral edema at baseline; this was reduced to 4 patients (50%) at follow-up. There was a significant reduction in the grade of TR assessed using the vena contracta and the classification proposed by Hann et al.¹ ($P = .01$). We also observed a significant reduction in the tricuspid annulus and the right ventricular end-diastolic area, but we did not detect significant changes in right ventricular contractility parameters or mitral regurgitation grade. Likewise, there were no differences in diuretic treatment or parameters of liver and renal function.

Despite the limitation of the small sample size, the results indicate that Cardioband implantation in patients with symptomatic severe-torrential TR appears to be a safe and effective option, which achieves symptomatic improvement in the mid-term and a reduction in the tricuspid annulus and valve regurgitation grade.

This procedure may be futile in patients with severe pulmonary hypertension in an end-stage situation, as occurred in 1 of these patients. Pacemaker wires are not a contradiction, but it should be confirmed that the wire is not adhered to any of the leaflets and that this is not causing the TR. After Cardioband implantation, it is possible to pass a wire or to implant a wireless pacemaker. These results align with those from the TRI-REPAIR primary study, although in the present series, we included patients with moderate TR. Further studies and longer clinical follow-up are needed to

Table 1Baseline characteristics and changes in echocardiographic variables, blood tests, and treatments at follow-up^a

Variable	Baseline	Follow-up ^a	P
<i>Study population baseline characteristics and comorbidities</i>			
Hypertension	7 (87.5)		
Diabetes mellitus	1 (12.5)		
COPD	1 (12.5)		
eGFR < 60 mL/min/1.73 m ²	5 (62.5)		
Pulmonary systolic pressure, mmHg	45.8 ± 9.3		
Atrial fibrillation	8 (100)		
Chronic ischemic heart disease	0		
Previous cardiac surgery	3 (37.5)		
Ascites	2 (25)		
Previous stroke	1 (12.5)		
Active cancer	1 (12.5)		
EuroSCORE II	5.5%		
STS score	7.8%		
Frailty ^b	7 (87.5)		
<i>Echocardiographic parameters</i>			
Vena contracta TR, mm	13.3 ± 4.0	7 ± 3.0	.026
RV area, cm ²	31.4 ± 7.1	23.2 ± 8.2	.003
RA area, cm ²	32.7 ± 9.2	28.0 ± 6.5	.119
AL tricuspid annulus, mm	45 ± 3.8	37.4 ± 4.0	.015
RV global longitudinal strain	-14.2 ± 3.8	-15.5 ± 1.8	.518
RV fractional area change	39.5 ± 8.4	43.2 ± 5.4	.398
LVEF, %	62.5 ± 8	62.2 ± 6	.923
<i>Medical treatment</i>			
Furosemide, mg/d	87 ± 53	107 ± 73	.245
Torsemide, mg/d	2.5 ^a	0	
Spironolactone, mg/d	20 ± 13	23 ± 33	.741
<i>Blood parameters</i>			
eGFR, mL/kg/1.73 m ²	57 ± 22	48 ± 21	.170
Creatinine, mg/dL	1.1 ± 0.3	1.2 ± 0.3	.315
BNP, pg/mL	240 ± 96	322 ± 272	.571
AST, U/L	38.4 ± 14.4	36.7 ± 12.1	.085
ALT, U/L	22.7 ± 5.6	25.0 ± 10.3	.597
GGT, U/L	168 ± 83	129 ± 65	.118
Hemoglobin, g/dL	12.6 ± 1.1	12.4 ± 1.4	.429

AL, anterolateral; ALT, alanine aminotransferase; AST, aspartate aminotransferase; BNP, brain natriuretic peptide; COPD, chronic obstructive pulmonary disease; eGFR, estimated glomerular filtration rate; GGT, gamma glutamyl transferase; LVEF, left ventricular ejection fraction; RA, right atrium; RV, right ventricle; STS, Society of Thoracic Surgeons; TR, tricuspid regurgitation.

^a The echocardiographic variables compared are from studies at baseline and at 3 months after Cardioband implantation. For the rest of the variables, the most recent measurement or assessment performed during follow-up (9.03 ± 3.67 months) were used.

^b According to the frailty criteria proposed by Fried et al.⁵ Unless otherwise indicated, qualitative variables are expressed as No. (%) and quantitative variables, as mean ± standard deviation.

confirm the promising data from this new percutaneous treatment option.

Acknowledgements

We would like to thank Dr Luisa Salido Tahoces and Dr Rocío Hinojar-Baydes for their invaluable critical review of the article.

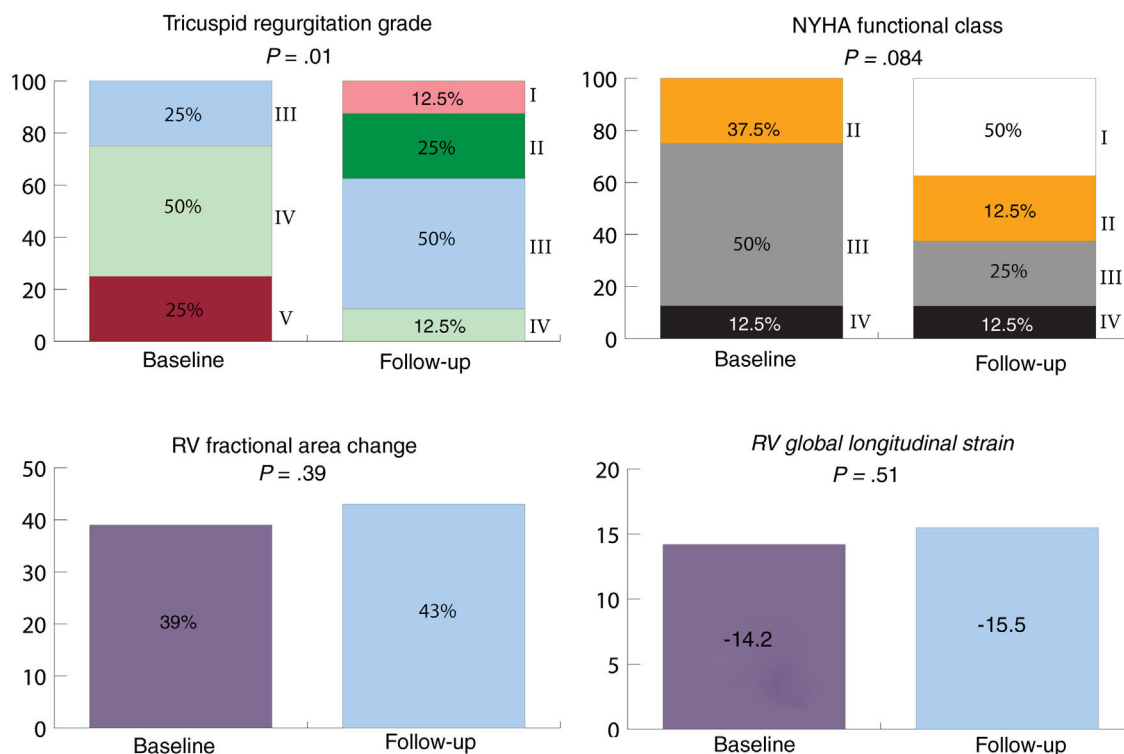


Figure 1. Clinical and echocardiographic variables at follow-up*. Tricuspid regurgitation was classified from grade I (mild) to V (torrential). NYHA, New York Heart Association functional class; RV, right ventricle.

*The echocardiographic variables compared were from studies done at baseline and at 3 months after Cardioband implantation. For NYHA, the most recent assessment performed during follow-up (9.03 ± 3.67 months) was used.

FUNDING

No funding was received for this article.

AUTHORS' CONTRIBUTIONS

Study concept and design: Á. Sánchez-Recalde and J. Solano-López. Manuscript writing: Á. Sánchez-Recalde and J. Solano-López. Data acquisition, analysis and interpretation: J. Solano-López, A. García Martín and A. González Gómez. Critical review of the manuscript: J.L. Zamorano, C. Fernández-Golfín, A. García Martín and A. González Gómez.

CONFLICTS OF INTEREST

Á. Sánchez-Recalde is associate editor of *Revista Española de Cardiología*; the journal's established editorial process has been followed to ensure impartial handling of the manuscript.

Jorge Solano-López, José L. Zamorano, Ana García-Martín, Ariana González Gómez, Covadonga Fernández-Golfín, and Ángel Sánchez-Recalde*

Servicio de Cardiología, Hospital Universitario Ramón y Cajal, Madrid, Spain

*Corresponding author:

E-mail address: asrecalde@hotmail.com (Á. Sánchez-Recalde).

REFERENCES

- Hahn RT, Zamorano JL. The need for a new tricuspid regurgitation grading scheme. *Eur Heart J Cardiovasc Imaging*. 2017;18:1342–1343.
- Nath J, Foster E, Heidenreich PA. Impact of tricuspid regurgitation on long-term survival. *J Am Coll Cardiol*. 2004;43:405–409.
- Sánchez-Recalde Á, Hernández-Antolín R, Salido Tahoces L, García-Martín A, Fernández-Golfín C, Zamorano JL. Transcatheter tricuspid annuloplasty with the Cardioband device to treat severe functional tricuspid regurgitation. *Rev Esp Cardiol*. 2020;73:507–508.
- Nickening G, Weber M, Schüller R, et al. Tricuspid valve repair with the Cardioband system: two-year outcomes of the multicentre, prospective TRI-REPAIR study. *Eurointervention*. 2021;16:e1264–e1271.
- Fried LP, Tangen CM, Walston J, et al. Frailty in older adults: evidence for a phenotype. *J Gerontol A Biol Sci Med Sci*. 2001;56:M146–M156.

<https://doi.org/10.1016/j.rec.2021.03.013>

1885-5857/© 2021 Sociedad Española de Cardiología. Published by Elsevier España, S.L.U. All rights reserved.