

Electrocardiographic Diagnosis of Left Main Coronary Artery Occlusion

To the Editor:

We wish to congratulate Prieto-Solis et al¹ for their work on the electrocardiographic diagnosis of left coronary artery occlusion; however, after reading it, we would like to make a few comments.

We believe that the number of patients included with multivessel disease (2 or more vessels) is low, given that ACS is more prevalent than isolated LCA disease. In a recent study it was 5.4%, 24%, and 27% for isolated LCA disease, 3-vessel disease and LCA/3-vessel disease, respectively.² These data may invalidate the conclusion of the study due to a non-representative sample.

The duration of the ischaemic event may be brief, and in the absence of symptoms, the ECG changes may be minimal,³ which is not mentioned in the article.¹

We have also noticed that, in the cases of LCA disease, ST depression is seen in II, III, and aVF of 100%, 60%, and 95% respectively; while in our experience⁴ it is 65%, 28%, and 35%. We believe that the explanation may be that the LCA cases are not pure, but rather are combined with other lesions, since the percentages change significantly in three vessel disease without LCA involvement (to 92%, 43%, and 76%, respectively.)

Regarding the direction of the vector directed to quadrant-A in the frontal plane (-90° to -180°) or anterior in the horizontal plane, we would like to point out that in our experience (17 patients with LCA subocclusion vs 37 patients with 3-vessel disease without injury to the LCA), the location and direction are very similar in the case of multi-vessel disease, an electrocardiographic finding that does not help differentiate them (Figures 1 and 2)

The case in Figure 4 from the Prieto-Solis et al¹ article (obstruction of the RCA) is an ACS with ST elevation in the lower leads and clear criteria for

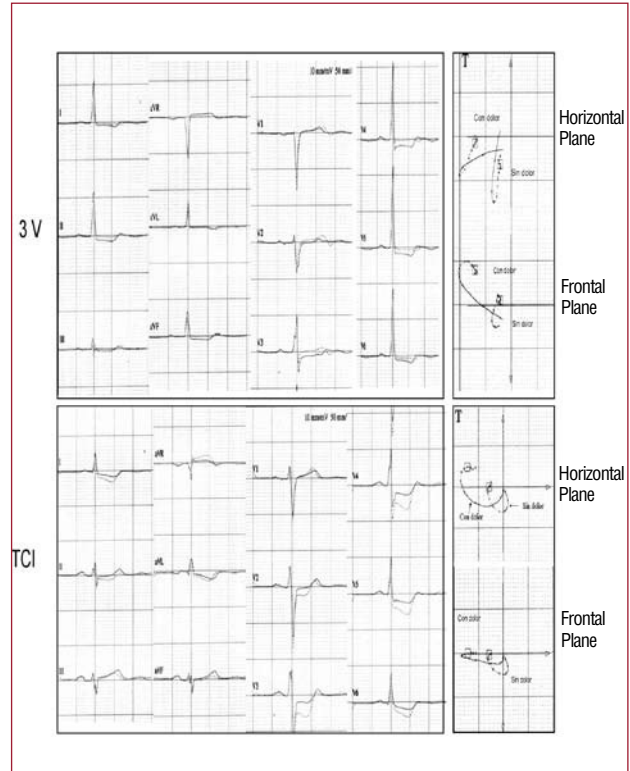
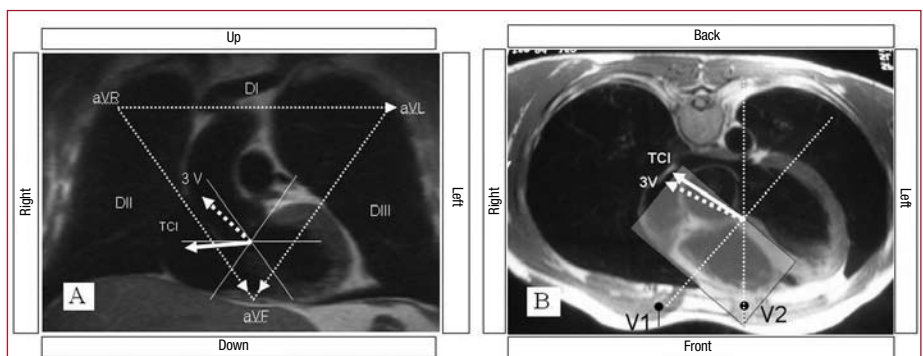


Figure 2. Cardiographic-vector analysis of 2 patients with isolated left coronary artery (LCA) disease and 3-vessel disease (3V) without LCA involvement. The location of the lesion's vector loop is similar in both cases.

proximal occlusion of the RCA: ST depression in I and ST elevation in II < III and isoelectric in V1, according to the algorithm we published^{5,6} and is associated with multivessel disease (ST depression in V2-V6).⁷

The search for electrocardiographic criteria to differentiate LCA disease from other lesions effectively requires prospective studies, especially in the case of non-ST elevation ACS in which the obstructed artery is the RCA, LCX, or the LAD.

Figure 1. A: frontal plane superimposed on a magnetic resonance image; in the case of 3-vessel disease, the lesion's dipole often falls in the negative hemifield in leads I, II, and III; conversely, in the LCA lesion, it often falls in the positive hemifield in III and in the positive isoelectric hemifield in II and the negative hemifield in I. B: horizontal plane, both in LCA disease as well as three-vessel disease, both fall in the positive hemifield in V1 close to the dividing line, and because of this, isolated analysis of the V1 lead is not useful for differentiating both situations.



We hope that these comments help to clarify a subject so complex as that discussed in the article on which we are commenting.

Andrés Carrillo^a, Miquel Fiol^a,
Rocío Amézaga,^a and
Antonio Bayés de Luna^b

^aUnidad Coronaria, Hospital Son Dureta,
Palma de Mallorca, Islas Baleares, Spain

^bInstituto Catalán de Cardiología, Barcelona, Spain

REFERENCES

1. Prieto-Solis JA, Benito N, Martín-Durán R. Diagnóstico electrocardiográfico de la obstrucción del tronco coronario izquierdo mediante el análisis vectorial del segmento ST y complejo QRS. *Rev Esp Cardiol.* 2008;61:137-45.
2. Yan AT, Yan RT, Kennelly BM, Andersen FA, Budaj A, López-Sendón JL, et al. Relationship of ST elevation in lead aVR with angiographic findings and outcome in non-ST-elevation acute coronary syndromes. *Am Heart J.* 2007;154:71-8.
3. Atie L, Brugada P, Brugada J, Smeets JL, Cruz FE, Romplás MP, et al. Clinical presentation and progress of left main coronary artery disease in 1980's. *Eur Heart J.* 1991;12:495-502.
4. Bayés de Luna A, Fiol-Sala M, editores. *Electrocardiography in ischemic heart disease. Clinical and imaging correlations and prognostic implications.* Oxford: Blackwell/Futura; 2008. p. 99-103.
5. Fiol M, Cygankiewicz I, Carrillo A, Bayés-Genís A, Santoyo O, Gómez A, et al. Value of electrocardiographic algorithm based on "ups and downs" of ST in assessment of a culprit artery in evolving inferior wall acute myocardial infarction. *Am J Cardiol.* 2004;94:709-14.
6. Fiol M, Carrillo A, Cygankiewicz I, Ayestarán JI, Caldés O, Peral V, et al. New criteria based on ST changes in 12-lead surface ECG to detect proximal versus distal right coronary artery occlusion in a case of acute inferoposterior myocardial infarction. *Ann Noninvasive Electrocardiol.* 2004;9:383-8.
7. Mager A, Sclarovsky S, Herz I, Adler Y, Strasberg B, Birnbaum Y. Value of the initial electrocardiogram in patients with inferior-wall acute myocardial infarction for prediction of multivessel coronary artery disease. *Coron Artery Dis.* 2000;11:415-20.

Response

To the Editor:

We appreciate the comments from Carrillo et al. We will try to respond to the questions raised.

Regarding point 1, the number of multivessel patients is quite low. This is due to the inclusion process¹ from the electrocardiogram (ECG) at admission which showed the most acute ischaemic changes, and which have been described as suggesting left coronary artery (LCA) disease.^{2,3} Out of a total of 840 patients with acute coronary syndrome (ACS), 57 patients who met the electrocardiographic criteria and had coronary angiography in the acute phase were included. We agree that multivessel

involvement is more prevalent than the LCA in ACS, but its prevalence is revealed by coronary angiography, which does not necessarily correlate with the extension of the ischaemia; for example, one patient may be admitted for ACS caused by obstruction of a marginal artery and three-vessel disease is found on coronary angiography.

We agree with point 2 that the ECG can be normal in the absence of acute ischaemia even though coronary involvement is severe. Space limitations do not permit commenting on aspects that are well-known.

On point 3, it is true that all patients with LCA involvement have ST-segment depression in II. In the 20 patients with LCA involvement, the extensive ischaemia of the endocardium creates an ST-vector directed towards quadrant-A (between -90° and -180°), which is why the ST segment has to be elevated in aVR and depressed in II. Coronary artery disease is a diffuse process and significant involvement in other territories cannot be ruled out despite having a "luminogram" on the coronary angiography that does not show severe stenosis.^{4,5}

We agree with point 4, that the ECG of the LCA and multivessel involvement may be similar.^{2,3} The ST vector in multivessel disease will vary depending on the artery that causes the acute ischaemia and on the intensity and extension of the ischaemia, which is why the ST vector in multivessel disease may be similar if there is extensive ischaemia in the territory of the left anterior descending and circumflex arteries.³ The following recent case illustrates the value of vector analysis of the ECG in "pure" ischaemia due to LCA obstruction: a young woman with central chest pain with effort. Sudden death preceded by chest pain upon carrying bags up a slope in front of the hospital and resuscitated successfully. The ECG on admission to the ICU only showed nonspecific changes in repolarisation (Figure 1); neurological recovery is complete and the coronary angiography is "normal." A stress test is performed in which extensive ischaemia compatible with LCA involvement is seen: a large ST vector towards quadrant-A is seen in the frontal plane and anterior in the horizontal plane, and the QRS vector is shifted to the left with an anterior hemiblock (Figure 2). Coronary angiography is repeated with subselective injection in the left coronary sinus and a "mass" impacting the LCA with severe obstruction is seen; when the catheter is introduced, the "mass" is displaced and the coronary angiography appears normal. A transoesophageal echocardiogram revealed a papillary fibroelastoma. She was operated on successfully.

Regarding point 5, we completely agree that in the majority of patients, the artery that causes the posteroinferior MI can be located.^{3,6,7}

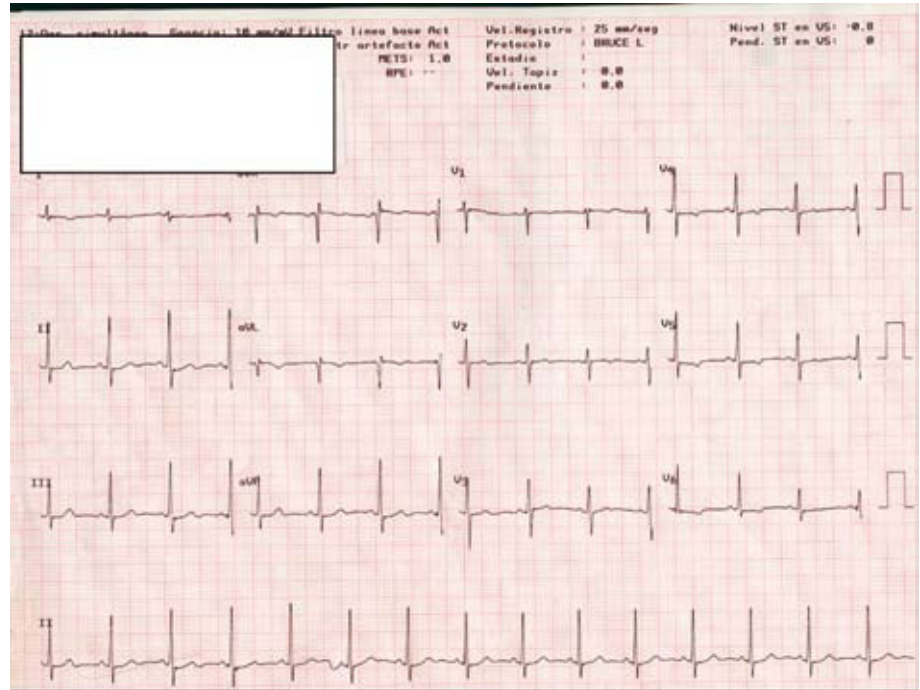


Figure 1. Electrocardiogram at admission in which nonspecific repolarisation changes are seen.

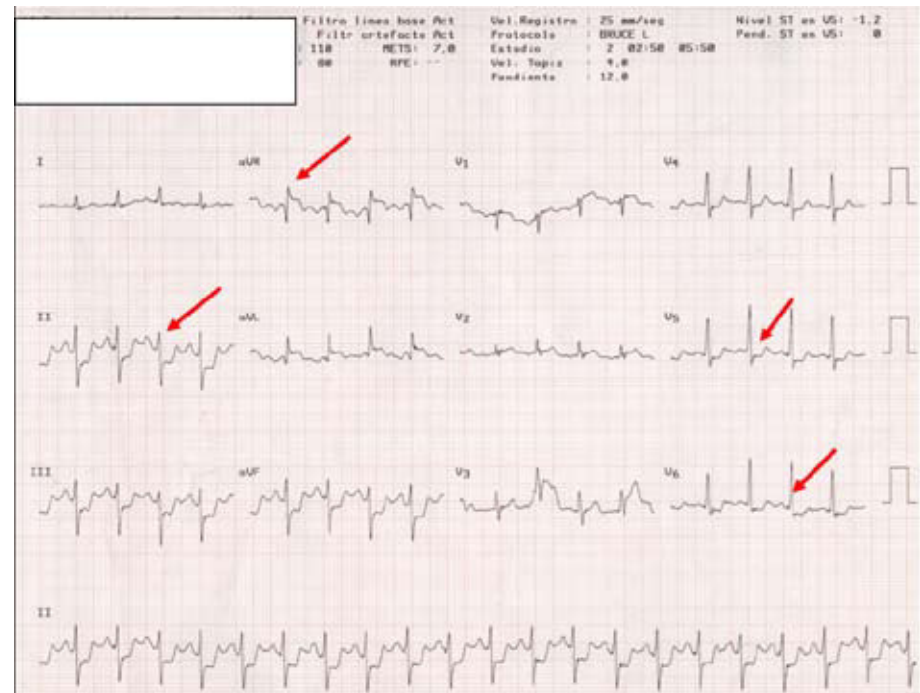


Figure 2. Electrocardiogram during induced ischaemia on the stress test. An ST-segment vector towards quadrant-A is generated in the frontal plane and anterior in the horizontal plane. The QRS vector is shifted to the left due to an anterior hemiblock.

Finally, we once again thank Carrillo et al for their comments and their interest in our article.

José Antonio Prieto Solís
and Rafael Martín Durán
Servicio de Cardiología, Hospital Universitario Marqués
de Valdecilla, Santander, Cantabria, Spain

REFERENCES

1. Prieto-Solís JA, Benito N, Martín-Durán R. Diagnóstico electrocardiográfico de la obstrucción del tronco coronario izquierdo mediante el análisis vectorial del segmento ST y el complejo QRS. *Rev Esp Cardiol.* 2008;61:137-45.

2. Gorgels APM, Vos MA, Mulleneers R, De Zwaan C, Bär FWHM, Wellens HJJ. Value of the electrocardiogram in diagnosing the number of severely narrowed coronary arteries in rest angina pectoris. *Am J Cardiol.* 1993;72:999-1003.
3. Wellens HJJ, Gorgels APM, Doevendans PA. The ECG in acute myocardial infarction and unstable angina: Diagnosis and risk stratification. Boston-Dordrecht-London: Kluwer; 2003. p. 9.
4. Glasgow S, Weisenberg E, Zarins CK, Stankunavicius R, Koletts GJ. Compensatory enlargement of human atherosclerotic coronary arteries. *N Engl J Med.* 1987;316:1371-5.
5. Topol EJ, Nissen SE. Our preoccupation with coronary luminology. The dissociation between clinical and angiographic findings in ischemic heart disease. *Circulation.* 1995;92:2333-42.
6. Prieto Solís JA, Martín Duran R, San José JM. [A new electrocardiographic approach to identify the coronary artery responsible for acute inferior myocardial infarction. A study of 100 patients]. *Rev Port Cardiol.* 1998;17:133-42.
7. Fiol M, Cygankiewicz I, Carrillo A, Bayés-Genís A, Santoyo O, Gómez A, et al. Value of electrocardiographic algorithm based on “ups and downs” of ST in assessment of a culprit artery in evolving inferior wall acute myocardial infarction. *Am J Cardiol.* 2004;94:709-14.