

ECG Contest

Response to ECG, May 2016

Respuesta al ECG de mayo de 2016

Víctor Bazán

Unidad de Arritmias, Servicio de Cardiología, Hospital de la Santa Creu i Sant Pau, Barcelona, Spain



The patient has second-degree atrioventricular (AV) block alternating with slowly-conducted P waves (long PR) via an intermittent left accessory pathway. The existence of this pathway avoids potential prolonged asystole due to advanced atrioventricular block. After pacemaker implantation, paced rhythm alternated with conduction via the pathway, which disappeared over time (Figures 1–3).

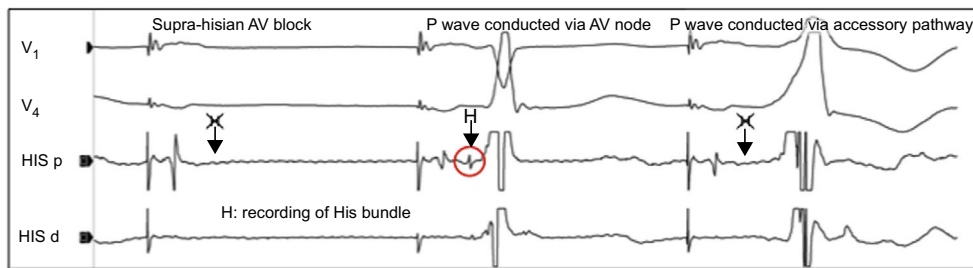


Figure 1.

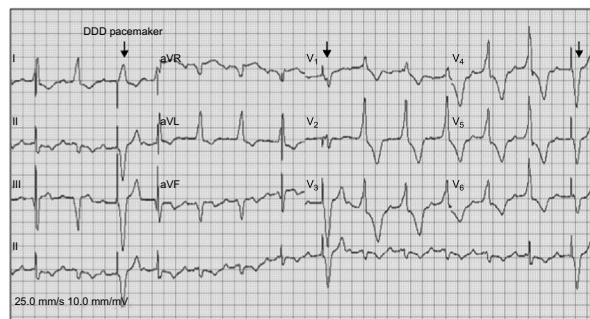


Figure 2.

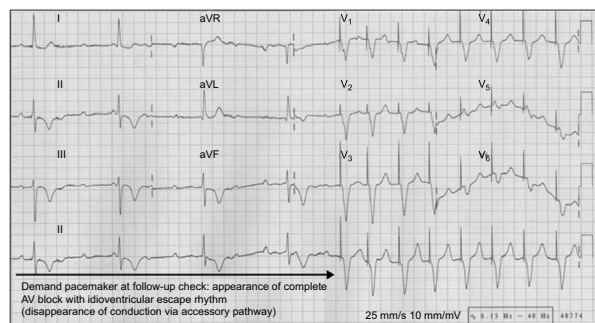


Figure 3.

SEE RELATED ARTICLE:
<http://dx.doi.org/10.1016/j.rec.2015.12.018>
 E-mail address: victorbazang@yahoo.com