

**Table 2**  
Distribution of Health Care Costs as a Function of Causes of Inappropriate Discharge

	Episodes, n	Attends emergency room	Attends out-patient clinic	Admission without intervention (GRD 544)	Admission with intervention (GRD 115)	Mean per episode
<i>Unit cost</i>	—	185	143	10 845	14 724	
<i>ID episodes</i>						
Rapid atrial fibrillation	12	370	286			55
Supraventricular tachycardia	11	185	429			56
Sinus tachycardia	5	555	429			197
T wave detection	7	185	572	10 845	29 448	5864
Electrode displacement	3	185	143		29 448	9925
Broken electrode	3	555	0		44 172	14 909
Inhibition therapy failure	1	185	143			328
Total	42	2220	2002	10 845	103 068	2813

DRG, diagnosis-related groups; ID, inappropriate discharge. Unless otherwise indicated, values express €.

We must remember that the economic value of the resources used was determined by our context at the time of the study, and this may differ in other situations. Furthermore, our calculation was based on the use of specific health care resources but we did not consider costs associated with the undoubtedly unfavorable effects of shocks—particularly inappropriate shocks—on psychosocial factors, quality of life, and overall mortality.

Our study found the economic cost of ID-related medical attention is distributed unequally; 42.8% of episodes were treated without using any of the resources studied and 96.4% of total costs were related to the 8 in-hospital episodes. We must distinguish between the cost of ID episode-related medical attention as such, and the cost of treating the cause. The first is low, since half of the episodes did not generate extra visits and were diagnosed at subsequent routine check-ups; moreover, diagnosis and therapeutic decision-making took place at a single visit. We put the cost of this at a mean €100 per episode. Treatment of ID-causes gives rise to costs that differ greatly as a function of these causes. Most are treated by reprogramming and/or adjusting medication, at no additional cost. However, 19% of episodes required hospitalization and reintervention, with high costs attributable more to the complication causing the ID than to ID itself (mean €14 239). Moreover, ID shortens the useful life of devices, at an estimated mean cost of some €4000 per device with ID.

## FUNDING

Study financed by Medtronic.

Damià Pere Ferrer Kleiner,<sup>a,\*</sup> Antoni Sicras Mainar,<sup>b</sup> Roger Villuendas Sabaté,<sup>a</sup> Oscar Alcalde Rodríguez,<sup>a</sup> Carles Labata Salvador,<sup>a</sup> and Antoni Bayes-Genis<sup>a</sup>

<sup>a</sup>Unidad de Arritmias, Servicio de Cardiología, Hospital Universitari Germans Trias i Pujol, Badalona, Barcelona, Spain

<sup>b</sup>Dirección de Planificación, Hospital Municipal de Badalona, Badalona, Barcelona, Spain

\*Corresponding author:

E-mail address: [dpere Ferrer.germanstrias@gencat.cat](mailto:dpere Ferrer.germanstrias@gencat.cat) (D. Pere Ferrer Kleiner).

Available online 16 October 2013

## REFERENCES

1. Zipes DP, Camm AJ, Borggrefe M, Buxton AE, Chaitman B, Fromer M, et al. ACC/AHA/ESC 2006 guidelines for management of patients with ventricular arrhythmias and the prevention of sudden cardiac death: a report of the American College of Cardiology/American Heart Association Task Force and the European Society of Cardiology Committee for Practice Guidelines. *J Am Coll Cardiol*. 2006;48:e247–346.
2. Orden SLT/42/2012, de 24 de febrero, por la que se regulan los supuestos y conceptos facturables y se aprueban los precios públicos correspondientes a los servicios que presta el Instituto Catalán de la Salud; DOGC núm. 6079 (02/03/2012). Available at: <http://www.gencat.cat/dogc> [accessed 8 Feb 2013].

<http://dx.doi.org/10.1016/j.rec.2013.06.013>

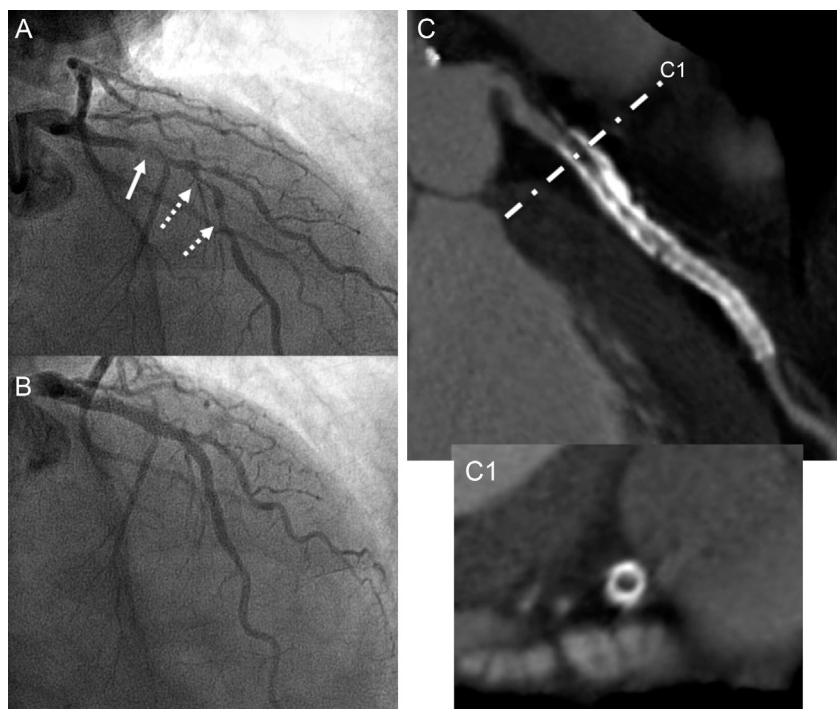
## Comparative Results Between Metal Stent and Bioresorbable Scaffold at Two Years Postimplantation

### Resultados comparativos entre el stent metálico y el stent bioabsorbible a los dos años de su implante

#### To the Editor,

A 75-year-old male smoker with diabetes and dyslipidemia was admitted to our hospital in January 2011 with anterior acute myocardial infarction. Emergency coronary angiography revealed

severe atheromatous disease with thrombosis in the proximal and medial segment of the left anterior descending artery. The lesion was revascularized in a percutaneous procedure by balloon angioplasty and placement of 2 overlapping everolimus-eluting stents (Promus Element 2.75×24 mm and 3.5×24 mm, Boston Scientific Corporation; Natick, Massachusetts, United States) (Fig. 1). In addition, a severe lesion was detected by angiography in the medial segment of the right coronary artery and treated in a scheduled procedure 1 month later. In view of the characteristics (short nonostial de novo lesion in a native coronary artery with a good caliber and without significant calcification) and the



**Figure 1.** A: Intraluminal thrombus leading to deficient perfusion in the proximal segment of the left anterior descending artery (solid arrow) and severe atherosclerotic disease in the medial segment of the same artery (dashed arrows). B: Angiographic outcome at the site of primary angioplasty with placement of 2 overlapping drug-eluting metal stents. C: Noninvasive angiographic study by computed tomography at 2 years; a substantial metal artifact is observed (high white density) resulting from both stents. C1: Transversal section of the proximal segment of the left anterior descending artery showing significant intrastent neointimal hyperplasia in the stent (low black density tissue).

satisfactory dilation achieved with balloon angioplasty, the patient was implanted with a bioresorbable everolimus-eluting vascular scaffold (Absorb BVS 3.0×18 mm, Abbott Vascular; Santa Clara, California, United States) (Fig. 2).

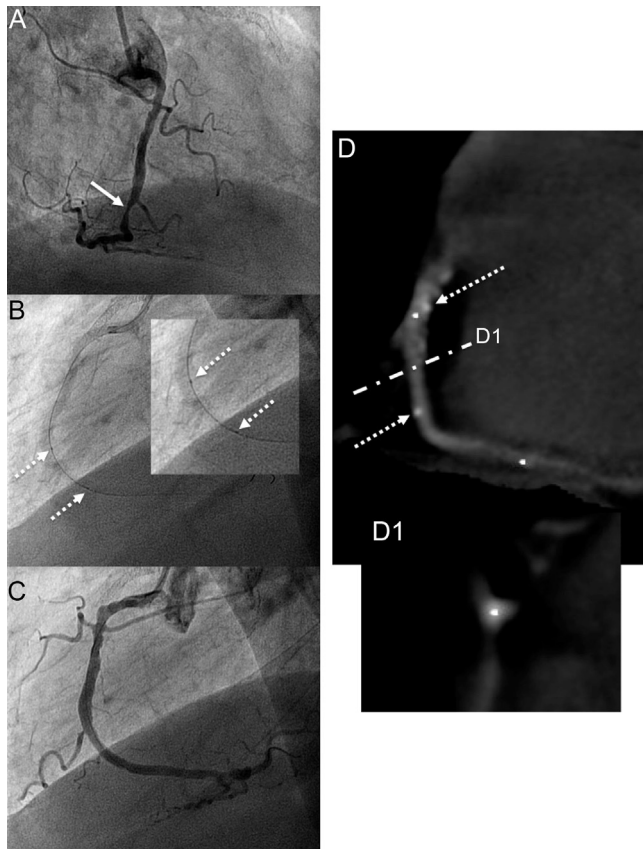
In March 2013, multislice coronary computed tomography was performed (Aquilion 64, Toshiba Corporation; Tokyo, Japan), showing the outcome of both percutaneous coronary interventions. In the case of the anterior descending artery, neointimal hyperplasia could be observed in the proximal stent and in the region of overlap, despite the metallic nature of the stents (Fig. 1). As expected, no metal artifact or neointimal hyperplasia was observed within the revascularized lesion with bioresorbable vascular scaffold, although the 2 platinum markers of the proximal and distal edges were evident (Fig. 2).

The advent of metal stents was a major advance in percutaneous coronary intervention procedures, as these significantly reduced acute occlusion and elastic retraction of the target lesions after simple balloon angioplasty. However, it was soon noted that the rate of restenosis, although lower, was still high, with neointimal hyperplasia developing to an even greater extent than after simple balloon angioplasty. Although drug-eluting stents have further improved the outcome of percutaneous coronary intervention, clinically relevant complications such as restenosis and late stent thrombosis are still observed.<sup>1</sup> On the other hand, the presence of a metal structure inside the arterial lumen can induce a substantial inflammatory reaction that may lead to neoatherosclerosis and be at least a partial cause of severe long-term endothelial dysfunction in the target artery.<sup>2,3</sup> In addition, the

metal scaffolding limits subsequent enlargement of the artery and expansive remodeling.<sup>1</sup>

In view of the above, a novel and enticing concept is that bioresorbable vascular scaffolds may be able to provide the necessary support during the first few weeks to prevent acute occlusion and elastic retraction of the coronary artery while eluting an antiproliferative drug that reduces the risk of neointimal hyperplasia.

We believe that our case illustrates some of the advantages of these bioresorbable vascular scaffolds compared to metallic stents. The complete absence after 2 years of any endovascular structure (Fig. 2D) would minimize and even eliminate late events such as restenosis (Fig. 1C) or stent thrombosis. This in turn would make prolonged antiplatelet therapy unnecessary. Likewise, the absence of the scaffold would allow further interventions, both percutaneous and surgical, on the revascularized artery or secondary branches (note, for example, the caging of the diagonal branch in Fig. 1B compared to the transient caging of the acute marginal branch, Fig. 2C). Finally, metal stents are known to be responsible for a “blooming effect” in the images produced by coronary angiography or computed tomography that reveals a false thickening of the stent struts, leading to underestimation of the real diameter of the intrastent lumen. In the absence of any metal, noninvasive monitoring of the outcome by angiographic computed tomography or magnetic resonance imaging of arterial segments treated with bioresorbable vascular scaffolds could also be a valid and reliable alternative to invasive coronary angiography.



**Figure 2.** A: Severe atheromatous lesion of the medial segment of the right coronary artery (arrow). B: Placement of bioresorbable vascular scaffold; the 2 radiopaque markers at either end of the stent can be seen (dashed arrows). C: Angiographic outcome after placement of the bioresorbable vascular scaffold. D: Noninvasive angiographic assessment by computed tomography at 2 years, in which only the radiopaque markers (dashed arrows) in the medial segment of the right coronary artery. D1: Transversal segment of the artery at the same site, confirming the absence of intraluminal stent and tissue indicative of neointimal hyperplasia.

Juan Ruiz-García,<sup>a,b,\*</sup> Elena Refoyo,<sup>c</sup> Emilio Cuesta-López,<sup>d</sup> Santiago Jiménez-Valero,<sup>a,b</sup> Ángela Portela,<sup>a</sup> and Raúl Moreno<sup>a,b</sup>

<sup>a</sup>Sección de Hemodinámica y Cardiología Intervencionista, Servicio de Cardiología, Hospital Universitario La Paz, Madrid, Spain

<sup>b</sup>Servicio de Cardiología, Hospital Universitario Quirón, Pozuelo de Alarcón, Madrid, Spain

<sup>c</sup>Sección de Imagen Cardíaca, Servicio de Cardiología, Hospital Universitario La Paz, Madrid, Spain

<sup>d</sup>Servicio de Radiodiagnóstico, Hospital Universitario La Paz, Madrid, Spain

\* Corresponding author:.

E-mail address: [j.ruizgarcia@hotmail.com](mailto:j.ruizgarcia@hotmail.com) (J. Ruiz-García).

Available online 23 October 2013

## REFERENCES

1. Onuma Y, Serruys PW. Bioresorbable scaffold: The advent of a new era in percutaneous coronary and peripheral revascularization? *Circulation*. 2011; 123:779–97.
2. Juni RP, Duckers HJ, Vanhoutte PM, Virmani R, Moens AL. Oxidative stress and pathological changes after coronary artery interventions. *J Am Coll Cardiol*. 2013;61:1471–81.
3. Muramatsu T, Onuma Y, Zhang YJ, Bourantas CV, Kharlamov A, Diletti R, et al. Avances en el tratamiento mediante intervención coronaria percutánea: el *stent* del futuro. *Rev Esp Cardiol*. 2013;66:483–96.

<http://dx.doi.org/10.1016/j.rec.2013.07.004>