

BRIEF REPORTS

Intraluminal dilation of inferior vena cava stenosis after repair of the scimitar syndrome in an adult patient

Fernando Benito Bartolomé, Ana González García and José M.^a Oliver Ruiz

Sección de Hemodinámica. Unidad de Cardiopatías Congénitas del Adulto. Hospital General Universitario La Paz. Madrid.

A 39 year-old woman diagnosed with anomalous drainage of middle and lower right pulmonary veins to the inferior vena cava was corrected surgically by means of baffle with patch up to the left atrium. Early after the operation the patient related intolerance to small efforts and an episode of syncope. The cardiac catheterization demonstrated the presence of a severe stenosis in the inferior vena cava, in its union with the right atrium, that was successfully treated by means of intraluminal percutaneous dilation with a catheter of Inoue. After the procedure the gradient decreased and she improved tolerance to effort, which persisted 10 months later.

Key words: *Congenital heart defects. Stenosis. Surgery.*

(*Rev Esp Cardiol* 2002; 55:)

Dilatación intraluminal de la estenosis de la vena cava inferior tras corrección del síndrome de la cimitarra en el adulto

A una mujer de 39 años diagnosticada de drenaje anómalo de las venas pulmonares media e inferior derecha a la vena cava inferior se le realizó corrección quirúrgica mediante tunelización con parche hasta la aurícula izquierda. Precozmente tras la operación la paciente relataba intolerancia a los pequeños esfuerzos y un episodio de síncope. El cateterismo cardíaco demostró la presencia de una estenosis severa en la vena cava inferior, en su unión con la aurícula derecha, que fue eficazmente tratada mediante dilatación intraluminal percutánea con catéter de Inoue. Tras el procedimiento se redujo el gradiente y mejoró la tolerancia al esfuerzo, que se mantienen 10 meses después.

Palabras clave: *Defectos cardíacos congénitos. Estenosis. Cirugía.*

(*Rev Esp Cardiol* 2002; 55:)

INTRODUCTION

Stenosis of the inferior cava vein (ICV) is a severe complication of surgical correction of anomalous pulmonary vein drainage in the scimitar syndrome in adult patients.¹⁻² This paper reports the case of a 39-year-old woman who underwent surgical correction of this anomaly and presented severe ICV stenosis, which was treated effectively by balloon angioplasty.

Correspondence: Dr. F. Benito.
Meléndez Valdés, 22, 5.º B. 28015 Madrid.
e-mail: fbenito@gmx.net

Received 3 April 2001.
Accepted for publication 12 July 2001.

CLINICAL CASE

A 39-year-old woman with a 5-year history of palpitations, dyspnea with moderate effort, and morning ankle edema. In the physical examination a grade II/IV systolic ejection murmur was auscultated in the pulmonary focus with wide splitting of the second sound. The electrocardiogram revealed sinus rhythm, PR interval 0.14 s, QRS axis +90° with a morphology of incomplete right bundle-branch block, and a thoracic radiograph showing moderate cardiomegaly due to dilation of the right ventricle (RV), pulmonary plethora, and a vascular image parallel to the right cardiac margin. The 2D echocardiogram showed RV volume overload with intact interatrial septum and anomalous drainage of the lower right pulmonary vein into the ICV. In cardiac catheterization, a left-to-right shunt was detected with Qp/Qs of 1.7 and pulmonary artery pressure of

ABBREVIATIONS

ICV: inferior cava vein
RV: right ventricle

35/15 mm Hg (ascending aorta pressure 105/65 mm Hg). Angiography demonstrated drainage of the right, middle, and inferior pulmonary veins into the ICV and excluded pulmonary sequestration. She underwent surgical correction. By medial sternotomy and right longitudinal atriotomy extended to the ICV, infradiaphragmatic drainage of the middle and lower right pulmonary vein was confirmed. The venous collector was tunneled from its opening on the cava to the left atrium through a septal window using a Dacron® hemiconduct. The right atrium and ICV were then enlarged with a patch of bovine peri-

cardium. The immediate postoperative period coursed without complications, except for an episode of arterial hypotension and bradycardia that resolved spontaneously. After discharge from the hospital, the patient reported intolerance to minor effort that interfered with household tasks, causing one syncope and two presyncope episodes. In the physical examination, painless hepatomegaly was palpated 2 cm below the rib cage without other significant disturbances. The stress test was interrupted at minute 1.6 by excessive tachycardization and a feeling of dizziness. In the echocardiogram, the RV was smaller, pulmonary vein blood flow was conducted back to the left atrium, and ICV blood flow was accelerated at its entrance into the right atrium, with a maximum gradient of 11 mm Hg and mean gradient of 13 mm Hg, without residual shunting. Catheterization was performed via the left femoral artery and vein and the right brachial vein, registering a peak gradient of 9 mm Hg and a mean gradient of 7 mm Hg between the ICV and atrium (Figure 1). An angiographic image of stenosis was obtained, with an estimated diameter of 12 mm and ICV dilation (diameter 28-30 mm) (Figure 2a). An Inoue catheter was inserted and the balloon was inflated in the stenotic zone to consecutive diameters of 28 mm and 30 mm (Figure 2b). After dilation, the gradient disappeared (Figure 1) but the angiographic image hardly changed (Figure 2c), resulting in improved functional capacity with prolongation of effort up to 7 min. At 10 months of follow-up, the patient had a practically normal life and persistent Doppler gradient, with a peak value of 5 mm Hg and mean gradient of 3 mm Hg.

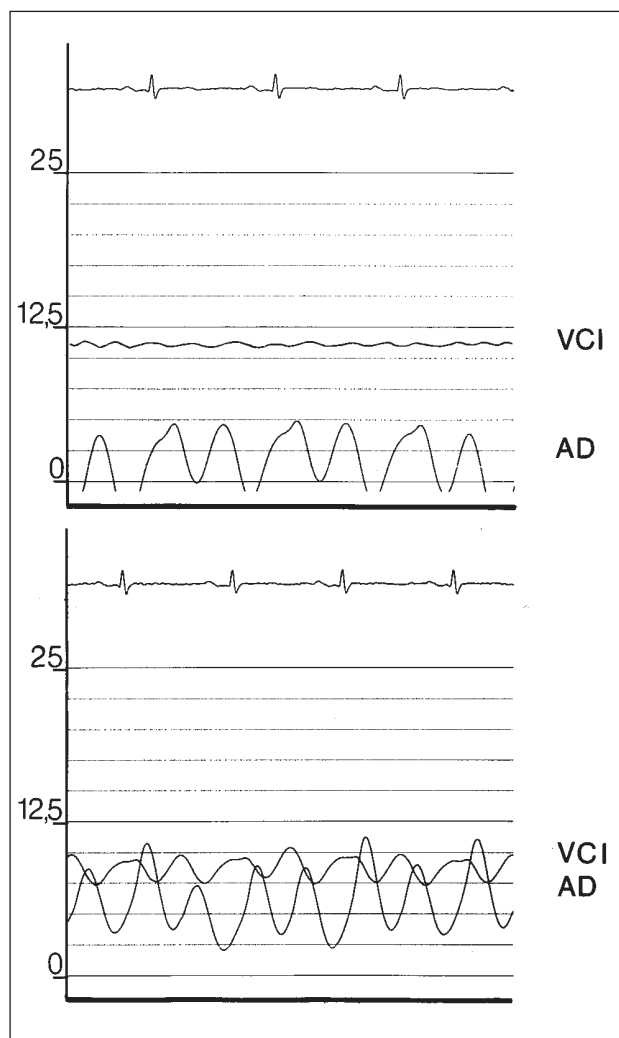


Fig. 1. Simultaneous registration of the inferior cava vein (ICV) and right atrial (RA) pressures before (above) and after balloon dilation (below).

DISCUSSION

Venous obstruction is relatively frequent when prosthetic material is used in the surgical intervention, due to the proliferation of fibrous tissue on the prosthesis, together with progressive retraction. The surgical treatment of this complication is technically difficult and demands new surgery with extracorporeal circulation, which is why percutaneous dilation is chosen at present. While the effectiveness of balloon dilation is usually transitory, due to vessel compliance,³ good immediate and intermediate-term results have been communicated with stent implantation.^{4,5} In the patient in this study, another factor is partial occupation of the ICV lumen by tunneling the anomalous drainage, which may be involved in the stenosis. The Inoue catheter has been used successfully in membranous stenosis of the ICV due to Budd-Chiari syndrome.^{6,7} In this case it was chosen because of: *a*) easy placement in the stenosis zone; *b*) low pressure (1-2 atm) and short inflation time (<3 s); *c*) a more resistant balloon than polyurethane balloons, and *d*) the use of a

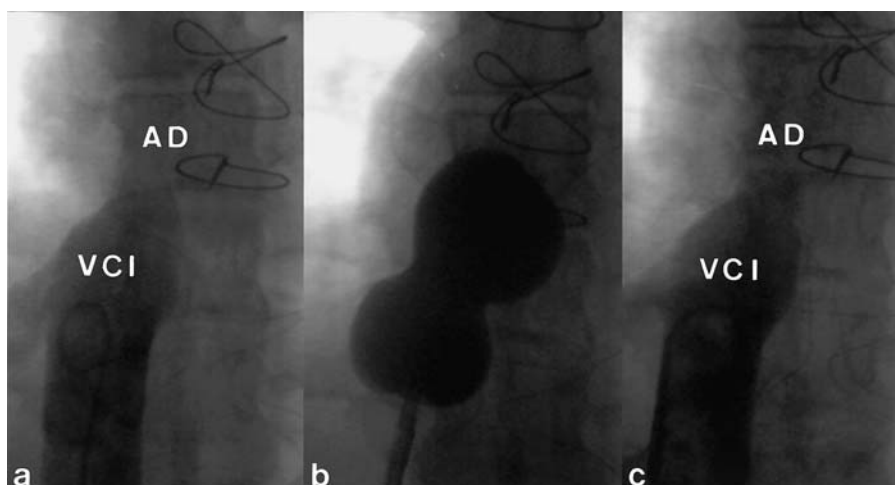


Fig. 2. Angiography in the inferior cava vein (ICV) before (a) and after (c) dilation. Inoue catheter (b) inflated in the ICV located in the stenosis is observed. RA indicates right atrium.

single balloon with a diameter adjustable in relation to volume. Dilation caused the gradient to disappear and was accompanied by marked improvement in immediate and intermediate-term functional capacity. The minimal or null modification of the image after angioplasty is explained by the probable diaphragmatic mechanism of the stenosis secondary to growth of a fine fibrous scar tissue that is not visible on angiography. Although stent dilation may be indicated in restenosis, its use is not free of several potential problems: *a*) difficulties in implantation due to distal location of the stenosis, near the opening of the ICV on the right atrium; *b*) compression of the hemiconduct, and *c*) its interference in the case of surgical reintervention.

It is concluded that dilation with an Inoue catheter in this adult patient was an effective intermediate-term treatment method in ICV stenosis after surgery for the scimitar syndrome.

REFERENCES

1. Dupuis C, Charaf LA, Abou CP, Breviere GM. Surgical treatment of the scimitar syndrome in children, adolescents and adults. A cooperative study of 37 cases. *Arch Mal Coeur Vaiss* 1993; 86: 541-547.
2. Najm HK, Williams WG, Coles JG, Rebeyka IM, Freedom RM. Scimitar syndrome: twenty years' experience and results of repair. *J Thorac Cardiovasc Surg* 1996; 112: 1161-1169.
3. Lock JE, Bass JL, Castañeda-Zuñiga W, Fuhrman BP, Rashkind WJ, Lucas RV. Dilation angioplasty of congenital venous channels. *Circulation* 1984; 70: 457-464.
4. Ward C, Mullins Ch, Nihil MR, Grifka RG, Vick GW 3rd. Use of intravascular stents in systemic venous and systemic venous baffle obstructions. *Circulation* 1995; 91: 2948-2954.
5. Benito F, Sánchez C, Oliver J. Implantación de *stent* en la obstrucción al drenaje venoso sistémico tras la cirugía tipo Mustard en el adulto. *Rev Esp Cardiol* 1997; 50: 904-905.
6. Cheng TO, Yang X, Chen C. Membranous obstruction of the inferior vena cava treated by percutaneous balloon angioplasty. *Circulation* 1994; 89: 896-897.
7. Yang XL, Cheng TO, Chen CR. Successful treatment by percutaneous balloon angioplasty of Budd-Chiari syndrome caused by membranous obstruction of inferior vena cava: 8-year follow-up study. *J Am Coll Cardiol* 1996; 28: 1720-1724.