

ECHOCARDIOGRAPHY-DOPPLER

Exercise Echocardiography to Differentiate Dilated Cardiomyopathy from Ischemic Left Ventricular Dysfunction

Jesús Peteiro Vázquez, Lorenzo Monserrat Iglesias, Eugenia Vázquez Rey, Ramón Calviño Santos, Jose M. Vázquez Rodríguez, Ramón Fabregas Casal, Jorge Salgado Fernández, José A. Rodríguez Fernández, and Alfonso Castro Beiras

Servicio de Cardiología. Hospital Juan Canalejo. A Coruña. España.

Objectives. Previous studies have shown the usefulness of dobutamine echocardiography to differentiate dilated cardiomyopathy (DC) from ischemic left ventricular dysfunction (ILVD), but no studies have been made using exercise echocardiography (EE). We hypothesized that most patients with DC have some contractile reserve and experience an increase in left ventricular ejection fraction (LVEF) during exercise, as opposed to patients with ILVD. Differences in response to EE may be useful to clinically differentiate between these two entities.

Patients and method. Between 1 March 1995 and 1 March 2001, we performed 4,133 EE studies on 3,830 patients. Of 289 patients (8%) with moderate or severe LV dysfunction (biplane LVEF < 41% and left ventricular end-diastolic diameter > 5.2 cm), 207 were excluded: 111 for a history of myocardial infarction; 28 for scarring on echocardiography (regional akinesia/dyskinesia with thinning and/or increased brightness); 13 for previous revascularization procedures; 9 for aortic valve disease; 11 for a known cause of cardiomyopathy; and 35 for not undergoing angiography. The study group was therefore composed of 82 patients who were encouraged to perform maximal treadmill EE. EE criteria for ILVD were either impaired regional wall motion (RWM) or a decrease/no change in LVEF from baseline to peak exercise, while criteria for DC were RWM improvement/no change and LVEF increase. The ILVD group was formed by 39 patients with stenosis \geq 70% diameter stenosis of a major epicardial coronary artery or major branch vessel. The remaining 43 patients constituted the DC group.

Results. The number of coronary risk factors (ILVD 2.0 ± 1.1 ; DC 1.9 ± 1.1), baseline LVEF (ILVD 30 ± 7 ; DC 30 ± 8), and exercise-induced angina (ILVD 23%; DC 14%) did not differ between groups ($p = \text{NS}$). ILVD patients achieved less Mets (6.6 ± 3.1 vs 8.3 ± 2.8 ; $p < 0.05$), had a lower heart rate \times systolic blood pressure product (22 ± 5 vs 27 ± 7 ; $p < 0.001$), and developed regional and/or global LV dysfunction more frequently (79 vs 28%; $p < 0.001$). Sensitivity, specificity, positive and negative predictive values and global accuracy for ILVD detection were 79% (95% CI: 70-88), 72%

(95% CI: 63-81), 72% (95% CI: 63-81), 79% (95% CI: 67-85), and 76% (95% CI: 69-83), respectively.

Conclusion. Global and/or regional LV function impairment with exercise is accurate in identifying patients with ILVD. This method could reduce the need for invasive procedures.

Key words: *Cardiomyopathy. Coronary artery disease. Exercise. Echocardiography.*

Ecocardiografía de ejercicio para diferenciar la miocardiopatía dilatada de la disfunción ventricular por cardiopatía isquémica

Objetivos. Aunque la ecocardiografía con dobutamina diferencia la miocardiopatía dilatada (MD) de la disfunción ventricular debida a cardiopatía isquémica (DVCI), no existen estudios al respecto con ecocardiografía de ejercicio (EE). Con la hipótesis de que los pacientes con MD pueden tener reserva contráctil, al contrario que aquellos con DVCI, hemos estudiado a enfermos con disfunción ventricular (DV) izquierda sometidos a EE. Entre 1995 y 2001 realizamos 4.133 EE a 3.830 pacientes. De 289 enfermos con DV (fracción de eyección ventricular izquierda [FEVI] por método biplano < 41% y diámetro telediastólico del ventrículo izquierdo > 5,2 cm) se excluyó a 207: 111 por historia de infarto de miocardio; 28 por necrosis (acinesia-discinesia con adelgazamiento o brillo aumentado); 13 por revascularización; 9 por valvulopatía aórtica; 11 por causa conocida de miocardiopatía, y 35 por ausencia de coronariografía.

Pacientes y método. Por tanto, el grupo de estudio estaba formado por 82 pacientes que fueron estimulados a realizar EE máxima en cinta: 39 pacientes con estenosis > 69% en una arteria epicárdica principal o una rama importante formaban el grupo de DVCI y el resto ($n = 43$), el de MD. El criterio para DVCI era empeoramiento de la motilidad segmentaria o descenso o igual FEVI con el ejercicio, mientras que el criterio para MD era mejoría o ausencia de cambio en la motilidad segmentaria y aumento de la FE.

Resultado. El número de factores de riesgo coronario (DVCI, $2,0 \pm 1,1$; MD, $1,9 \pm 1,2$), FEVI basal (DVCI, 30 ± 7 ; MD, 30 ± 8) y porcentaje de aparición de angina (DVCI, 23%; MD, 14%) eran similares ($p = \text{NS}$), mientras que los pacientes con DVCI alcanzaron menos Mets ($6,6 \pm 3,1$ frente

Correspondence: Dr. J. Peteiro Vázquez.
P.º Ronda, 5, 4.º izqda. 15011 A Coruña. España.
E-mail: jpeteiro@mun-do-r.com

Received 21 February 2002.
Accepted for publication 19 August 2002.

ABBREVIATIONS

AMI: acute myocardial infarction.
CAD: coronary artery disease.
ECG: electrocardiogram.
EE: exercise echocardiography.
VDIC: ventricular dysfunction due to ischemia.
LVEF: left ventricle ejection fraction.
DM: dilated cardiomyopathy.
RSM: regional segment motility.

a $8,3 \pm 2,8$; $p < 0,05$) y producto frecuencia cardíaca \times presión arterial (22 ± 5 frente a 27 ± 7 ; $p < 0,001$), y desarrollaron disfunción regional o global más frecuentemente (79 frente a 28%; $p < 0,001$). La sensibilidad, el especificidad, el valor predictivo positivo y negativo y la precisión diagnóstica para DVCI fueron del 79% (IC del 95%, 70-88), 72% (63-81), 72% (63-81), 79% (67-85) y 76% (69-83).

Conclusión. En conclusión, una respuesta de empeoramiento de la función ventricular con el ejercicio identifica a los pacientes con DVCI con razonable precisión diagnóstica. La EE puede reducir, por tanto, la necesidad de procedimientos invasivos.

Palabras clave: Miocardiopatía. Enfermedad coronaria. Ejercicio. Ecocardiografía.

Full Spanish text available at: www.revespcardiol.org

INTRODUCTION

Exercise echocardiography (EE) has improved diagnostic accuracy in the detection of coronary artery disease (CAD) in patients with a possible diagnosis of CAD.¹⁻³ Lower diagnostic accuracy, nevertheless, has been reported in patients with left ventricular dysfunction.⁴ Left ventricular dysfunction in patients with suspected CAD may be due to ischemic cardiopathy or dilated cardiomyopathy (DM). Although studies have shown the usefulness of dobutamine stress echocardiography in distinguishing between these 2 entities,^{5,6} there are no studies published on the utility of EE in this regard.

Since there is speculation that the majority of patients with DM may have a certain degree of contractile reserve and, therefore, an increased left ventricular ejection fraction (LVEF) during exercise, as compared with patients with ventricular dysfunction due to severe coronary stenosis, we reviewed our database of patients with suspected clinical CAD and moderate or severe left ventricular dysfunction who underwent EE and coronary angiography.

PATIENTS AND METHODS

Patients

Between March 1, 1995, and March 1, 2001, we performed 4133 EEs on 3830 patients. Of the 289 patients (8%) who had moderate or severe left ventricular dysfunction, as defined by an LVEF calculated by the biplane method of less than 41% and a telediastolic diameter of the LV > 5.2 cm, 289 were excluded, 111 due to a clinical history of acute myocardial infarct (AMI); 28 after baseline echocardiography showed scarring (akinesia-dyskinesia with narrowing or increased brilliance),¹³ due to previous coronary revascularization procedures, 9 due to aortic valvulopathy, 11 due to a known cause of cardiomyopathy, and 35 due to lack of coronary angiography. Patients included before January 1, 2000, were studied retrospectively. Of 45 potentially eligible patients, 20 were excluded (18 had EE suggesting the presence of DM) because the patient or their physician refused coronary angiography. The rest of the patients were studied retrospectively. Of the 82 eligible patients, only 15 were excluded for refusing coronary angiography (6 with EE suggesting the presence of DM).

The study group, therefore, was made up of 82 patients who underwent treadmill exercise, echocardiography and coronary angiography. All patients gave informed consent.

Exercise echocardiography

Treadmill ergometry was performed according to standard procedures adjusted to each patient's characteristics (Bruce for 64 patients; modified Bruce for 14 patients, Naughton for 4 patients) with careful monitoring of ECG, arterial pressure, and echocardiographic image. Reasons for interrupting the test were: reaching the predetermined maximum cardiac frequency; the appearance of angina or dyspnea; exhaustion; hypertension (arterial systolic pressure [ASP] > 240 mm Hg and/or arterial diastolic pressure [ADP] > 110 mm Hg); hypotension (decrease $= 20$ mm Hg with respect to the previous ASP); and the presence of severe arrhythmia or evidence of worsening of ventricular function on echocardiography.

Two-dimensional echocardiography was performed with machines that were equipped for digital image processing (Vingmed CFM 750, Horten, Norway; HP-5500, Agilent Technologies, Mass., USA; Vivid 5, GE Vingmed Sound, Horten, Norway) in the longitudinal parasternal and transverse planes, and 4-chamber and 2-chamber in the apical planes at baseline and at the peak of exercise, as we have described previously.⁷ Briefly, when the patient becomes tired or symptoms exist, we acquire the data in the apical planes at the

peak of exercise holding the transducer with the right hand and using pressure on the patient's back with the left hand to assist; we then acquire data on the parasternal planes. If the patient is running at that time, we ask the patient to walk during the acquisition of data.

Baseline images were analyzed and compared to the peak images. The left ventricle was divided into 16 segments.⁸ The appearance of a new regional dysfunction or the worsening of hypokinesia was considered to be an ischemic response. The presence of necrotic tissue, suggested by extensive regional akinesia or dyskinesia with narrowing or increased brilliance at baseline prompted exclusion from the study. We calculated the regional segment motility index (RSM) at baseline and at the peak of exercise, scoring the normal segments 1, the hypokinetic segments 2, akinetic segments 3, and dyskinetic segments 4, and dividing the sum of the scores of the various segments by the overall number of segments.

All studies were analyzed by 2 experienced observers, who had no knowledge of the clinical or angiographic data. There was agreement in 93% of the segments analyzed, and the discrepancies were resolved by consensus for the remaining 7%. The baseline and peak LVEF were measured beginning with the 4-chamber and 2-chamber apical images using the Simpson biplane method.⁹ In addition, in order to study the reproducibility of the diagnosis, 2 experienced observers reanalyzed the data blindly of 30 EEs selected randomly for the diagnosis of DM or ventricular dysfunction due to ischemic cardiopathy (VDIC). The intra-observer concordance was 83% and the inter-observer concordance was 87%, with an index K of 0.67 (intra-observer) and 0.73 (inter-observer).

The criteria for VDIC was worsening of the RSM index or a decrease or no change in the LVEF from baseline to exercise peak, and the criteria for DM was improvement or no change in the RSM index and improvement of LVEF with exercise equal to 1 point.

Coronary angiography

Coronary angiography was performed within 16 weeks before (8% of patients) or after (92% of patients) the EE. A total of 39 patients who presented with narrowing of the lumen diameter of more than 69% in an epicardial artery or a major coronary branch constituted the VDIC group. Thirty-four of these patients (87%) had multi-vessel disease (3 vessels in 18 patients; 2 vessels in 16 patients); 28 patients had severe stenosis in the proximal portion of the anterior descending coronary artery and 5 patients had severe stenosis in the common trunk, 5 patients (13%) had single vessel disease, which affected the proximal third of the anterior descending artery in 2 patients.

The remaining 43 patients comprised the DM group. Of these, 39 patients had normal coronary arteries, and 4 presented with coronary stenosis of less than 70%.

Statistical analysis

The continuous variables are expressed as mean±standard deviation (SD) and were compared using the Student t test comparing patients with VDIC and patients with DM. The noncontinuous variables were compared using the Pearson χ^2 test or the exact Fisher test. A value of $P<.05$ was considered significant. The sensitivity, specificity, positive and negative predictive values, and diagnostic precision (with 95% confidence intervals [CI]) for the diagnosis of VDIC were calculated by the usual methods.¹⁰

The variables with significant differences between groups in univariate analysis were introduced in a step by step conditional logistical regression multivariate analysis.

RESULTS

The patients with VDIC had a higher mean age and there was a higher percentage of patients taking angiotensin-converting enzyme inhibitors (ACEI). There were no differences between the 2 groups of patients with regard to clinical characteristics, medications, electrocardiogram, or mitral regurgitation at baseline (Table 1), while there were significant differences with regard to hemodynamic response to exercise (Table 2). The patients with VDIC achieved a lower maximum cardiac frequency and the product of maximum cardiac frequency multiplied by peak arterial systolic pressure (CF×PAS), as well as a more reduced exercise capacity. Scoring of peak RSM was higher, and the peak LVEF was lower in the patients with VDIC. The percentage of patients who complained of precordial pain was similar in both groups. In the group of patients with DM, the test was suspended due to exhaustion in 42 patients and due to increased angina in 1 patient; in the group of patients of VDIC the test was suspended due to exhaustion in 30 patients, due to intermittent claudication in 7 patients, due to hypertension in 1 patient, and due to hypotension in 1 patient. The exclusive finding of claudication as the cause of suspending the test, although of sensitivity (18%) this part makes no sense; please check, turned out to have a high negative predictive value (100%).

Of the 39 patients with VDIC, 25 developed new RSM changes (sensitivity, 64%) and in 23 patients LVEF was lower or the same (sensitivity, 59%). The RSM score index worsened 0.15 ± 0.25 ($P<.001$; range, 0.93 to -0.50) and the LVEF score -1 ± 9 ($P=NS$; range, -24 to $+17$). The LVEF decreased in 18 patients,

TABLE 1. Baseline clinical, electrocardiographic, and mitral regurgitation data

	VDIC (n=39)	DM (n=43)	P
Age, years	65±9	61±10	<.05
Men, %	33 (85)	27 (63)	<.05
Smoking, %	16 (41)	13 (30)	NS
Arterial hypertension, %	21 (54)	26 (60)	NS
Diabetes mellitus, %	12 (31)	8 (19)	NS
Total cholesterol ≥240 mg/100 ml, %	22 (56)	27 (63)	NS
Family history of CAD	6 (15)	9 (21)	NS
Coronary risk factors, n	2.0±1.1	1.9±1.2	NS
Symptoms			
Angina, %	20 (51)	20 (47)	NS
Dyspnea, %	10 (26)	18 (42)	NS
Dyspnea+angina, %	8 (21)	5 (12)	NS
Asymptomatic (FV), %	1 (3)	0 (0)	NS
Nitrates, %	11 (28)	11 (26)	NS
Calcium antagonists, %	3 (8)	3 (7)	NS
Beta-blockers, %	3 (10)	2 (5)	NS
ACEI, %	30 (77)	21 (49)	<.05
Digoxin, %	6 (15)	13 (30)	NS
Diuretics, %	20 (51)	20 (47)	NS
Atrial fibrillation, %	4 (10)	9 (21)	NS
Left branch block, %	17 (44)	25 (47)	NS
Mitral regurgitation*, %	19 (49)	24 (56)	NS

*Jet area estimated by using color Doppler ≥2.5 cm² in the 4-chamber apical plane. VDIC indicates ventricular dysfunction due to ischemic cardiopathy; DM, dilated myocardopathy; VF, ventricular fibrillation.

remained the same in 5 patients, and increased in 16 patients. In 31 patients, we observed changes in RSM, or decreased or same LVEF (sensitivity, 79%) (Figure 1); in 8 patients the presence of CAD was ruled out; 6 of these patients had multi-vessel disease. The sensitivity was greater in the 18 patients with 3-vessel disease, in whom the combined criteria allowed the

detection of illness in 16 patients (89%).

Of the remaining 43 patients with DM, we found new RSM abnormalities in 5 (specificity, 88%), and in 10 patients we observed lower or the same FE (specificity, 77%). The RSM score index decreased 0.08±0.23 ($P<.05$; range, 0.88 to -0.44), and the LVEF increased 4±7 ($P<.001$; range, -16 to +17). The LVEF improved

TABLE 2. Hemodynamic data and clinical response and exercise ECG

	VDIC (n=39)	DM (n=43)	P
Baseline CF, beats/min	84±13	88±16	NS
Maximum CF, beats/min	137±20	154±23	<.01
Baseline ASP, mm Hg	134±22	146±21	<.05
Maximum ASP, mm Hg	161±31	175±29	<.05
Product of baseline CF×baseline ASP (10)3	11.3±2.6	12.8±2.9	<.05
Product of maximum CF×maximum ASP (10)3	22.0±5.3	27.0±6.5	<.001
Percentage of maximum CF predicted by age reached	89±13	99±14	<.01
Mets	6.6±3.1	8.3±2.8	<.05
Baseline RSM index	1.97±0.20	1.98±0.19	NS
Peak RSM index	2.12±0.26	1.90±0.31	<.01
Baseline LV telediastolic volume, ml	125±44	132±45	NS
Peak LV telediastolic volume, ml	126±48	118±42	NS
Baseline LVEF	30±7	30±8	NS
Peak LVEF	28±10	34±10	<.05
Angina during EE, %	9 (23)	6 (14)	NS
Claudication during EE, %	7 (18)	0 (0)	<.05
Overall or regional dysfunction induced by exercise, %	31 (79)	12 (28)	<.001
ECG			
Normal, %	4 (10)	3 (7)	NS
Ischemia, %	3 (8)	2 (5)	NS
Not diagnostic, %	31 (82)	38 (88)	NS

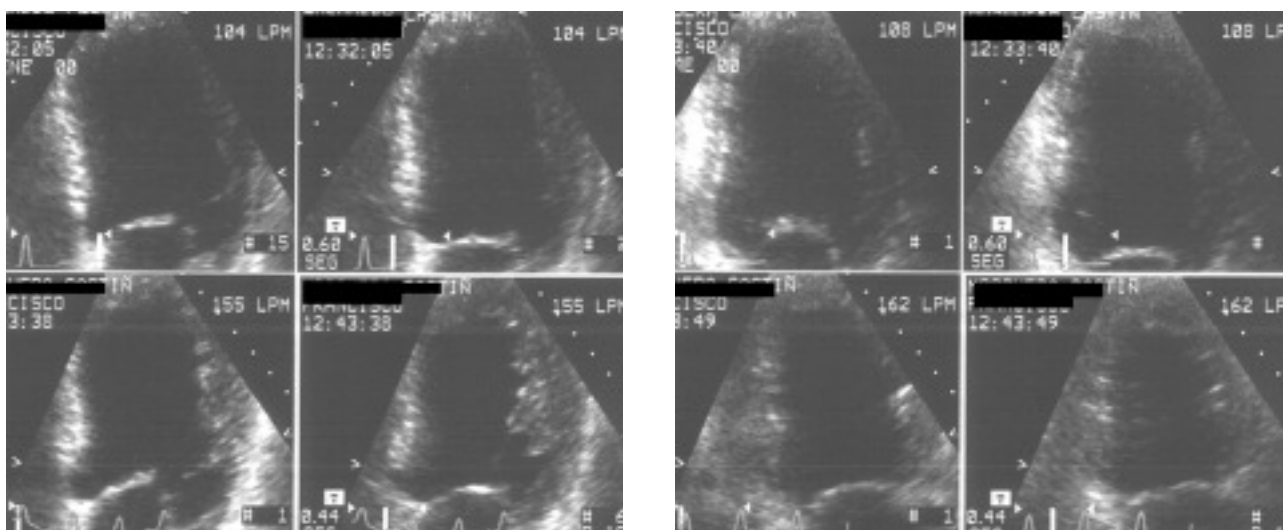


Fig. 1. Example of a patient with nonischemic dilated cardiomyopathy. Echocardiography reveals overall LV dysfunction at rest (above; cardiac frequency 104 beats per minute, LVEF 24%), which improved on the peak exercise image (below; cardiac frequency 162 beats per minute, LVEF 34%). The patient achieved 9 Mets and the product of the cardiac frequency X maximum arterial pressure was 24×10 (3). 4c indicates 4-chamber apical plane; 2c, 2-chamber apical plane; S, systolic image; D, diastolic image.

in 33 patients (Figure 2), remained the same in 1 patient, and worsened in 9 patients. Of 12 patients with false positive results for CAD, 1 had 65% stenosis in the circumflex artery and 50% in the right coronary artery, both distally.

Table 3 shows the sensitivity, specificity, and positive and negative predictive values, as well as the overall diagnostic precision of clinical positivity, worsening of RSM, and decrease in overall LVEF for the detection of heart disease.

On multivariate analysis VDIC predictors were positive EE (OR, 7.9; 95% CI, 2.6-23.6; $P < .0001$), masculine sex (OR, 3.6; 95% CI, 1.0-12.4; $P < .05$) and the product $FC \times ASP$ (OR, 1.0; 95% CI, 1.0-1.0; $P < .05$).

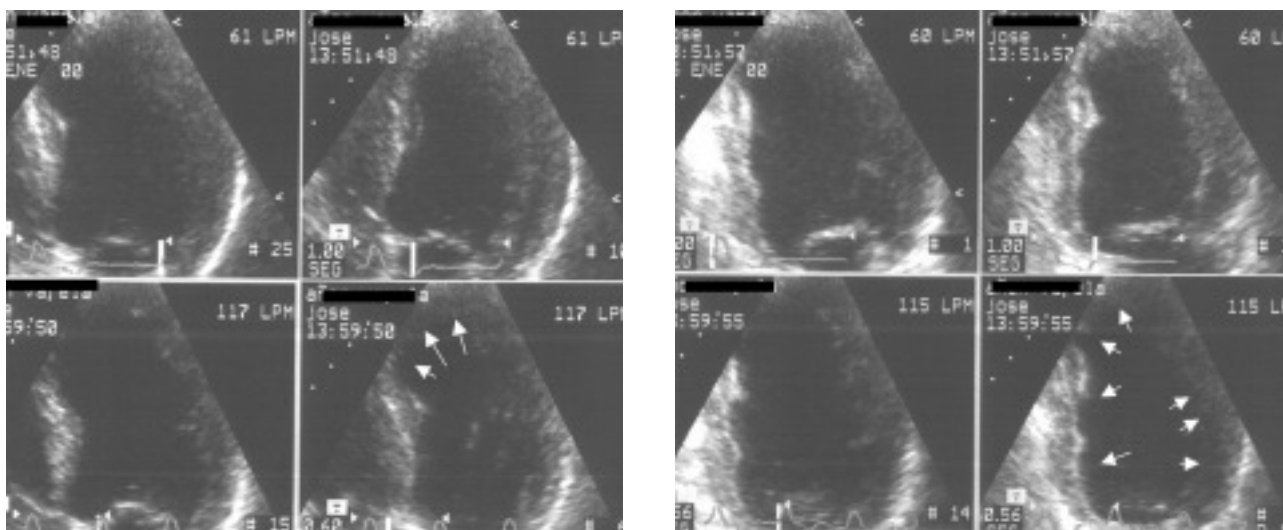


Fig. 2. Example of a patient with ischemic dilated cardiomyopathy. Echocardiography revealed an overall LV dysfunction (above; cardiac frequency 61 beats per minute, LVEF 34%) and in the peak exercise image (below; cardiac frequency 117 beats per minute; LVEF, 34%). Note the appearance of regional motility abnormalities, induced by exercise, in the apex, the inferior wall, and the anterobasal wall (arrows), which correlates with severe stenosis in the anterior descending and right coronary arteries, documented by coronary angiography. The patient achieved 7 Mets and the product of the cardiac frequency multiplied by maximum arterial pressure was 15.9×10 (3). 4c indicates 4-chamber apical plane; 2c, 2-chamber apical plane; S, systolic image; D, diastolic image.

TABLE 3. Sensitivity, specificity, positive and negative predictive values, and diagnostic precision for exercise-induced angina, new regional segment motility abnormalities, and lack of improvement in LVEF with exercise for the diagnosis of coronary artery disease in 82 patients with overall left ventricular systolic function

	Sensitivity (CI)	Specificity (CI)	PPV (CI)	NPV (CI)	Dx precision (IC)
Angina	23% (14-32)	86% (79-93)	60% (45-75)	55% (47-63)	56% (49-63)
New RSM changes	59% (49-69)	77% (69-85)	70% (60-80)	67% (58-76)	68% (61-75)
No LVEF improvement	64% (54-74)	88% (81-95)	83% (72-94)	73% (64-82)	77% (70-84)
New RSM changes and/or no LVEF improvement	79% (70-88)	72% (63-81)	72% (63-81)	79% (70-88)	76% (69-83)

CI indicates confidence interval (95%); PPV, positive predictive value; NPV, negative predictive value; RSM, regional segment motility

DISCUSSION

The differentiation of VDIC from DM using clinical criteria and ECG may be difficult in certain patients. In both cases angina may exist, as may Q-waves on ECG.

Present study

The most important finding of this study is that EE can differentiate VDIC from DM with a reasonable degree of diagnostic precision, measuring changes in overall and regional systolic function with exercise. For this study, we carefully selected patients with overall LV dysfunction and CAD symptoms. In many of the patients in the study, the diagnosis of ventricular dysfunction was made in the same stress echocardiography suite, which explains the decreased utilization of ACEI. In contrast with other studies that used different techniques,^{5,12,13} we excluded those patients with clinical or echocardiographic evidence of previous AMI, who could be easily classified as patients with VDIC. The majority of patients with DM had some inotropic reserve, while the majority of the patients with VDIC experienced a worsening of overall or regional systolic function with exercise. Until now, there have been no studies that evaluated the role of EE in distinguishing DM from VDIC. Hayakawa et al¹⁴ studied the response of LVEF to exercise in 24 patients with DM using echocardiography, and showed an increase in 17 patients (71%) and a lack of change in 7 patients (29% who had more dilated ventricles).

Left ventricle dysfunction in ischemic cardiopathy and dilated myocardopathy

The overall LV dysfunction in patients with VDIC may be due to chronic hypoperfusion (hibernating myocardium) or to previous multiple myocardium infarcts. Several studies that used dobutamine stress echocardiography^{15,16} have shown that patients with CAD and a dysfunctional, viable myocardium have a biphasic response to dobutamine, with improvement at low doses and worsening at high dosages, and patients with predominant scar tissue can present with a lack of

response to dobutamine or a sustained improvement due to the recruitment of the normal myocardium. An improvement in regional motility, such as that induced with low doses of dobutamine, has also been described with low levels of bicycle exercise in heart patients with severe left ventricular dysfunction.¹⁷ Nevertheless, no studies have evaluated whether an underlying worsening occurs with maximum or less than maximum exercise. Our data, based on a high exercise load on treadmill, suggest that the majority of patients in the VDIC group had a viable ischemic myocardium, given that contractile function worsened at peak exercise. On the other hand, the fact that the majority of our patients with DM showed an improvement in systolic function with exercise suggests that the myocardium was not totally replaced by fibrotic tissue, as occurs in later phases of this process. Unfortunately, we do not know the state of the patients with DM. Of the 12 patients with DM and false positive results for CAD, only 1 had slight or moderate coronary lesions. Nevertheless, it is not clear whether these nonsevere lesions could induce ischemia.

Isotopic studies

Cardiac gammagraphy has been used to investigate the left ventricular response to exercise in patients with non-ischemic DM,^{18,19} as well as in patients with systolic dysfunction after an AMI.²⁰ Kirilin et al¹⁸ found an increase in ventricular volumes and the absence of LVEF changes with exercise in patients with DM (22%±2% baseline vs 23%±3% with exercise), although the differences between patients were substantial. Suzuki et al,¹⁹ on the other hand, found an increase in LVEF with exercise in 11 of 20 patients with DM (55%). Shen et al,²⁰ via cardiac gammagraphy, observed that LVEF increased in patients with DM, but did not change in patients with left ventricular dysfunction secondary to AMI due to the increase in telesystolic volume.

The use of thallium-201 gammagraphy perfusion [something missing here? «to detect?>] defects in DM have been described; therefore this technique

cannot really distinguish the 2 entities.²¹ The radiotracer deposit is less in the areas with more severe dysynergy, probably reflecting fibrosis.²² The presence of a complete block of the left branch in many patients with ventricular dysfunction is an additional limitation of thallium gammography.²³ Positron emission tomography seems to be capable of distinguishing dilated ischemic cardiomyopathy (DIM) from nonischemic dilated ischemic cardiomyopathy (NDIM);²⁴ however, technique is expensive and not readily available.

Dobutamine echocardiography

Low-dose and high-dose dobutamine stress echocardiography has been used to distinguish between DM and VDIC.^{5,6,13} In 2 studies,^{5,6} researchers observed that a response of progressive improvement characterized the patients with DM, while a biphasic response was typical in patients with VDIC. Through the use of these different responses, echocardiography with dobutamine reaches high levels of sensitivity (80%-83%) and specificity (71%-96%), which does not differ from our results with EE. Another study, however, yielded conflicting results¹³ given that, although a biphasic response was observed with greater frequency in the group with heart disease, achieving high specificity (95%), the sensitivity level was low (25%).

Magnetic resonance (MR)

The gadolinium used during MR accumulates in areas of fibrosis, and therefore it has been used to study viability after the occurrence of AMI.²⁵ A recent study showed that the gadolinium accumulated in 100% of the patients with VDIC but in only 41% of patients with DM.²⁶

Limitations

The principal limitation of our study is that it uses a new technique for detecting ischemia during EE.⁷ Therefore, our results may not be reproducible by using traditional treadmill EE (that is, obtaining the image following exercise). It would be interesting to perform additional studies with echocardiography at the peak of exercise or during exercise that would validate our results. Another limitation of stress echocardiography in general is that it involves research that is largely dependent on the technique used, which in turn requires extensive experience on the observer's part; 1 study documented a great deal of variability in the interpretation of studies among centers.²⁷

According to our results, approximately 25% of patients will receive an erroneous diagnosis if EE is

used, focusing clinical interest and treatment on specific patients (for example, when catheterization is not being considered).

We placed the angiographic limit for the diagnosis of CAD at 70% lumen narrowing, instead of the more commonly used 50%, as the majority of patients with VDIC present with lesions that severely limit flow and because elderly patients with DM may develop slight or moderate coronary lesions. Nevertheless, only 4 patients (9%) in the group with VDIC had slight or moderate coronary lesions. On the other hand, 5 patients in the group with ischemia had severe coronary lesions but these were limited to 1 vessel. Although heart disease may not be the cause of DM in these 5 patients, the EE detected the presence of heart disease in 3 of them.

CONCLUSION

Differentiating between DM and ischemic ventricular dysfunction is a challenge in the absence of typical frequent chest angina, a history of AMI, evidence of extensive scarring on echocardiography, or clear perfusion defects on thallium gammography. Treadmill EE is a safe, cheap, widely-available technique that can offer diagnostic information on these patients. A response of overall or regional systolic dysfunction with exercise identified patients with DMA with adequate sensitivity and specificity.

BIBLIOGRAFÍA

1. Armstrong WF, O'Donnell J, Ryan Th, Feigenbaum H. Effect of prior myocardial infarction and extent and location of coronary artery disease on accuracy of Exercise Echocardiography. *J Am Coll Cardiol* 1987;10:531-8.
2. Maurer G, Nanda NC. Two-dimensional echocardiographic evaluation of exercise-induced left and right ventricular asynergy: correlation with thallium scanning. *Am J Cardiol* 1981;48:720-7.
3. Crouse LJ, Harbrecht JJ, Vacek JL, Rosamond TL, Kramer PH. Exercise echocardiography as a screening test for coronary artery disease and correlation with coronary angiography. *Am J Cardiol* 1991;67:1213-8.
4. Roger VL, Pellicka PA, Oh JK, Bailey KR, Tajik AJ. Identification of multivessel coronary artery disease by exercise echocardiography. *J Am Coll Cardiol* 1994;2:109-14.
5. Sharp SM, Sawada SG, Segar DS, Ryan Th, Kovacs R, Fineberg NS, et al. Dobutamine stress echocardiography: Detection of coronary artery disease in patients with dilated cardiomyopathy. *J Am Coll Cardiol* 1994;24:934-9.
6. Vigna C, Russo A, De Rito V, Perna GP, Testa M, Lombardo A, et al. Regional wall motion analysis by dobutamine stress echocardiography to distinguish between ischemic and non ischemic dilated cardiomyopathy. *Am Heart J* 1996;131:537-43.
7. Peteiro J, Fabregas R, Monserrat L, Álvarez N, Castro-Beiras A. Comparison of treadmill exercise echocardiography before and after exercise in the evaluation of patients with known or suspected coronary artery disease. *J Am Soc Echocardiogr* 1999;12: 1073-9.

8. Bourdillon PD, Broderik TM, Sawada SG, Armstrong WF, Ryan T, Dillon JC, et al. Regional wall motion index for infarct and noninfarct regions after reperfusion in acute myocardial infarction: comparison with global wall motion index. *J Am Soc Echocardiogr* 1989;9:398-407.
9. Schiller NB, Shan PM, Crawford M, De Maria A, Devereux R, Feigenbaum H, et al. Recommendations for quantification of the left ventricle by two dimensional echocardiography. *J Am Soc Echocardiogr* 1989;2:358-67.
10. Latour J, Abaira V, Cabello JB, López Sánchez J. Métodos de investigación en cardiología clínica (IV). Las mediciones en cardiología: validez y errores de medición. *Rev Esp Cardiol* 1997;50:117-28.
11. Dec GW, Fuster V. Medical progress. Idiopathic dilated cardiomyopathy. *N Engl J Med* 1994;331:1564-70.
12. Shen WF, Roubin GS, Hirasawa K, Choong CY, Hutton BF, Harris PJ, et al. Left ventricular volume and ejection fraction response to exercise in chronic congestive heart failure: difference between dilated cardiomyopathy and previous myocardial infarction. *Am J Cardiol* 1985;55:1027-31.
13. Cohen A, Chauvel C, Benhalima B, Guyon P, Desert I, Valty J. Is dobutamine stress echocardiography useful for noninvasive differentiation of ischemic from idiopathic dilated cardiomyopathy? *Angiology* 1997;48:783-93.
14. Hayakawa M, Inoh T, Kawanishi H, Kaku K, Kumaki T, Yokota Y, et al. Evaluation of left ventricular function in patients with dilated cardiomyopathy by exercise echocardiography. *J Cardiol* 1982;12:605-12.
15. Afridi Y, Kleiman NS, Raizner AE, Zoghbi WA. Dobutamine echocardiography in myocardial hibernation. Optimal dose and accuracy in predicting recovery of ventricular function after coronary angioplasty. *Circulation* 1995;91:663-70.
16. Senior R, Lahiri A. Enhanced detection of myocardial ischemia by stress dobutamine echocardiography utilizing the «biphasic» response of wall thickening during low and high dose dobutamine infusion. *J Am Coll Cardiol* 1995;26:26-32.
17. Hoffer EP, Dewe W, Celentano C, Pierard LA. Low-level exercise echocardiography detects contractile reserve and predicts reversible dysfunction after acute myocardial infarction. Comparison with low-dose dobutamine echocardiography. *J Am Coll Cardiol* 1999;34:989-97.
18. Kirlin PC, Das S, Zijnen P, Wijns W, Domenicucci S, Roelandt J, et al. The exercise response in idiopathic dilated cardiomyopathy. *Clin Cardiol* 1984;7:205-10.
19. Suzuki T, Kanda T, Nagaoka H, Kubota S, Iizuka T, Nagai R, et al. Predictive value of left ventricular response to exercise in patients with dilated cardiomyopathy—assessment by radionuclide ventriculography. *Angiology* 1997;48:497-502.
20. Shen WF, Roubin GS, Hirasawa K, Choong CY, Hutton BF, Harris PJ, et al. Left ventricular volume and ejection fraction response to exercise in chronic congestive heart failure: difference between dilated cardiomyopathy and previous myocardial infarction. *Am J Cardiol* 1985;55:1027-31.
21. Dunn RF, Uren RF, Sadick N, Bautovich G, McLaughlin A, Hiroe M, et al. Comparison of thallium-210 scanning in idiopathic dilated cardiomyopathy and severe coronary artery disease. *Circulation* 1982;66:804-10.
22. Yamaguchi S, Tsuiki K, Hayasaka M, Yasui S. Segmental wall motion abnormalities in dilated cardiomyopathy: hemodynamic characteristics and comparison with thallium-201 myocardial scintigraphy. *Am Heart J* 1987;113:1123-8.
23. Mairesse GH, Marwick ThH, Arnesi M, Vanoverschelde J, Cornel JH, Detri JMR, et al. Improved identification of coronary artery disease in patients with left bundle branch block by use of dobutamine stress echocardiography and comparison with myocardial perfusion tomography. *Am J Cardiol* 1995;76:321-5.
24. Eisenberg JD, Sobel BE, Geltman EM. Differentiation of ischemic from nonischemic cardiomyopathy with positron emission tomography. *Am J Cardiol* 1987;59:1410-4.
25. Klein C, Nekolla SG, Bengel FM, Momose M, Sammer A, Haas F, et al. Assessment of myocardial viability with contrast-enhanced magnetic resonance imaging: comparison with positron emission tomography. *Circulation* 2002;105:162-7.
26. McCrohon JA, Moon JC, Murphy RT, Lorenz CH, Pennell DJ. A new imaging perspective in ischemic and idiopathic dilated cardiomyopathy using cardiovascular magnetic resonance. *J Am Coll Cardiol* 2002;39(Suppl A):150A.
27. Hoffmann R, Lethen H, Marwick T, Arnesi M, Fioretti P, Pingitore A, et al. Analysis of interinstitutional observer agreement in interpretation of dobutamine stress echocardiograms. *J Am Coll Cardiol* 1996;27:330-6.