

BRIEF REPORTS

Right Atrial Pheochromocytoma

Rubén A. Cabo,^a Evaristo Castedo,^a Miguel Pastrana,^a Ricardo Crespo,^b Carlos G. Montero^a and Juan Ugarte^a

^aDepartamento de Cirugía Cardiovascular, Clínica Puerta de Hierro, Madrid, Spain.

^bDepartamento de Medicina Interna, Hospital Virgen de la Salud, Toledo, Spain.

Pheochromocytoma is a catecholamine-producing tumor and a rare cause of hypertension. Most cases are intra-adrenal and intrapericardial pheochromocytomas are extremely uncommon. We report the case of a 46-year-old woman with a 1-year history of hypertension, in which a right atrial pheochromocytoma was detected after a hypertensive crisis. ¹³¹I-metaiodobenzylguanidine scintigraphy and magnetic resonance imaging established the diagnosis. The tumor was successfully resected using cardiopulmonary bypass and the right atrium was reconstructed using bovine pericardium.

Key words: *Cardiac tumors. Pheochromocytoma. Surgery.*

Full English text available at: www.revespcardiol.org

INTRODUCTION

Pheochromocytoma is a generally benign, catecholamine-producing tumor and a rare cause of hypertension. Approximately 0.1% to 2% of hypertensive individuals have a pheochromocytoma.^{1,2} The tumor is usually found in the adrenal gland, with the intrapericardial site extremely infrequent.¹⁻¹⁰ We report the case of a primary right atrial pheochromocytoma. The tumor was successfully resected using cardiopulmonary bypass and the atrium wall was reconstructed using bovine pericardium.

CLINICAL CASE

A 46-year-old woman with a one-year history of hypertension presented in the emergency room for palpitations, sweating, dyspnea and a feeling of anxiety. On physical examination, blood pressure was 170/100

Feocromocitoma de aurícula derecha

El feocromocitoma es un tumor productor de catecolaminas y una causa infrecuente de hipertensión arterial. La mayoría están localizados en la glándula suprarrenal, siendo la localización intrapericárdica una rareza. Describimos el caso de una paciente de 46 años, hipertensa de un año de evolución, a la que tras una crisis hipertensiva se le diagnosticó un feocromocitoma de aurícula derecha mediante gammagrafía con ¹³¹I-metaiodobencilguanidina y resonancia magnética. El tumor fue resecado con éxito mediante circulación extracorpórea y la pared auricular, reconstruida con un parche de pericardio bovino.

Palabras clave: *Tumores cardíacos. Feocromocitoma. Cirugía.*

mm Hg and peripheral pulses were present and symmetrical in all extremities. Urinary noradrenaline levels were elevated (604 g/24 h), and pheochromocytoma was suspected. ¹³¹I-metaiodobenzylguanidine scintigraphy showed uptake in the middle mediastinum and transesophageal echocardiography disclosed a 29 × 36 mm mass in the junction of the superior vena cava and the right atrium. Magnetic resonance imaging confirmed a mediastinal tumor in the lateral wall of the superior vena cava at this site, as well as the absence of distant metastasis (Figure 1A). Cavography revealed an intraluminal filling defect in the right atrium and slow venous return (Figure 1B); coronary angiography showed normal coronaries. Because the clinical symptoms were consistent with cardiac pheochromocytoma, we opted for surgery after administering alpha and beta blockers. Surgery consisted of a midline sternotomy, cardiopulmonary bypass and hypothermia at 32 °C, and complete resection of a 3 × 4 cm tumor with free margins. The tumor was located in the free wall of the right atrium, extending toward the Sondergaard's groove and the junction of the superior vena cava (Figure 2). We used bovine pericardium with 4/0 polypropylene suture to reconstruct the defect. There were no postoperative complications and the patient was discharged six days after surgery.

Correspondence: Dr. E. Castedo.
Departamento de Cirugía Cardiovascular, Clínica Puerta de Hierro.
San Martín de Porres, 4. 28035 Madrid, España.
E-mail: evaristocm@terra.es

Received 3 July 2002.

Accepted for publication 12 December 2002.

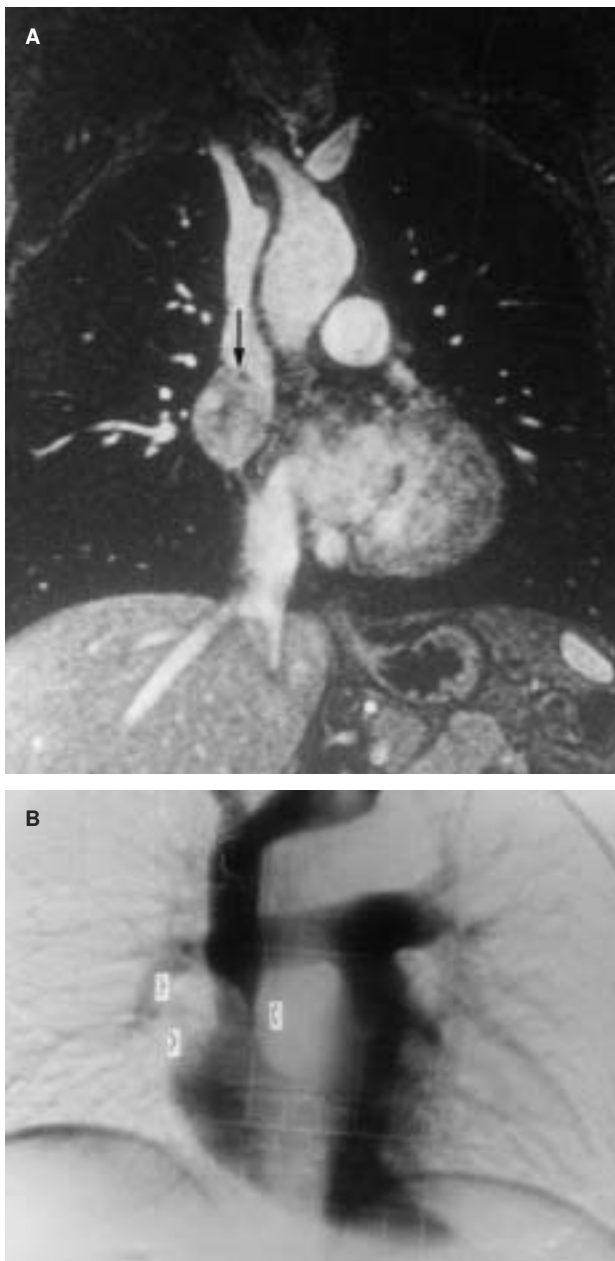


Fig. 1. 3-D magnetic resonance angiography, coronal section: mediastinal tumor, maximum diameter 3.5 cm, solid appearance, vascularized, with central hypodense areas, located in the lateral wall of the superior vena cava at the right atrial junction (arrow) (A). Cavography: intraluminal filling defects (arrows) at the junction of the superior vena cava and the right atrium (B).

Urinary catecholamine levels and blood pressure were normal 6 months later. Histological study confirmed the diagnosis of pheochromocytoma.

DISCUSSION

Paragangliomas are neural crest-derived neuroendocrine cell tumors. Pheochromocytoma is a type of catecholamine-producing paraganglioma derived from the chromaffin cells of the sympathetic nervous sys-

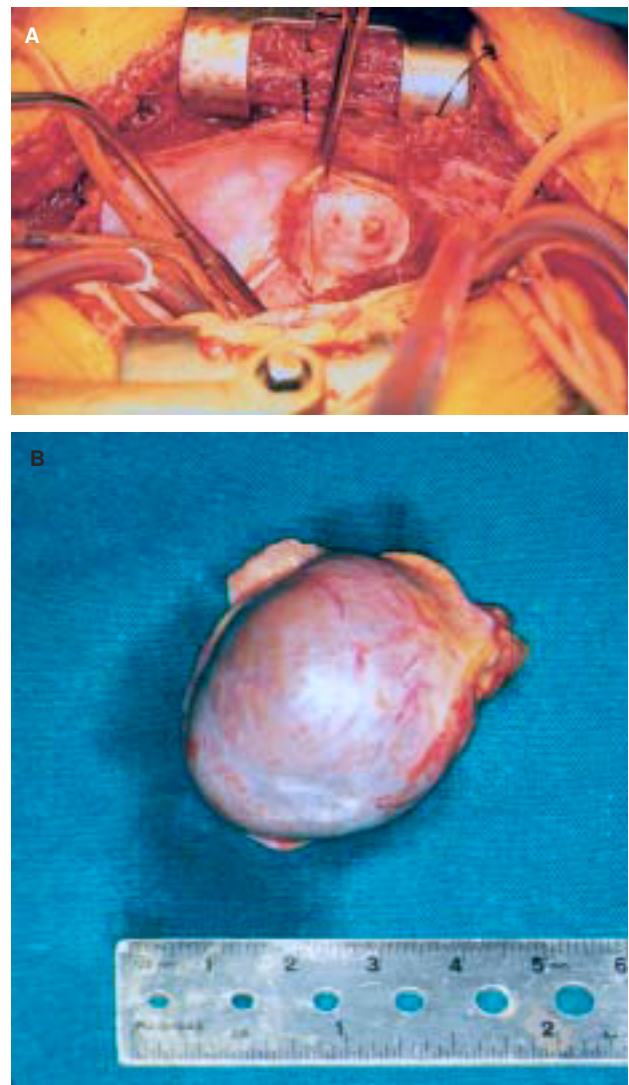


Fig. 2. Intraoperative images: a retractor is used to expose the defect in the atrial wall (A) after tumor excision (B).

tem. Around 12% to 19% are malignant, as evidenced by their metastasis-producing capacity.^{2,4} Pheochromocytomas are usually red or brownish, soft, lobulated and highly vascularized masses; 90% are found in the adrenal glands and less than 2% in the thorax.¹⁻³ Most thoracic pheochromocytomas are located in the posterior mediastinum^{1,3} and develop from ectopic islets of chromaffin cells that persist in the mediastinum instead of being replaced by lymphoid tissue after birth.^{1,2} Intrapericardial pheochromocytomas are rare. In fact no more than 40 cases have been reported worldwide.¹⁻¹⁰ Around 60% of cardiac pheochromocytomas are located in the roof of the left atrium.^{1,3} The rest are located (in order of frequency) in the interauricular septum, the anterior surface of the heart, and the aortopulmonary window. The literature contains two cases of pheochromocytoma involving the right and left atria simultaneously^{6,7} and another

two of metastatic pheochromocytomas extending to the inferior vena cava and right atrium,^{8,9} but there is no report of a single primary tumor in the lateral wall of the right atrium, as observed in our patient. Generally, the tumor appears in young or middle-aged adults and there is no predilection for either sex.¹ Clinically it manifests as uncontrolled hypertension, severe headache, orthostatic hypotension, palpitations, sweating, and abdominal or chest pain. Symptoms resulting from space occupation due to partial compression of the cardiac venous return have also been reported.⁵

Elevated urinary levels of catecholamines and their metabolites will assist the diagnosis, although confirmation requires imaging techniques:

1. Enhanced computed tomography (CT) locates 98% of intra-abdominal pheochromocytomas and 90% of those in the suprarenal medulla.⁴ Supradiaphragmatic pheochromocytomas may go undetected, as they have the same density as heart tissue and are visualized only with rapid bolus administration of contrast material.

2. Magnetic resonance imaging is more sensitive than CT in detecting extra-adrenal pheochromocytomas. The tumor gives a hyperintense signal in T2⁴ and has a solid, vascularized appearance with areas of central hypodensity due to necrosis or hemorrhaging.

3. ¹³¹I-metaiodobenzylguanidine scintigraphy has a sensitivity of 80-88% and a specificity of 98%.⁴ This method is useful when the abdominal CT findings are normal.

4. Indium-octreotide scintigraphy is less specific than the previous technique, although it is able to locate intracardiac somatostatin receptors.^{4,5}

Transesophageal echocardiography and cavography are useful for determining the extension of the tumor and planning surgery. Coronary angiography is also recommended to rule out the invasion or compression of coronary arteries.²

The differential diagnosis includes intracardiac thrombi which, unlike pheochromocytomas, are intravascular lesions, and other wall tumors, such as cardiac myxoma, which usually develop within the cavity,¹¹ and sarcoma in the vena cava.

The response of pheochromocytoma to chemotherapy is very poor,² and therefore the treatment of choice is complete resection with free margins to prevent local recurrence. Depending on the location and extent of the

lesion, three surgical strategies are available: simple excision, excision with reconstruction and heart transplantation. We found two published transplantation cases in cardiac pheochromocytoma: one autotransplantation patient who died of hemorrhage¹⁰ and one orthotopic heart transplantation, in which the patient was alive after 8 months.³ Whenever possible, tumor excision should be attempted, reserving transplantation for extensive masses that cannot be resected due to involvement of the atrioventricular groove, the mitral valve apparatus, the left ventricle or the coronary arteries. Surgery with cardiopulmonary bypass allows safe resection, as it prevents malignant arrhythmias and hypertensive crises when handling the tumor and helps control hemorrhaging. Nevertheless, operative mortality due to bleeding was 20% in the largest series.^{1,3} Reconstruction of part of the heart wall after tumor excision is often necessary, and patches of various materials can be used for this purpose: autologous pericardium,^{1,4} Dacron or, as in our case, bovine pericardium. If metastasis is observed in the nodes of the surgical specimen or in remote organs, the patient should be given postoperative adjuvant chemotherapy for neuroblastoma.²

REFERENCES

1. Jebara VA, Uva MS, Farge A, Acar C, Azizi M, Plouin PF, et al. Cardiac pheochromocytomas. *Ann Thorac Surg* 1992;53:356-61.
2. Jirari A, Charpentier A, Popescu S, Boidin P, Eisenmann B. A malignant primary cardiac pheochromocytoma. *Ann Thorac Surg* 1999;68:565-6.
3. Jeevanandam V, Oz MC, Shapiro B, Barr ML, Marboe C, Rose EA. Surgical management of cardiac pheochromocytoma. Resection versus transplantation. *Ann Surg* 1995;221:415-9.
4. Lin JC, Palafox BA, Jackson HA, Cohen AJ, Gazzaniga AB. Cardiac pheochromocytoma: resection after diagnosis by ¹¹¹indium octreotide scan. *Ann Thorac Surg* 1999;67:555-8.
5. Meunier J, Tatou E, Bernard A, Brenot R, David M. Cardiac pheochromocytoma. *Ann Thorac Surg* 2001;71:712-3.
6. Saad MF, Frazier OH, Hickey RC, Samaan NA. Intrapericardial pheochromocytoma. *Am J Med* 1983;75:371-6.
7. Lee HH, Brenner WI, Vardhan I, Hyatt J, Terlecki M. Cardiac pheochromocytoma originating in the interatrial septum. *Chest* 1990;97:760-2.
8. Rote AR, Flint LD, Ellis FH Jr. Intracaval recurrence of pheochromocytoma extending into right atrium. *N Engl J Med* 1977;296:1269-71.
9. Rötter J, Oberpennig F, Scheld HH, Hertle L, Knichwitz G, Hammel D. Pheochromocytomas with extension into central vascular structures. *Ann Thorac Surg* 1996;61:222-4.
10. Cooley DA, Reardon MJ, Frazier OH, Angelini P. Human cardiac explantation and autotransplantation: application in a patient with a large cardiac pheochromocytoma. *Tex Heart Inst J* 1985;12:171-6.
11. Gabe ED, Rodríguez Correa C, Vigliano C, San Martino J, Wisner JN, González P, et al. Mixomas cardíacos: correlación anatomoclínica. *Rev Esp Cardiol* 2002;55:505-13.