

## INTERVENTIONAL CARDIOLOGY

# Percutaneous Closure of Large Atrial Septal Defects

Marcos Rodríguez,<sup>a</sup> José Suárez de Lezo,<sup>a</sup> Manuel Pan,<sup>a</sup> Miguel Romero,<sup>a</sup> José Segura,<sup>a</sup> Djordje Pavlovic,<sup>a</sup> Juan Muñoz,<sup>a</sup> Manuel Franco,<sup>a</sup> José R. Ortega,<sup>b</sup> and Alfonso Medina<sup>b</sup>

<sup>a</sup>Servicio de Cardiología, Hospital Reina Sofía, Córdoba, Spain.

<sup>b</sup>Servicio de Cardiología, Hospital Dr. Negrín, Las Palmas de Gran Canaria, Spain.

**Background.** Percutaneous occlusion of secundum type atrial septal defect with an Amplatzer device is an effective treatment alternative. However, there is little information about the use of this treatment for large defects.

**Patients and method.** We retrospectively analyzed the initial and follow-up findings in 31 patients aged  $41 \pm 18$  years who had large atrial septal defects ( $\geq 30$  mm diameter). Mean defect diameter evaluated by the balloon occlusion method was  $33.4 \pm 3.4$  mm (range, 30-40 mm). In all patients we attempted the implantation of an Amplatzer septal occluder.

**Results.** The implant was successful in 23 patients (74%); 3 of whom had a double orifice. The size of the device was  $34 \pm 3$  mm diameter (range, 30-38 mm). Combined associated procedures were balloon pulmonary valvuloplasty in 3 patients and coronary stent implantation in 1. In 4 out of 8 patients where we failed, the implant was attempted but the device was unstable so we decided to retrieve it; in the remaining 4 patients, balloon measurement alone contraindicated the procedure. All patients did well, but one had cardiac tamponade during the procedure that was resolved in the catheterization laboratory. After  $15 \pm 12$  months of follow-up all 31 patients were alive and those who had functional limitation before treatment remained stable, with significant clinical improvement.

**Conclusions.** Percutaneous device occlusion of large atrial septal defects is feasible and effective in most patients.

**Key words:** *Congenital heart disease. Atrial septal defect. Catheterization.*

Full English text available at: [www.revespcardiol.org](http://www.revespcardiol.org)

Correspondence: Dr. J. Suárez de Lezo.  
Servicio de Cardiología. Hospital Reina Sofía.  
Avda. Menéndez Pidal, s/n. 14004 Córdoba, Spain.  
E-mail: grupo\_corpal@arrakis.es

Received 28 January 2003.  
Accepted for publication 29 April 2003.

## Cierre percutáneo de comunicaciones interauriculares grandes

**Introducción.** El cierre percutáneo de las comunicaciones interauriculares *ostium secundum* con dispositivo Amplatzer se ha consolidado como un método terapéutico efectivo. Sin embargo, existe poca información en la bibliografía en cuanto al abordaje de defectos amplios mediante esta técnica.

**Pacientes y método.** Estudiamos retrospectivamente los resultados iniciales y la evolución de 31 pacientes, con una edad media de  $41 \pm 18$  años, en los que se demostró una comunicación interauricular con diámetro «distendido» de 30 mm o mayor (media,  $33,4 \pm 3,4$  mm; rango, 30-40 mm) y en los que se intentó el cierre percutáneo a través de un dispositivo ocluidor de Amplatzer.

**Resultados.** El cierre del defecto interatrial fue posible en 23 pacientes (74%), incluidos 3 casos con doble orificio. En cuatro de los 8 pacientes en los que se fracasó se intentó un implante que resultó inestable, por lo que se retiró el dispositivo; en los 4 restantes, la medida con balón fue suficiente para desistir. El diámetro medio de los dispositivos fue de  $34 \pm 2,9$  mm (rango, 30-38 mm). En 3 enfermos se realizó, además, de forma combinada una valvuloplastia pulmonar, y en un paciente se implantaron *stents* por enfermedad coronaria grave. La mortalidad hospitalaria fue nula y sólo se registró como complicación un taponamiento cardíaco resuelto eficazmente en la sala de hemodinámica. Tras un tiempo medio de seguimiento de  $15 \pm 12$  meses, los enfermos que presentaban limitación funcional experimentaron una mejoría clínica significativa.

**Conclusiones.** El cierre percutáneo de defectos interatriales de 30 mm o más con dispositivo Amplatzer se muestra como una alternativa terapéutica eficaz y segura en un alto porcentaje de pacientes.

**Palabras clave:** *Cardiopatías congénitas. Comunicación interauricular. Cateterismo cardíaco.*

## INTRODUCTION

A significant improvement in long-term survival and a considerable reduction in the risk of functional decline have been shown in patients with atrial septal defects (ASD) who undergo surgical repair, compared to those who only receive medical treatment.<sup>1</sup> On the other

## ABBREVIATIONS

ASD: atrial septal defect.  
 AOD: Amplatzer occluder device.  
 TTE: transthoracic echocardiogram.  
 TEE: transesophageal echocardiogram.  
 NYHA: New York Heart Association.

hand, cumulative experience with the use of percutaneous occlusion devices has been such that we are now well into the «era» when secundum-type atrial septal defects can be treated by means of catheterization.<sup>2</sup> In this regard, the Amplatzer occluder device (AOD) has proved safe when by used by experts. There is practically no risk of death, and complications are much fewer than with surgery.<sup>3</sup> In addition, we are beginning to see the results of percutaneous closure of atrial septal defects under certain «complex» conditions (pulmonary hypertension or associated heart malformations, multiple openings, residual defects after previous surgical repair).<sup>4-6</sup> However, there are still large gaps in our understanding of the limitations of this therapeutic modality. In the case of atrial septal defects having a very large diameter, we begin by asking what is considered too «large» for percutaneous closure, since definition thresholds vary widely among series. Furthermore, the development of larger AODs has made it possible to handle defects that were beyond correction until recently.

In this study we take a retrospective look at our experience with closure of atrial septal defects measuring 30 mm in diameter or more by means of catheterization, which is, in our view, a technical and psychological challenge for the cardiologist.

## PATIENTS AND METHODS

### Patients

Of a total of 145 patients having *ostium secundum*-type ASD who underwent percutaneous closure, we selected 31 whose defect was greater than 29 mm in diameter when stretched open, as determined by balloon angiography. There were no significant differences between the study group and the rest of the series in terms of baseline clinical, angiographic, or echocardiographic features, except for age, which turned out to be significantly greater in the study group (41±18 vs 27±9 years;  $P<.005$ ), and, as might be expected, in the size of the ASD. The procedures were performed between January 1998 and June 2002, and informed consent from patients or their tutors was obtained in all cases. In addition to a 12-lead electrocar-

diogram and a chest x-ray, preliminary tests included a transthoracic Doppler echocardiogram (TDE). The purpose was to obtain information about the potential hemodynamic and anatomical consequences of the ASD and to determine if there was any other co-existing condition. Our series was composed of 22 women (71%) and 9 men who ranged in age from 5 to 65 years (mean age, 40.9±18 years). Most of them had a history of frequent colds, and 16 had varying degrees of exertional dyspnea, with 2 patients belonging to functional category IV of the NYHA when admitted. Of note, 5 patients also had other heart problems and 3 women had been diagnosed with severe pulmonary stenosis. Another patient with a history of diabetes mellitus and hypertension had typical exertional angina and positive ergometry results. There was also one child who had undergone surgical repair of Fallot's tetralogy and ASD three years before and who showed extensive dehiscence of the atrial septal patch.

All patients were in sinus rhythm when the study was performed, even though 2 of them had a documented history of paroxysmal atrial fibrillation. Complete or incomplete right bundle branch block was the most frequent electrocardiographic finding (23 cases; 74%), whereas paradoxical movement of the interventricular septum on M-mode electrocardiography was seen in 22 patients (71%).

The clinical features seen in our series are shown in Table 1. After therapy, all patients remained at bed rest for 24 hours, after which they underwent a new clinical, radiologic, and echocardiographic assessment. Patients were discharged 2 to 7 days after implantation. Follow-up consisted of clinical tests and TTE-Doppler 6 to 12 months after implantation of the ASD and once a year thereafter.

TABLE 1. Baseline clinical and echocardiographic features in our series (n=31)

Age, years	41±8 (5-65)
Women	22 (71%)
Functional class (NYHA)	
II	12 (39%)
III	2 (6%)
IV	2 (6%)
Sinus rhythm	31 (100%)
Right bundle branch block	23 (74%)
Enlarged RV on EKG	3 (10%)
Paradoxical movement of the septum on TTE	22 (71%)
Estimated diameter of the ASD as seen on TTE	23.9±3.4
Related conditions	
Obstructive coronary heart disease	1
Pulmonary stenosis	3
Previous surgical closure of the ASD	1

RV indicates right ventricle; ASD, atrial septal defect; TTE, transthoracic echocardiogram.

## Technique

The procedure was performed under general anesthesia and monitored by means of transesophageal echocardiography (TEE). All patients were premedicated with low-molecular-weight heparin and acetylsalicylic acid (150 mg). After basal hemodynamic determinations were carried out and after assessing the size of the shunt by applying Fick's method, contrast angiographies were performed by injecting contrast medium into the pulmonary artery (in order to assess potential abnormalities in venous drainage) and into the superior right pulmonary vein, with four-chamber views in both cases. In addition, a coronary artery sonogram was performed in patients having a history of chest pain or risk factors for ischemic heart disease. The ASD was measured as follows: maximum estimated diameter as determined by passing contrast medium through the defect; diameter as seen in longitudinal and cross-sectional views on TEE; superior, inferior, and anterior septal rims; and, finally, the maximum diameter after stretching with a balloon catheter as monitored with Doppler echocardiography (so as to confirm total occlusion of the defect with the smallest possible diameter of the balloon; Figure 1). In keeping with these measurements and after deciding

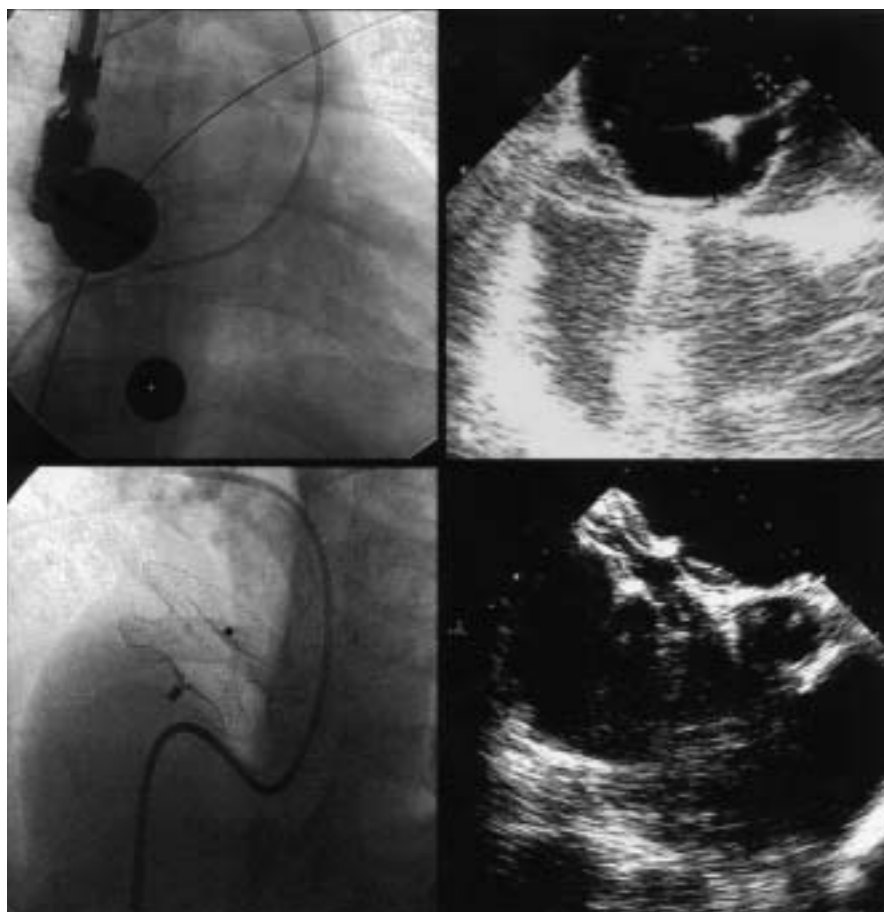
that closure would be attempted, an Amplatzer occluder device was chosen that was slightly larger in diameter (around 2 mm) than the ASD. The technical features of this system have been described previously.<sup>9</sup>

Before the ASO was released, its stability was tested by push-pull maneuvers. Angiography for visualizing restored circulation after injection of the contrast medium in the pulmonary artery and Doppler echocardiography were used to make certain the defect was sealed. During the procedure, operators were shown hemodynamic, radiologic, and echocardiographic images in the same visual field, which made it easier to assess the defect spatially and to monitor its closure at all times.

All patients were treated with low-molecular-weight heparin for one month and with acetylsalicylic acid indefinitely. They were given antibiotic treatment with a second-generation cephalosporin for one week.

## Diagnostic and therapeutic procedures performed simultaneously

In 11 patients systolic arterial pressure in the pulmonary artery was 40 mm Hg or higher (mean,  $64 \pm 16$  mm Hg). Two women in particular had a bidirectional shunt and severe functional deficit (chest pain and



**Fig. 1.** Upper left: radioscopic image of the sizing balloon (37 mm in diameter) with reference sphere. Upper right: image of the balloon closing the defect, as seen on TEE. Bottom: radioscopic and ultrasonic images of the Amplatzer occluder device after implantation.

dyspnea on minimal exertion). After testing for hypoxia and temporarily closing the defect with a balloon catheter, the pulmonary hypertension was shown to be reversible, so a decision was made to perform definitive closure. One female patient in whom closure of the ASD was unsuccessful because the diameter of the defect was too large (38 mm) had previously undergone successful dilatation of supralvalvular pulmonary stenosis. Subsequently, the septal defect was surgically closed. Two other female patients with pulmonary stenosis underwent valvuloplasty followed by closure of the ASD during the same catheterization procedure. Both procedures were successful.<sup>6</sup> A 52-year-old male patient with clinical symptoms of exertional angina was noted to have severe obstructive disease of the anterior descending artery on coronary angiography. Insertion of 3 stents in the involved arterial segments showed excellent results on angiography, and closure of the ASD was then performed. Finally, in one patient who 3 years earlier had undergone surgical repair of Fallot's tetralogy and of an ASD, major dehiscence of the atrial patch was closed by means of an AOD without evidence of residual shunting.

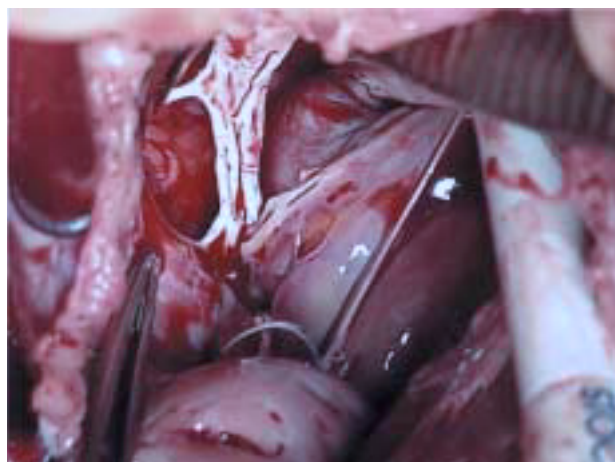
## RESULTS

Table 2 shows the main hemodynamic, angiographic, and echocardiographic findings during the procedure. The maximum diameter of the ASD as determined by balloon angioplasty ranged from 30 to 40 mm (mean, 33.4±3.4), which was significantly greater than the estimated diameter based on angiography. This was, in turn, greater than the diameter measured by means of TEE and TTE. Percutaneous closure could be performed in 23 patients (74%) by using devices with a mean diameter of 34±2.9 mm. In the remaining cases, failure was due to the instability of the system on account of small rims (which led to the decision to

**TABLE 2. Hemodynamic, angiographic, and echocardiographic findings during the procedure**

	Baseline	After closure
Aortic systolic pressure, mm Hg	90.8±16.9	93.2±16.8
Pulmonary systolic pressure, mm Hg	41.4±20.1	40.6±16.3
Qp/Qs	2.1±.8	1.1±.1
Shunt		
Left-right	29 (94%)	
Bidirectional	2 (6%)	
ASD diameter on TEE, mm	26.5±4.2 (16-36)	
ASD diameter on angiography, mm	27.6±5.4 (20-38)	
ASD diameter in stretched position, mm	33.4±3.4 (30-40)	
Upper septal rim, mm	12.2±6	
Lower septal rim, mm	13.8±6	
Anterior septal rim, mm	8.8±5.6	

ASD indicates atrial septal defect; TEE, transesophageal echocardiogram.



**Fig. 2.** Direct view during surgery of one of the atrial septal defects that could not be closed percutaneously.

remove the device rather than free it) or the excessive diameter of the defect as measured with a balloon. All patients underwent programmed surgical closure with good results. Table 3 shows the size of the defect and the date when the procedure was performed in patients whose defect could not be closed. Figure 2 shows the atrial septum as seen during surgery in one such patient. Three patients were shown to have a second atrial opening that had not been picked up by TEE, and it was possible to close both defects simultaneously with the same device. Angiography and Doppler-TEE immediately after the implant showed a small left-to-right shunt measuring approximately 2 mm in diameter in one patient and similar shunts measuring less than 1 mm in another five patients. No residual shunting was noted in the remaining 17 patients.

In one patient who underwent implantation of a device measuring 38 mm in diameter, hemodynamic signs of cardiac tamponade were noted along with pericardial effusion on echocardiography. However, no signs of perforation were seen prior to that. Drainage pericardiocentesis was sufficient for successful resolution of the problem, without the need for further sur-

**TABLE 3. Date of the procedure and ASD diameter in patients Who underwent unsuccessful closure with an Amplatzer occluder device (n=8)**

Patient initials	Date	ASD diameter, mm
MDGD	25/03/1998	40
CLC	20/10/1998	31
EMR	02/02/1999	32
RFA	08/06/1999	36
FPO	21/12/1999	40
SASM	27/06/2000	38
MCP	19/02/2002	39
PRB	04/06/2002	37



gery. No other major or minor complications were noted.

### Follow-up

All patients were discharged from the hospital 48 hours after the procedure with the exception of the patient who developed cardiac tamponade and the two female patients who had bidirectional shunts. After a mean follow-up of  $15\pm 12$  months, no deaths or hospital admissions have occurred among patients who underwent successful closure of the ASD. Follow-up echocardiograms show only minimal shunting through the defect in two patients, and only when color Doppler is employed. All of them remain in sinus rhythm. Patients who reported a history of dyspnea prior to the procedure have experienced clinical and functional improvement. Out of four patients who were in the functional grade III-IV category before treatment, three currently show grade II functional dyspnea when engaged in some form of activity, and one patient with pulmonary hypertension and bidirectional shunting is still in the functional grade II-III category after 6 months of follow-up. The remaining patients are asymptomatic.

### DISCUSSION

According to our findings, percutaneous closure of atrial septal defects having a large diameter with an Amplatzer occluder device can be performed successfully in most cases, with minimal complications and no mortality. This conclusion has already been reached by other authors after studying series of patients whose septal defects had a smaller, though considerable, mean diameter.<sup>4,7,8</sup>

We wish to underline that a large proportion of our patients had other heart conditions, some of which also required combination treatment. Three patients had a double opening. Eleven patients showed significant pulmonary hypertension, and two of them had bidirectional shunting. Three other patients had right ventricular outflow tract obstruction which required dilatation with a balloon catheter. Similarly, one patient with concomitant severe coronary heart disease could be successfully treated with stent implantations, and dehiscence of the atrial patch was closed in the child who had undergone previous surgical repair of Fallot's tetralogy and ASD. The positive results obtained in these complicated situations have been reported previously,<sup>4,6</sup> and this encourages us to try to repair defects which at one time would have been treated in the operating room.

According to a recently-published multicentric study<sup>3</sup> in more than 600 patients having ostium secundum-type ASD in which surgical repair and closure with an Amplatzer occluder device were compared, the percu-

taneous approach had an initial success rate of 96% in the general series, as well as zero mortality and a significantly lower rate of complications than surgical repair. In most cases, failure resulted from an excessively large ASD and from the unavailability of devices large enough in size at the time the repair was attempted. Like the authors who published this study, we feel that some of the patients could have benefited from closure with an Amplatzer occluder device if catheterization had been performed when larger devices became available. In any event, cardiologists will more than likely always have to deal with defects that are anatomically impossible to correct by means of percutaneous methods, and perhaps these are the only cases that should be treated with «open» surgery at the present time, since mean hospital stay and complications appear to be higher than with percutaneous treatment, even though mortality resulting from the surgical procedure is very small.<sup>1,3</sup> In order to draw comparisons, however, follow-up studies are needed similar to those that have been carried out in surgical patients. Potential complications of the procedure include embolism of the device, thrombotic events, involvement of the atrioventricular valves, heart rupture with hemopericardium, conduction defects, and episodes of supraventricular tachycardia.<sup>2,3,7-10</sup> In our series of patients with large ASD we have seen only one case of cardiac tamponade, and it was successfully treated with pericardiocentesis. No embolism of the device was seen in these patients, and closure of the defect did not result in persistent arrhythmia, even under unfavourable conditions. Another issue is how to measure the ASD and study its anatomy with current imaging techniques. It has been clearly established that the estimated diameter of the defect is smaller when determined with an echocardiogram rather than angiography, and that the largest measurement is obtained by means of balloon sizing, which is normally used as reference when choosing the size of the ASD occluder device.<sup>7-11</sup> However, echocardiography is not only useful in estimating the diameter of the opening when stretched open<sup>11</sup>; it also provides information regarding the size of the rims, correct balloon occlusion, and the presence of multiple openings, so that the technique is currently considered essential if good therapeutic results are to be obtained.<sup>10</sup> Thus, combined use of hemodynamic imaging and ultrasound is mandatory.

Admittedly, our results are limited by the small number of patients and short follow-up period. We realize there is more cumulative experience surrounding surgery and that good results are obtained with this technique, which for so many years was the standard approach to the mechanical treatment of ASDs. It is still useful for treating patients who are unlikely candidates for percutaneous closure, whose numbers will hopefully decrease in the future.

## REFERENCES

1. Konstantinides S, Geibel A, Olschewski M, Görndt L, Roskamm H, Spillner G, et al. A comparison of surgical and medical therapy for atrial septal defect in adults. *N Engl J Med* 1995;333:469-73.
2. Rigby M. The era of transcatheter closure of atrial septal defects. *Heart* 1999;81:227-8.
3. Du ZD, Hijazi Z, Kleinman C, Silverman N, Larntz K, for the Amplatzer investigators. Comparison between transcatheter and surgical closure of secundum atrial septal defect in children and adults. *J Am Coll Cardiol* 2002;39:1836-44.
4. Suárez de Lezo J, Medina A, Pan M, Romero M, Segura J, Pavlovic D, et al. Transcatheter occlusion of complex atrial septal defects. *Cathet Cardiovasc Intervent* 2000;51:33-41.
5. Suárez de Lezo J, Medina A, Romero M, Pan M, Segura J, Caballero E, et al. Effectiveness of percutaneous device occlusion for atrial septal defect in adult patients with pulmonary hypertension. *Am Heart J* 2002;144:877-80.
6. Medina A, Suárez de Lezo J, Delgado A, Caballero E, Segura J, Romero M. Combined percutaneous atrial septal defect occlusion and pulmonary balloon valvuloplasty in adult patients. *Tex Heart Inst J* 2000;27:216-7.
7. Losay J, Petit J, Lambert V, Esna G, Berthaux X, Brenot P, et al. Percutaneous closure with Amplatzer device is a safe and efficient alternative to surgery in adults with large atrial septal defects. *Am Heart J* 2001;142:544-8.
8. Berger F, Ewert P, Abdul-Khaliq H, Nurnberg JH, Lange PE. Percutaneous closure of large atrial septal defects with the Amplatzer Septal Occluder: technical overskill or recommendable alternative treatment? *J Interv Cardiol* 2001;14:63-7.
9. Masura J, Gavora P, Formanek A, Hijazi Z. Transcatheter closure of secundum atrial septal defects using the new self-centering amplatzer septal occluder: initial human experience. *Cathet Cardiovasc Diagn* 1997;42:388-93.
10. Fernández A, del Cerro MJ, Rubio D, Castro MC, Moreno F. Cierre percutáneo de la comunicación interauricular mediante dispositivo de Amplatz: resultado inicial y seguimiento a medio plazo. *Rev Esp Cardiol* 2001;54:1190-6.
11. Rao PS, Langhough R. Relationship of echocardiographic, shunt flow, and angiographic size to the stretched diameter of the atrial septal defect. *Am Heart J* 1991;122:505-8.