

IMAGES IN CARDIOLOGY

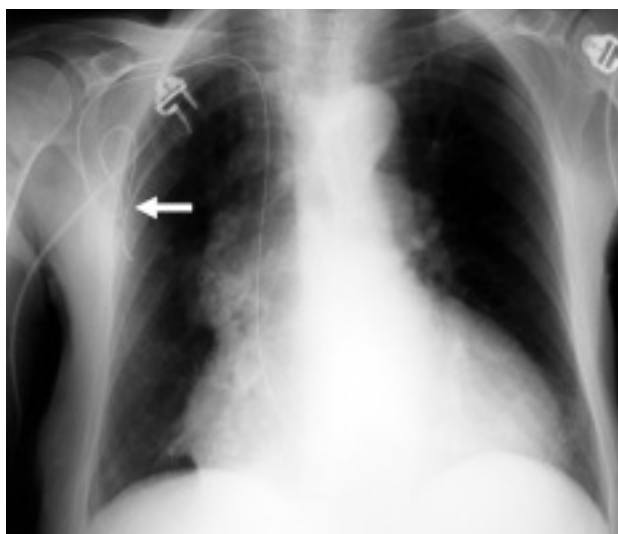


Fig. 1.

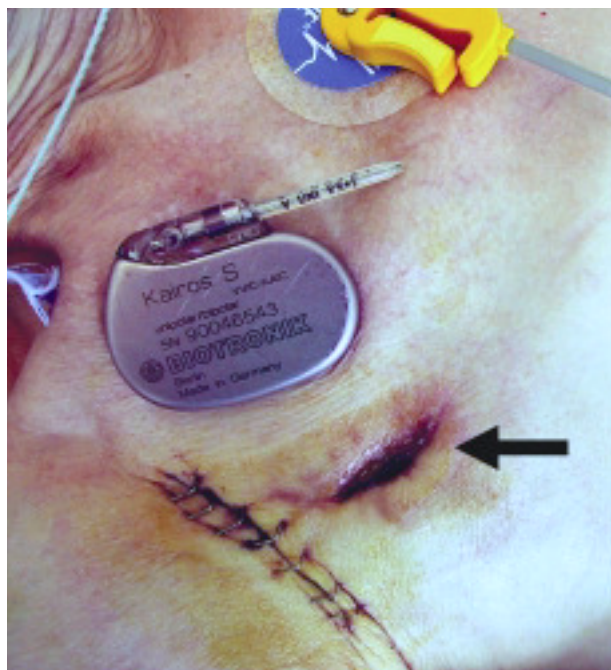


Fig. 2.

Disappearance of Pacemaker Pulse Generator

An 83-year-old woman with a history of VVI pacemaker implantation 10 years earlier due to complete atrioventricular block. Four months previously at another hospital she had undergone elective replacement of the generator as it was worn out, and she was admitted at the present time for syncope. She lived alone and presented with senile dementia and blindness due to glaucoma in the right eye.

On ECG complete atrioventricular block was seen with a ventricular escape rhythm of 35 beats/minute and morphology of an advanced block of the right branch of the bundle of His. Stimulation flutter was not seen.

On physical examination, the generator pocket appeared edematous and swollen, with continuity solution on the skin, but the generator was not located on palpation.

Chest radiography showed the absence of the pacemaker generator and interruption of the electrode. In addition, continuity fluid was seen on the electrode (Figure 1, arrow).

On questioning the patient again, she remembered that she had cut the pacemaker cable and given the generator to the attending cardiologist.

Figure 2 shows the pacemaker generator with intentional cutting of the cable, the partially closed exterior wound (arrow), and the surgical wound, with staples, used for the revision and electrical isolation of the remaining electrode.

Staphylococcus aureus was isolated in a wound culture, and treatment was begun with intravenous vancomycin. We decided to proceed to the isolation of the pacemaker electrode and the implantation of a new stimulation system via dissection of the left cephalic vein.

José Luis Martínez Sande, Antonio Amaro Cendón and José María García Acuña
Servicio de Cardiología y Unidad Coronaria, Hospital Clínico Universitario, Santiago de Compostela, Spain.