

IMAGES IN CARDIOLOGY

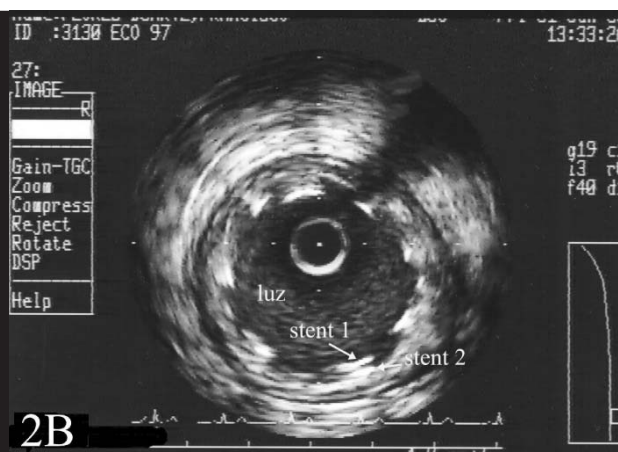
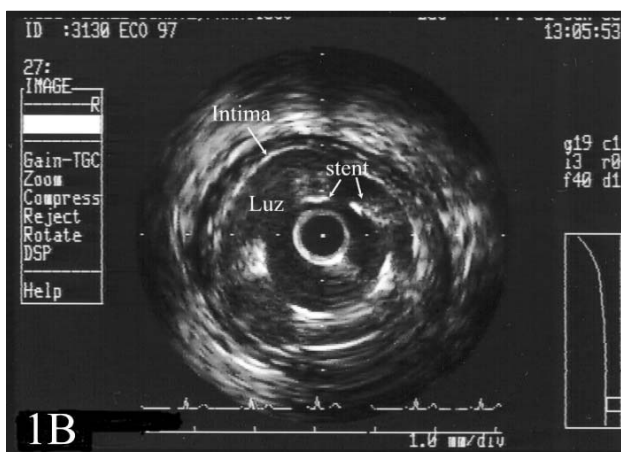
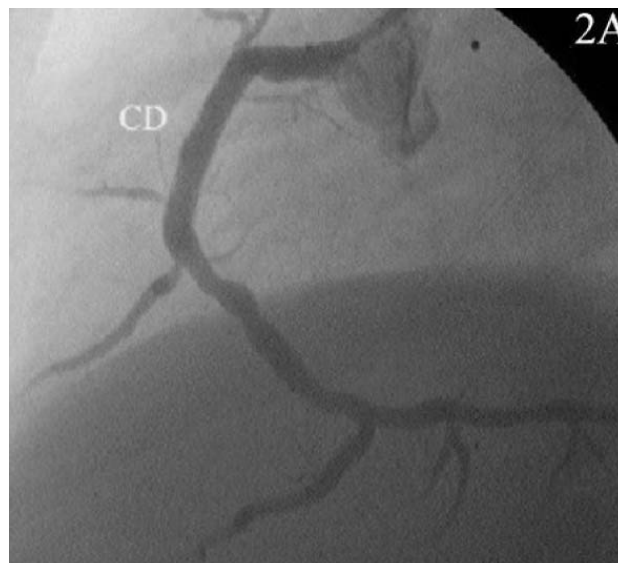
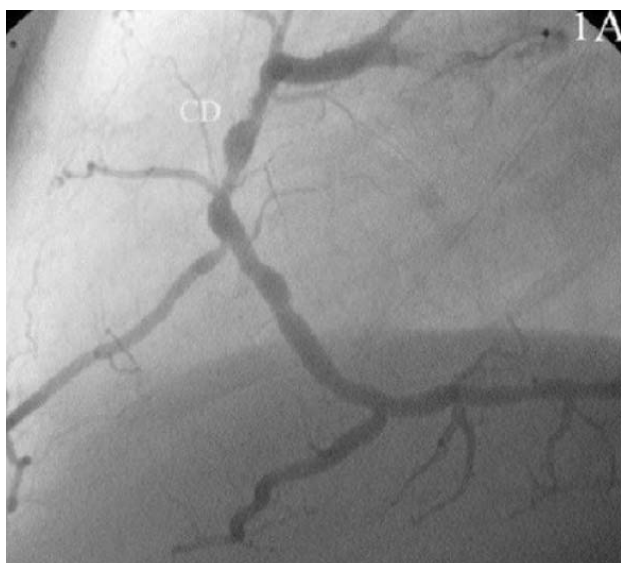
Fig. 1.

Fig. 2.

Stent Pseudo restenosis. Diagnosis Using Intravascular Ultrasound

A 56-year-old ex-smoker with dyslipidemia who had undergone cardiac catheterization in another center three months earlier for acute myocardial infarction (AMI) is presented. At that time stenotic disease was seen in the proximal right coronary artery (RCA) and the distal left anterior descending (LAD)

artery. Angiography was performed and a 2.5 18-mm stent was implanted in the RCA. The patient was again admitted for a new inferior AMI and treated with fibrinolysis. At 72 hours, inferior reinfarction occurred and the patient was again given thrombolytic therapy.

García García C, et al. Stent Pseudorestenosis.

The patient was referred to our hospital where cardiac catheterization showed distal LAD disease, similar to that seen before, and a lesion in the RCA stent (Figure 1A). Moreover, there was an inconclusive image of contrast leakage outside the limits of the stent. Intracoronary ultrasound showed a 2.5-mm permeable stent without intimal proliferation. Nevertheless, failed apposition of the struts to the wall of the vessel, which measured 4 mm in diameter, was evident (Figure 1B). The stent was dilated with a 4 20-mm balloon at high-pressure and a small proximal dissection occurred. A 4 28-mm stent was then implanted, with good angiographic results

(Figure 2A). The final intracoronary ultrasound study demonstrated adequate expansion and apposition of both stents, with a double series of struts in contact with the vessel intima (Figure 2B). Intracoronary ultrasound is a useful technique for coronary stent implantation and for assessing the mechanisms of stent thrombosis.

Cosme García García,
Eduard Fernández Nofrerías,
and Josepa Mauri Ferré
Servicio de Cardiología, Hospital Universitari Germans
Trias i Pujol, Badalona, Barcelona, Spain.