

Aortic Origin of the Left Pulmonary Artery in an Infant With Fallot's Tetralogy

Juan Carretero, Miquel Rissech, Carlos Mortera, Javier Mayol, José Caffarena, and Fredy Prada

Sección de Cardiología Pediátrica, Unidad Integrada, Hospital Sant Joan de Déu-Hospital Clínic, Barcelona, Spain.

We report the case of a male neonate who had a prenatal diagnosis of Fallot's tetralogy. He presented with respiratory distress during the second week of life. Chest x-ray showed an enlarged right ventricle and pulmonary edema. Echocardiography demonstrated characteristic features of Fallot's tetralogy. However, cardiac catheterization disclosed that, in this case of Fallot's tetralogy, the left pulmonary artery had an anomalous origin in the ascending aorta. At 23 days of age, the patient underwent total surgical correction of the defects, during which a direct anastomosis was employed without conduit placement. 10 days later, he was discharged. We present the results of a literature review of the epidemiological, physiopathological, clinical, diagnostic, and surgical characteristics of this rare condition.

Key words: *Cardiac surgery. Fallot's tetralogy. Congenital heart defect.*

Origen aórtico de arteria pulmonar izquierda en neonato con tetralogía de Fallot

Presentamos el caso de un neonato con diagnóstico prenatal de tetralogía de Fallot. Durante la segunda semana de vida presentó dificultad respiratoria; en la radiografía de tórax se observó un aumento del ventrículo derecho con edema pulmonar. La ecocardiografía mostró los hallazgos de la tetralogía de Fallot. En el cateterismo cardíaco se encontró además un origen anómalo de la arteria pulmonar izquierda desde la aorta ascendente. A los 23 días se realizó cirugía correctora con anastomosis directa sin utilizar interposición de conducto. Fue dado de alta hospitalaria 10 días después. Revisamos la literatura médica de esta rara entidad, en sus hallazgos epidemiológicos, fisiopatológicos, clínicos, diagnósticos y quirúrgicos.

Palabras clave: *Cirugía cardíaca. Tetralogía de Fallot. Defectos cardíacos congénitos.*

INTRODUCTION

Anomalous origin of a pulmonary artery branch from the aorta is a rare congenital heart disease, in which one of the pulmonary branches arises from the ascending aorta. Aortic arch abnormalities include partial or complete failure in the development of the left sixth arch.¹ The condition is included in the group of aortic arch abnormalities and is produced by partial or complete developmental failure of the left sixth arch.¹

This defect should be suspected in newborns with heart failure and increased pulmonary flow. Unless surgically repaired, the condition is fatal in most cases due to irreversible pulmonary hypertension, which can be present at very early ages.^{2,3}

We describe the case of a neonate prenatally diagnosed with Fallot's tetralogy, who presented heart failure. Catheterization disclosed Fallot's tetralogy associated with anomalous origin of a pulmonary artery (PA) branch from the left aorta, from the ascending aorta. Surgical correction of the defect was performed and the postoperative course was favorable.

CASE STUDY

Neonate born at term with a prenatal diagnosis of Fallot's tetralogy. The postnatal echocardiography showed a large subaortic ventricular septal defect, aortic arch 50%, pulmonary artery trunk 8 mm, and pul-

Correspondence: Dr. F. Prada.
Sección de Cardiología Pediátrica. Hospital Sant Joan de Déu.
Passeig de Sant Joan de Déu, 2. 08950 Esplugues. Barcelona. España.
E-mail: fprada@hsjdbcn.org

Received November 12, 2004.
Accepted for publication January 18, 2005.

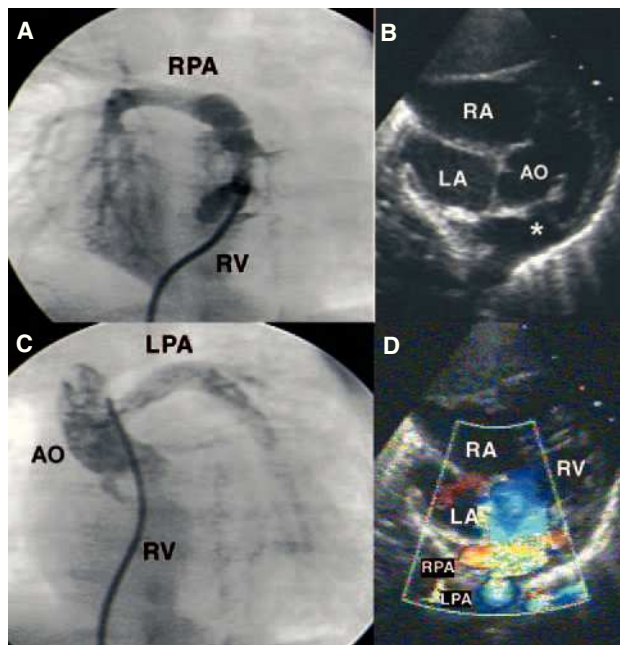


Figure. A: right ventriculography: pulmonary artery (PA) trunk, right PA, and absence of left PA are visualized. **B:** subcostal view: a ventricular septal defect and pulmonary infundibular stenosis can be seen. Note the false image of both branches emerging from the PA trunk (*). **C:** ascending aortography; opacification in the left PA, which originates from the lateral side of the aorta, is observed. **D:** same view with color Doppler. RA indicates right atrium; LA, left atrium; Ao, aorta; RPA, right pulmonary artery; LPA, left pulmonary artery; RV, right ventricle.

monary branches 4 mm. The anomalous origin of one pulmonary artery branch from the aorta (Figure B and D) was not visualized, and there was no pulmonary valvular or subvalvular stenosis. In the second week of life, the infant presented progressively worse tachypnea, tachycardia, hepatomegaly, and grade II/VI systolic murmur in the mesocardium. The chest x-ray showed cardiomegaly, pulmonary edema, and an elevated apex of the heart. Therapy with digitalis drugs and diuretics was initiated, with partial improvement.

Since the clinical symptoms were not consistent with the echocardiographic findings, cardiac catheterization was performed, disclosing good right ventricle (RV) function, an infundibular-valvular gradient of 20 mm Hg, PA trunk with no left PA (Figure A), and pulmonary hypertension due to pulmonary overflow (Q_p/Q_s 2.4) with normal resistances; both ventricles had the same pressures. The aortography disclosed a right aortic arch and origin of the left PA from the posterolateral wall of the ascending aorta (Figure C). Left ventriculography showed a large subaortic ventricular septal defect.

The microdeletion 22q11 study was positive. At 23 days of life, surgical repair was performed, consisting of resection of the left PA and reimplantation on the PA trunk, along with direct closure of the ascending

aorta and subaortic ventricular septal defect with a heterologous pericardium patch. The infundibular muscle and anomalous bands of the RV were resected through an atrial approach. Postoperative echocardiography showed a gradient of 17 mm Hg at the left PA and RV pressures at 40% of systemic pressures. One week later, the patient was discharged.

DISCUSSION

Anomalous origin of a PA branch from the aorta is an extremely rare conotruncal malformation, accounting for only 0.12% of all congenital heart diseases.⁴ In most cases, the anomalous branch originates on the posterolateral wall of the ascending aorta, near the aortic valve.^{5,6} In 15%, the origin is distal, near the base of the innominate artery.⁴ Anomalous origin of the right branch is 5-6 times more frequent than the left.^{4,6,7}

Most articles on anomalous origin of a PA branch from the aorta describe isolated clinical cases except for 2 series,^{6,7} which review 12 and 16 cases, respectively.

This condition can present alone or in association with other congenital heart defects; the most frequent is persistent ductus arteriosus.^{3,4,6} The heart disease most frequently associated with left-sided anomalous origin is Fallot's tetralogy.⁸ Association with microdeletion of chromosome 22q11, as occurred in our patient, has only been described in one case, indicating that this anomaly pertains to the group of conotruncal cardiac malformations caused by anomalous development of the neural crest cells.⁹

Only 9 cases of anomalous origin of the PA from the left aorta associated with Fallot's tetralogy have been reported; the case we describe is the first reported in the Spanish medical literature.

The clinical presentation includes heart failure, heart murmurs, tachypnea, dyspnea, and repeated respiratory distress. Heart failure is the predominant symptom, with this being particularly serious when associated with coarctation or interruption of the aortic arch.¹⁰

Two-dimensional color Doppler echocardiography is used for the initial diagnosis, although up to 15% of cases can go undetected.¹⁰ In our case, we could not detect the anomalous origin, probably because both branches were very close, as observed in Figure (B and D). The Doppler examination may be suggestive of anomalous origin,¹¹ visualizing systodiastolic flow in the left PA, a phenomenon that we probably did not observe due to the elevated pulmonary vascular resistance of the newborn. Cardiac catheterization continues to be the definitive test for diagnosis, along with providing useful information for surgical planning.

Catheterization shows the systemic pulmonary pressures in the 2 arteries. The abnormally connected lung is perfused at a systemic pressure, whereas the other is exposed to the entire cardiac output from the RV. When

the pulmonary resistances drop during the neonate period, the pressure and flow within the anomalous PA increase, causing overcirculation and leading to pulmonary hypertension.¹⁰ The development of pulmonary hypertension in the lung normally irrigated by the pulmonary artery may be due to vasoconstrictive circulating substances or crossed neurogenic factors.^{12,13}

Early surgery within the neonatal period is preferable,¹¹ as it would prevent pulmonary occlusive vascular disease that can develop quickly from age 3 months.^{2,3} The surgery consists of direct anastomosis of the anomalous branch to the pulmonary artery trunk.^{3,11} It may be necessary to expand the operated area with an autologous pericardium patch or interposition of a homograft.¹¹ Techniques that use autologous tissues to widen and lengthen the anomalous origin of a PA branch from the aorta may be associated with a lower incidence of restenosis than direct anastomosis techniques,¹⁴ although the reported series are too small to clearly demonstrate this. At the present time, mortality is virtually nonexistent.

The most frequent postoperative complication is stenosis of the anastomosis (10.6%), which can develop months after surgery.⁷ Patients with severe restenosis may require surgical angioplasty, balloon dilatation or stent placement.⁷

Anomalous origin of a PA branch from the aorta is a rare entity in which prompt diagnosis and surgery are essential to prevent irreversible vascular pulmonary disease. Follow-up to detect restenosis, which is frequent, is important.

REFERENCES

1. Aru GM, English WP, Gaymes CH, Heath BJ. Origin of the left pulmonary artery from the aorta: embryologic considerations. *Ann Thorac Surg.* 2001;71:1008-10.
2. Fontana GP, Spach MS, Effmann EL, Sabiston DC, Jr. Origin of the right pulmonary artery from the ascending aorta. *Ann Surg.* 1987;206:102-13.
3. Kaene JF, Maltz D, Bernhard WF, Corwin RD, Nadas AS. Anomalous origin of one pulmonary artery from ascending aorta. Diagnostic physiological and surgical considerations. *Circulation.* 1974;50:588-94.
4. Kutsche LM, Van Mierop LH. Anomalous origin of a pulmonary artery from the ascending aorta: associated anomalies and pathogenesis. *Am J Cardiol.* 1988;61:850-6.
5. Duncan WI, Freedom RM, Olley PM, Rowe RD. Two dimensional echocardiographic identification of hemitruncus. Anomalous origin of one pulmonary artery from ascending aorta. *Am Heart J.* 1981;102:892-6.
6. Reyes de la Cruz L, Vizcaíno Alarcón A, Arévalo Salas A, Espinosa Islas G, Bolio Cerdan A, Arteaga Martínez M. Diagnóstico ecocardiográfico del origen anómalo de una rama de la arteria pulmonar de la aorta ascendente. *Arch Cardiol Mex.* 2003;73:115-23.
7. Abu-Sulaiman RM, Hashmi A, McCrindle BW, Williams WG, Freedom RM. Anomalous origin of one pulmonary artery from the ascending aorta: 36 years' experience from one centre. *Cardiol Young.* 1998;8:449-54.
8. Prifti E, Bonacchi M, Murzi B, Crucean A, Bernabei M, Luisi VS, et al. Anomalous origin of the left pulmonary artery from the aorta. Our experience and literature review. *Heart Vessels.* 2003;18:79-84.
9. Saliba Z, le Bidois J, Sidi D, Kachener J, Bonnet D. Prenatal detection of a tetralogy of fallot with origin of the left pulmonary artery from the ascending aorta in a familial 22q11 microdeletion. *Prenat Diagn.* 1999;19:260-2.
10. Miyazaki K, Murashita T, Kubota T, Matsuzaki K, Miyazaki YJ, Yasuda K. Neonatal repair of anomalous origin of the right pulmonary artery from the ascending aorta. *J Cardiovasc Surg.* 2000;41:863-8.
11. Rey C, Cloez JL, Francart C, Marcon F, Vaksman G. Abnormal origin of the right pulmonary artery from the ascending aorta. Echocardiographic diagnosis apropos of 2 cases. *Arch Mal Coeur Vaiss.* 1988;81:643-8.
12. Nakamura Y, Yasui H, Kado H, Yonenaga K, ShioKawa Y, Tokunaga S. Anomalous origin of right pulmonary artery from the ascending aorta. *Ann Thorac Surg.* 1991;52:1285-91.
13. Griffiths SP, Levine OR, Anderson DH. Aortic origin of the right pulmonary artery. *Circulation.* 1962;25:73-84.
14. Prifti E, Crucean A, Bonacchi M, Bernabei M, Leacche M, Murzi B, et al. Postoperative outcome in patients with anomalous origin of one pulmonary artery branch from the aorta. *Eur J Cardiothorac Surg.* 2003;24:21-7.