

Abnormal Myocardial Perfusion After Infarction in Patients With Persistent TIMI Grade-3 Flow. Only an Acute Phenomenon?

Vicente Bodí,^a Juan Sanchis,^a Julio Núñez,^a María P. López-Lereu,^b Luis Mainar,^a María J. Bosch,^a Eloy Domínguez,^a Oliver Husser,^a Francisco J. Chorro,^a and Ángel Llacer^a

^aServicio de Cardiología, Hospital Clínico y Universitario de Valencia, Universidad de Valencia, Valencia, Spain

^bERESA, Valencia, Spain

Introduction and objectives. It has been suggested that abnormal perfusion as derived from cardiovascular magnetic resonance imaging (CMR) is a transient dysfunction of microcirculation after myocardial infarction (MI) with TIMI 3 flow. We hypothesized that defects of myocardial perfusion may persist during the following months.

Methods. Forty-seven patients with MI and sustained TIMI 3 flow underwent intracoronary myocardial contrast echocardiography (MCE) 1 week and 6 months after infarction. Abnormal perfusion by MCE was regarded as >1 hypoperfused segment.

Results. At one week, 20 patients showed abnormal perfusion as derived from MCE. At six months 10 patients displayed chronic abnormal perfusion. These patients had greater left ventricular volumes and lower ejection fraction at the sixth month by CMR ($P < .01$).

Conclusions. MCE detects perfusion defects which can persist in chronic phase—this relates to more severe systolic dysfunction and increased left ventricular volumes.

Key words: Magnetic resonance imaging. Myocardial contrast echocardiography. Myocardial infarction. Perfusion. Angioplasty.

SEE EDITORIAL ON PAGES 468-70

INTRODUCTION

The main purpose of treatment for acute myocardial infarction (AMI) is to reestablish tissue perfusion.¹

This study was funded by a grant from Guidant.

Correspondence: Dr. V. Bodí.
Servicio de Cardiología. Hospital Clínico y Universitario de Valencia.
Blasco Ibáñez, 17. 46010 Valencia. España.
E-mail: vicentbodi@hotmail.com

Received July 6, 2006.

Accepted for publication December 12, 2006.

Perfusión miocárdica alterada tras un infarto en pacientes con flujo TIMI 3 mantenido. ¿Sólo un fenómeno agudo?

Introducción y objetivos. Se ha señalado que la perfusión anormal analizada mediante resonancia magnética cardiaca (RMC) es una alteración transitoria de la microcirculación después de un infarto agudo de miocardio (IAM) con flujo TIMI 3. Planteamos la hipótesis de que las alteraciones de la perfusión miocárdica pueden persistir en los meses siguientes.

Métodos. Estudiamos 47 pacientes con un primer IAM y flujo TIMI 3 mantenido mediante ecografía miocárdica con inyección intracoronaria de contraste (EMC) en la primera semana y el sexto mes postinfarto. Se consideró que había perfusión anormal mediante EMC si había más de un segmento hipoperfundido.

Resultados. En la primera semana 20 pacientes mostraron perfusión anormal mediante EMC. En el sexto mes, 10 pacientes presentaron perfusión anormal persistente mediante EMC. Estos pacientes mostraron mayores volúmenes ventriculares y peor fracción de eyección en la fase crónica ($p < 0,01$) mediante RMC.

Conclusiones. Mediante EMC pueden detectarse defectos de la perfusión que pueden persistir en fase crónica y se relacionan con mayor dilatación ventricular y peor función sistólica.

Palabras clave. Resonancia magnética. Ecocardiografía miocárdica de contraste. Infarto de miocardio. Perfusion. Angioplastia.

Even in patients with a patent culprit artery, a microvascular perfusion defect is associated with a poorer prognosis.¹⁻⁵

The extent of the perfusion defect may vary in the months following an AMI.^{5,6} As measured by cardiac magnetic resonance (CMR), the evolution of perfusion is controversial. Several authors have defined abnormal perfusion as a phenomenon that is always transient in patients with TIMI 3 flow, mainly on the basis of analyses of delayed gadolinium enhancement sequences.^{7,8} However, first-pass imaging studies have found that perfusion abnormalities can become chronic.^{9,10} At the threshold of the era of regenerative medicine,¹¹ it is

ABBREVIATIONS

AMI: acute myocardial infarction
 CMR: cardiac magnetic resonance
 MCE: myocardial contrast echocardiography

important to clarify whether or not myocardial perfusion alterations can persist in the chronic phase after an AMI with maintained TIMI 3 flow.

The ideal method to analyze myocardial perfusion is still not clear.¹ Although it is limited by its invasive nature, intracoronary myocardial contrast echocardiography (MCE) allows clear assessment of perfusion and may be a reference technique.^{2,5,12}

In this study, we used MCE to assess the presence of microcirculation alterations in the chronic phase after AMI, as well as its significance in relation to ventricular dilation and systolic function.

METHODS**Study Group**

We prospectively included 67 consecutive patients with a first AMI and ST segment elevation treated with thrombolysis within the first 6 h after onset of pain and who underwent cardiac catheterization (with angioplasty, if necessary) before discharge. The inclusion criteria were: *a*) stable clinical course with no complications in the first 6 months; *b*) single-vessel disease with TIMI 3 flow and residual stenosis <50% in the culprit artery at the end of predischage catheterization and in the sixth month; and *c*) absence of contraindications for CMR. We excluded 20 patients with multivessel disease (10 cases), TIMI flow <3 (2 cases), restenosis (5 cases), claustrophobia (2 cases), and reinfarction (1 case), giving a final study group composed of 47 patients.

The study met the requirements of the Declaration of Helsinki and was approved by the Ethics Committee of our institution. All subjects signed the informed consent to participate.

The patients included in the study group are part of a prospective protocol that assesses various aspects of remodeling, perfusion, and myocardial viability by different invasive and noninvasive techniques.^{5,9,12,13} We recently analyzed the evolution of microcirculation using first-pass gadolinium imaging with CMR in 40 patients from this series.⁹ The 17 patients included in this protocol underwent a preliminary analysis of perfusion evolution with MCE, angiography and CMR.⁵ In this paper, we present a more comprehensive analysis of the evolution of perfusion abnormalities by MCE in a group of 47 patients.

Cardiac Catheterization

Cardiac catheterization was performed 4 (\pm 1) days after the AMI. Salvage angioplasty was done within the first 12 h after thrombolysis in 3 patients for chest pain and persistent ST segment elevation. Catheterization was repeated in these 3 patients before discharge and the perfusion indexes (both TIMI flow and MCE) were determined at that time.

The culprit artery was the anterior descending artery in 29 cases and the right coronary in 18 cases. An intracoronary stent was implanted in 41 patients (87%) with residual stenosis >50%. At completion of predischage catheterization, all patients had TIMI 3 flow and residual stenosis <50%. Cardiac catheterization was repeated at 179 (\pm 8) days after AMI, and TIMI 3 flow and residual stenosis <50% were confirmed in all patients included in the study.

Intracoronary Myocardial Contrast Echocardiography

At the end of cardiac catheterization (both predischage and at six months), MCE was performed according to the previously established protocol in our laboratory.⁵ A 1-mL bolus (concentration, 350 mg/mL) of Levovist (Schering AG, Germany) was injected, followed by 5 mL of saline solution through the catheter that revascularized the culprit artery for the parasternal and apical views. Successive 1-mL contrast boluses were administered if necessary. There were no adverse effects in more than 100 studies. The images were recorded in real time using second harmonic technology with a VingMed 750 echocardiograph (General Electric, USA); gain and compression were optimized in each case and did not vary during the studies.

Analysis of Intracoronary Myocardial Contrast Echocardiography

The images were digitized and analyzed on separate days by an experienced observer who was unaware of the results obtained in the other examinations. Images were taken with maximum contrast intensity in end-systole, and the area at risk was defined as the region including segments dependent on the culprit artery in the 17-segment model.¹⁴ Quantitation of perfusion was done using MATLAB 6.5 (The Mathworks Inc., USA).¹² A region of interest was defined in each field; the baseline intensity (video intensity units) was subtracted and standardized by the intensity of the segment that showed normal contractility and maximum intensity (video intensity units), yielding in all cases a standardized perfusion range of 0 to 1. Based on our experience, we defined abnormal perfusion to exist in a segment if its standardized range was <0.75.¹² A patient was considered to have poor

perfusion in the infarct area if more than one segment showed abnormal perfusion.

The intraobserver variability with regard to presence or absence of normal perfusion was analyzed in 15 patients; these studies were assessed twice at least 3 months apart by the observer who quantitated all the data. When using the methodology described, the variability was 0%.

Cardiac Magnetic Resonance

Cardiac magnetic resonance (1.5-Tesla, Sonata Magnetom, Siemens, Germany) was performed 7 (± 1) days (at least 48 h after catheterization) and 184 (± 11) days after the AMI, following the protocol of our laboratory.^{9,13} Electrocardiogram-gated images were recorded during breath-holding. The cine-MRI images (true fast imaging with steady state precession sequences, repetition time/echo time: 3.2/1.6 ms^o angle, 61^o; matrix; 256 \times 128; slice thickness, 6 mm) were acquired in 2-, 3-, and 4-chamber views and every 1 cm in the short-axis views.

Following administration of 0.1 mmol/kg of gadolinium-diethylenetriaminepentaacetic acid contrast (Magnograf, Juste SAQF, Spain) at a flow rate of 3 mL/s, the delayed gadolinium enhancement images were taken 10 min after contrast injection using a true fast imaging with steady state precession (repetition time/echo time: 2.5/1.1 ms; slice thickness, 6 mm; angle, 50^o; matrix, 195 \times 192), canceling the myocardial signal.

Cardiac Magnetic Resonance Analysis

The studies were analyzed by an experienced observer using QMASS MR 6.1.5 (Medis, The Netherlands). The end-diastolic and end-systolic volumes (mL/m²), ventricular mass (g/m²), and ejection fraction (%) were quantitated by planimetry of the cine images.

In the delayed uptake images, late enhancement was considered to exist if the signal intensity was >2 standard deviations with respect to a remote, noninfarcted area⁹; the percentage of ventricular mass was calculated with delayed enhancement (percentage of infarction/infarcted mass). All indices were reevaluated at six months.

Intraobserver variability was analyzed in 15 patients; the CMR studies were assessed twice by the observer, who quantitated all the data at least 3 months apart. The intraobserver variability was 4.1 mL/m² (± 2.9) mL/m² for end-diastolic volume, 2 mL/m² (± 1.4) mL/m² for end-systolic volume, and 2.4% (± 2.4 %) for ejection fraction.

Statistical Analysis

Continuous variables are expressed as mean (\pm standard deviation) and qualitative variables, as percentages. For

the continuous variables, the 2 groups were compared by Student *t*-test for paired and unpaired data. Comparisons between more than 2 groups were done using analysis of variance (with the Bonferroni test to analyze the differences between subgroups). The χ^2 test was used to compare percentages. A *P* value less than $<.05$ was considered statistically significant. SPSS 11.0 (SPSS Inc., USA) was used for the statistical analysis.

RESULTS

The baseline characteristics of the 47 patients are shown in Table 1.

Abnormal Perfusion on Intracoronary Myocardial Contrast Echocardiography

Abnormal perfusion was detected by MCE in 20 patients (43%) at one week and 10 (21%) at six months. Abnormal perfusion was related to higher ventricular volumes, more severely depressed ejection fraction, and higher percentage of infarct mass, both at one week and at six months. Only 1 case of abnormal perfusion at six months was associated with a larger ventricular mass in the chronic phase (Tables 2 and 3).

TABLE 1. Characteristics of Study Group*

Age, years	57 (± 10)
Men	42 (89%)
Hypertension	18 (38%)
Smokers	35 (74%)
Diabetes	5 (11%)
Hypercholesterolemia	20 (43%)
Killip class >1	7 (15%)
Anterior infarction	29 (62%)
Inferior infarction	18 (38%)
Catheterization	
Stent	41 (87%)
GP IIb/IIIa inhibitors	20 (43%)
Intracoronary myocardial contrast echocardiography	
Number of segments per patient with:	
Abnormal perfusion, week 1	2 (± 2.6)
Abnormal perfusion, month 6	0.8 (± 1.8)
Cardiac magnetic resonance	
End-diastolic volume, week 1, mL/m ²	70 (± 21)
End-systolic volume, week 1, mL/m ²	35 (± 19)
Ejection fraction, week 1, %	52 (± 12)
Ventricular mass, week 1, g/m ²	80 (± 16)
Infarction mass, week 1, %	31 (± 16)
End-diastolic volume, month 6, mL/m ²	69 (± 24)
End-systolic volume, month 6, mL/m ²	32 (± 22)
Ejection fraction, month 6, %	56 (± 13)
Ventricular mass, month 6, g/m ²	79 (± 18)
Infarct mass, month 6, %	33 (± 14)

*GP indicates glycoprotein; HT, hypertension. The data are presented as the mean (\pm standard deviation) or as n (%).

TABLE 2. Clinical and Left Ventricular Data Based on the Presence of Abnormal Perfusion at One Week With Intracoronary Myocardial Contrast Echocardiography*

	Normal Perfusion (n=27)	Abnormal Perfusion (n=20)	P
Age, years	59 (±9)	55 (±12)	.2
Men	24 (89%)	18 (90%)	.9
Hypertension	9 (34%)	9 (45%)	.2
Smoker	19 (70%)	16 (80%)	.4
Diabetes	4 (15%)	1 (5%)	.4
Hypercholesterolemia	13 (48%)	7 (35%)	.5
Killip class	1.1 (±0.2)	1.2 (±0.4)	.5
Anterior infarction	16 (59%)	13 (65%)	.9
GP IIb/IIIa inhibitors	12 (45%)	8 (40%)	.8
End-diastolic volume, week 1, mL/m ²	65 (±14)	78 (±26)	.04
End-systolic volume, week 1, mL/m ²	27 (±9)	46 (±24)	.002
Ejection fraction, week 1, %	59 (±9)	43 (±11)	<.0001
Ventricular mass, week 1, g/m ²	78 (±14)	82 (±19)	.4
Infarct mass, week 1, %	25 (±12)	39 (±17)	.002
End-diastolic volume, month 6, mL/m ²	64 (±17)	77 (±32)	.05
End-systolic volume, month 6, mL/m ²	24 (±6)	44 (±30)	.008
Ejection fraction, month 6, %	63 (±6)	46 (±13)	<.0001
Ventricular mass, month 6, g/m ²	78 (±18)	80 (±19)	.6
Infarct mass, month 6, %	26 (±12)	43 (±13)	<.0001
Number of segments per patient with abnormal perfusion, week 1	0.2± (0.4)	4.4± (2.3)	<.0001

*GP indicates glycoprotein; HT, hypertension. The data are presented as the mean (± standard deviation) or as n (%).

Regarding the evolution of the end-diastolic volume from one week to the six months, no significant increases were detected in the overall study group (70 [±21] vs 69 [±24] mL/m²; *P*=.9) or in patients with normal (65 [±14] vs 64 [±17] mL/m²; *P*=.8) or abnormal perfusion (78 [±26] vs 77 [±32] mL/m²; *P*=.9) at one week. Following a separate analysis of the 20 patients with abnormal perfusion in the first week, those in whom perfusion was normal at the six months (n=10) showed a trend toward decreases in the end-diastolic volume (69 [±15] vs 64 [±12] mL/m²; *P*=.2), whereas those who presented chronic abnormal perfusion showed a trend toward increased end-diastolic volume (82 [±33] vs 91 [±41] mL/m²; *P*=.1).

TABLE 3. Clinical and Left Ventricular Data Based on the Presence of Abnormal Perfusion at Six Months With Intracoronary Myocardial Contrast Echocardiography*

	Normal Perfusion (n=37)	Abnormal Perfusion (n=10)	P
Age, years	59 (±10)	55 (±10)	.2
Male	33 (89%)	9 (90%)	.9
Hypertension	12 (33%)	6 (60%)	.2
Diabetes	5 (12%)	0 (0%)	.6
Hypercholesterolemia	18 (49%)	2 (20%)	.2
Killip class	1 (±0.2)	1.2 (±0.4)	.5
Anterior infarction	20 (54%)	9 (90%)	.07
GP IIb/IIIa inhibitors	15 (40%)	5 (50%)	.7
End-diastolic volume, month 6, mL/m ²	64 (±12)	91 (±41)	.001
End-systolic volume, month 6, mL/m ²	26 (±8)	56 (±38)	<.0001
Ejection fraction, month 6, %	60 (±10)	42 (±14)	<.0001
Ventricular mass, month 6, g/m ²	75 (±16)	91 (±19)	.01
Infarct mass, month 6, %	29 (±13)	45 (±12)	.001
Number of segments per patient with abnormal perfusion, month 6	0± (0.2)	3.9 (±2)	<.0001

*GP indicates glycoprotein; HT, hypertension. The data are presented as the mean (± standard deviation) or as n (%).

Evolution of Perfusion From One Week to Six Months

The number of segments per patient with abnormal perfusion as determined by MCE decreased from one week to six months (2 [±2.6] vs 0.8 [±1.8] segments; *P*<.0001).

The 27 patients with normal perfusion on MCE in the one week maintained this condition in six months. Among the 20 patients with abnormal perfusion at one week, 10 (50%) achieved normal perfusion in the six months, whereas poor perfusion became chronic in 10 patients (21% of the entire group) (Figures 1 and 2).

Patients with chronic abnormal perfusion exhibited larger ventricular volumes and masses and a more severely depressed ejection fraction at 6 months than the other 2 subgroups. Furthermore, they presented a greater percentage of infarct mass than patients with normal perfusion from the start, but no differences with respect to the subgroup with late normalization of perfusion (Figure 3).

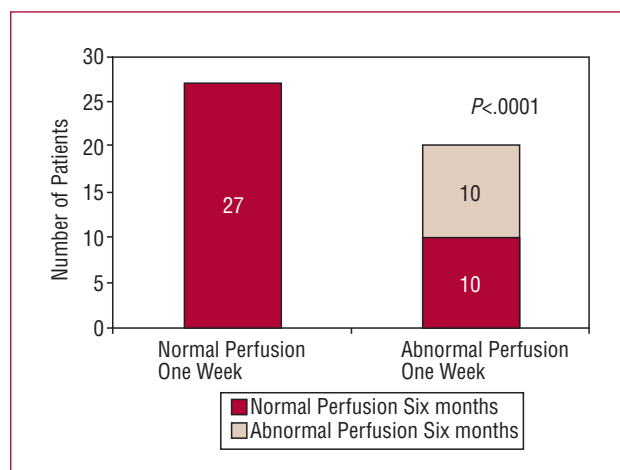


Figure 1. Evolution of perfusion on intracoronary myocardial contrast echocardiography. All patients with normal perfusion at one week maintained this condition at six months. Abnormal perfusion persisted in at six months in 10 of the 20 patients who had abnormal perfusion at one week.

DISCUSSION

In a group of patients with a first AMI, single-vessel disease, and maintained TIMI 3 flow, MCE showed that perfusion alterations can persist during the chronic phase and are related with poorer ventricular function parameters.

Evolution of Perfusion on Cardiac Magnetic Resonance

Analysis of the evolution of perfusion abnormalities as measured by CMR has provided uneven results. Wu et al⁸ and Hombach et al⁷ observed acute phase perfusion defects in 25% and 46% of their patients, respectively. In both studies, the abnormalities disappeared in the chronic phase in all cases.

This transient alteration is apparently more common in studies that assess microcirculation on delayed enhancement images (contrast defects surrounded by necrotic tissue with late enhancement). Studies analyzing perfusion on first-pass gadolinium images have indicated that microcirculation alterations can become chronic in some cases. Taylor et al¹⁰ observed this phenomenon in a group of 16 patients.

In 40 patients in the study group of the present series, we recently observed that chronic perfusion abnormalities can affect up to 14% of segments in the infarct region in the postinfarction chronic phase by an analysis of first-pass gadolinium images.⁹

At the threshold of the era of regenerative medicine,^{11,15} this concept requires clarification. Patients with poor microvascular perfusion have a poorer prognosis,¹⁻⁵ and the possibility of chronic microcirculation defects should

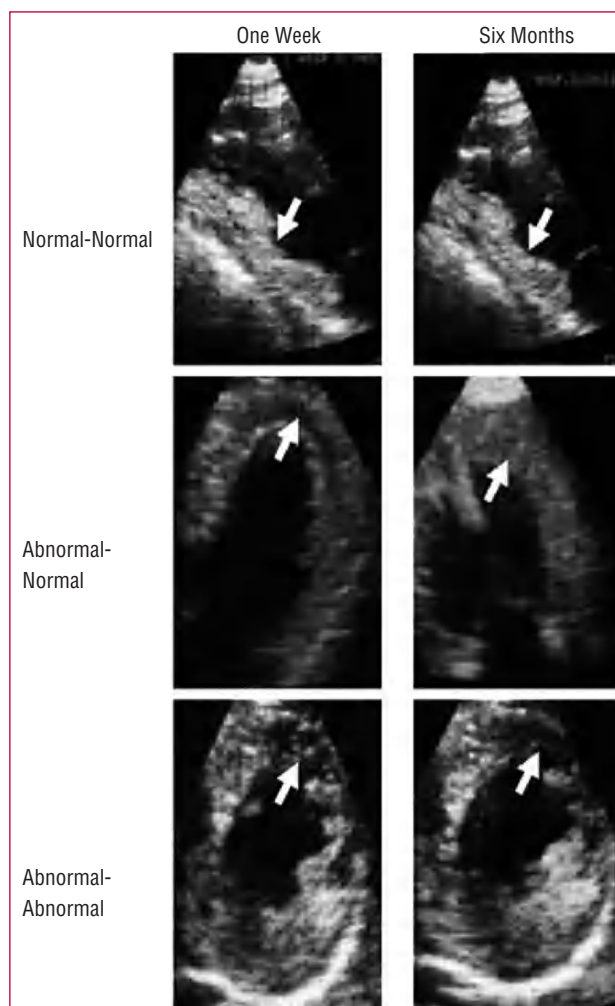


Figure 2. Intracoronary myocardial contrast echocardiography. Top: a patient with an inferior infarction and normal perfusion in the infarct area (arrows), both at one week (left) and the six months (right). Middle: a patient with an anterior infarction and abnormal perfusion in the infarct area (arrows) at one week (left) and normal perfusion in the six months (right). Bottom: a patient with an anterior infarction and abnormal perfusion in the infarct area (arrows) at both one week (left) and the sixth month (right).

not be ruled out, since these cases could be candidates for regenerative medicine in the future.

Abnormal Perfusion on Intracoronary Myocardial Contrast Echocardiography

The kinetics of gadolinium must be taken into account when analyzing the evolution of perfusion abnormalities with CMR¹⁶: it is an extracellular agent with a high capacity for diffusion in the interstitial space. Failure of gadolinium to fill the interstitium in the acute phase could be due not only to microvascular damage, but also to massive interstitial edema in extensive infarctions that

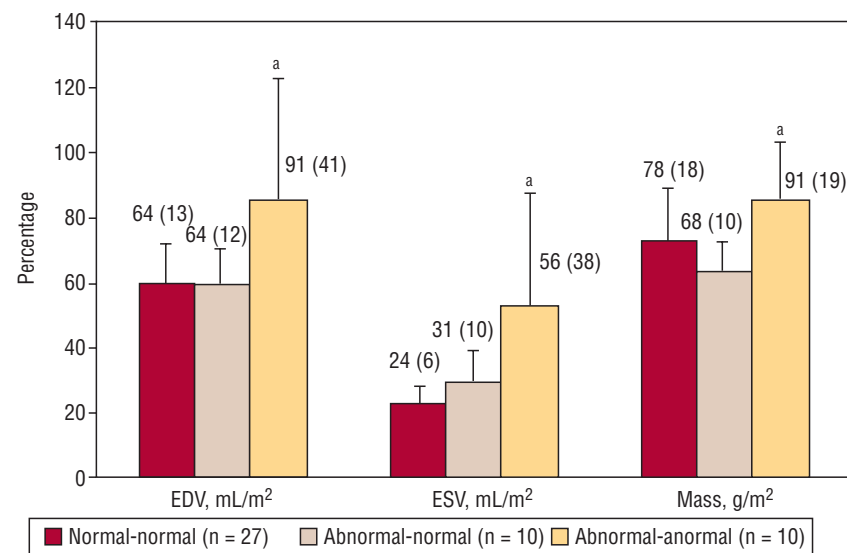
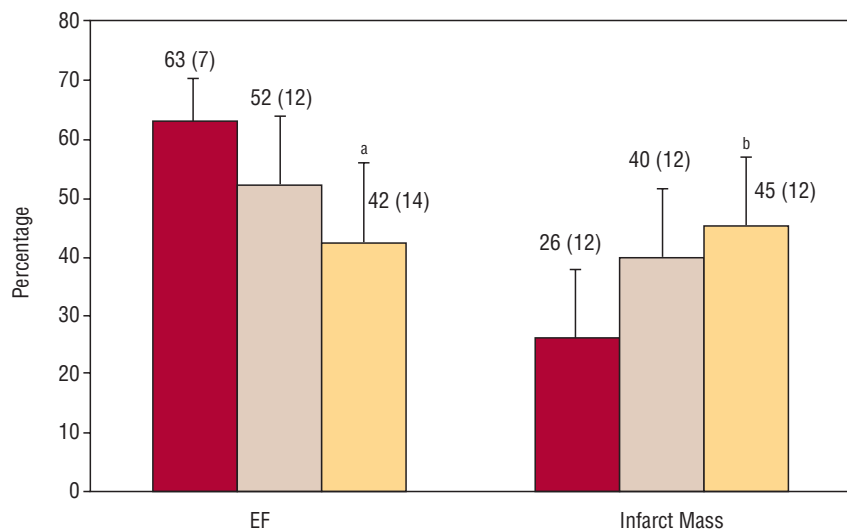


Figure 3. Based on the evolution of perfusion on myocardial contrast echocardiography from one week to six months, the patients were divided into 3 groups: normal-normal (n=27), abnormal-normal (n=10), and abnormal-abnormal (n=10). Patients with sustained abnormal perfusion showed a more severely depressed ejection fraction, greater percentage of infarct mass (top), and larger ventricular volumes and mass (bottom) in the chronic phase. EDV indicates, end-diastolic volume; EF, indicates ejection fraction; ESV, end-systolic volume. ^aP<.01 for abnormal-abnormal vs the other 2 groups. ^bP<.01 for abnormal-abnormal vs normal-normal; P=nonsignificant for abnormal-abnormal vs abnormal-normal.

could impede the entry of gadolinium. Once the inflammatory response disappears, the contrast again occupies the interstitium, which would explain the disappearance of microvascular alteration in all cases in the chronic phase.

In view of these uncertainties, we decided to assess microcirculation using an alternative method. Because of the purely intravascular character of echocardiography contrast, MCE allows direct assessment of coronary microcirculation rather than interstitium. The contrast was injected directly into the coronary artery and reached the small vessels.^{2,5,12} The large number of bubbles allows excellent definition of the perfusion (Figure 2).

This methodology was able to confirm the trend toward spontaneous improvement of microcirculation observed with different techniques.⁶⁻⁸ Half the patients with abnormal perfusion on MCE study achieved normal

perfusion in the chronic phase. The most interesting finding was that MCE allowed detection of a subgroup (21% of the total) in which abnormal perfusion became a chronic phenomenon.

A persistent perfusion abnormality was associated with more highly depressed systolic function and greater dilation of ventricular volumes in comparison with normal perfusion, whether from the first week or for late normalization. In fact, the ventricular mass was only larger in cases of chronic perfusion alteration. As expected, the percentage of infarct mass was only lower in the subgroup with normal perfusion from the start. Lastly, the only subgroup that showed a trend (nonsignificant, probably because of the small number of patients, n=10) toward progressive ventricular enlargement were those with a chronic perfusion abnormality. These data indicate that abnormal perfusion in the chronic phase is not merely

an incidental finding, but has important consequences for ventricular function.

Limitations

For the purpose of carrying out a careful assessment of the objectives (basically pathophysiological), we enrolled a carefully selected group of patients. Therefore, the results are only applicable to series similar to the one presented. We used intracoronary MCE which is an invasive procedure; however, intravenous injection has shown similar results.¹² In our experience, MCE with intracoronary injection allows a more adequate analysis of perfusion and therefore, we chose this method to ensure the objectives set out. The MCE studies had to be done upon completion of catheterization; this could correlate to a higher percentage of cases with abnormal perfusion in comparison with later analyses.

CONCLUSIONS

Most patients with sustained TIMI 3 flow present normal myocardial perfusion, whether from the acute phase or by late spontaneous normalization with no need for further interventions. In a small group of patients, abnormal perfusion persists despite a patent artery. These patients show greater deterioration of left ventricular function and in the future, could be candidates for regenerative medicine.

REFERENCES

1. Braunwald E. Reperfusion therapy for acute myocardial infarction: historical context and future promise. *Eur Heart J*. 2002; 4:E10-4.
2. Ito H, Tomooka T, Sakai N, Yu H, Higashino Y, Fujii K, et al. Lack of myocardial perfusion immediately after successful thrombolysis. A predictor of poor recovery of left ventricular function in anterior myocardial infarction. *Circulation*. 1992;85:1699-705.
3. Haager PK, Christott P, Lepper W, Hanrath P, Hoffmann R. Prediction of clinical outcome after mechanical revascularization in acute myocardial infarction by markers of myocardial reperfusion. *J Am Coll Cardiol*. 2003;41:532-8.
4. Wu KC, Zerhouni EA, Judd RM, Lugo-Olivieri CH, Barouch LA, Schulman SP, et al. Prognostic significance of microvascular obstruction by magnetic resonance imaging in patients with acute myocardial infarction. *Circulation*. 1998;97:765-72.
5. Bodí V, Sanchis J, López-Lereu MP, Llácer A, Pellicer M, Losada A, et al. Estudio de la perfusión en pacientes post-infarto mediante ecografía miocárdica con inyección intracoronaria de contraste. Implicaciones y relación con la angiografía y la resonancia magnética. *Rev Esp Cardiol*. 2004;57:20-8.
6. Ito H, Iwakura K, Oh H. Temporal changes in myocardial perfusion patterns in patients with reperfused anterior wall myocardial infarction. Their relation to myocardial viability. *Circulation*. 1995;91:656-62.
7. Hombach V, Grebe O, Merkle N, Waldenmaier S, Höher S, Kochs S, et al. Sequelae of acute myocardial infarction regarding cardiac structure and function and their prognostic significance as assessed by magnetic resonance imaging. *Eur Heart J*. 2005;26:549-57.
8. Wu KC, Kim RJ, Bluemke DA, Rochitte CE, Zerhouni EA, Becker LC, et al. Quantification and time course of microvascular obstruction by contrast-enhanced echocardiography and magnetic resonance imaging following acute myocardial infarction and reperfusion. *J Am Coll Cardiol*. 1998;32:1756-64.
9. Bodí V, Sanchis J, López-Lereu MP, Núñez J, Sanz R, Palau P, et al. Microvascular perfusion one week and six months after myocardial infarction by first-pass perfusion imaging CMR. *Heart*. 2006;92:1801-7. Disponible en: 10.1136/hrt.2005.077305
10. Taylor AJ, Al-Saadi N, Abdel-Aty H, Schulz-Menger J, Messroghli DR, Friedrich MG. Detection of acutely impaired microvascular reperfusion after infarct angioplasty with magnetic resonance imaging. *Circulation*. 2004;109:2080-5.
11. Bolli R, Jneid H, Dawn B. Bone marrow cell-mediated cardiac regeneration. A veritable revolution. *J Am Coll Cardiol*. 2005; 46:1659-61.
12. Bodí V, Sanchis J, Losada A, García D, Pellicer M, Millet J, et al. Estudio de la perfusión coronaria post-infarto mediante análisis cuantitativo de la ecocardiografía miocárdica con inyección intravenosa de contraste. *Rev Esp Cardiol*. 2005;58: 137-44.
13. Bodí V, Sanchis J, López-Lereu MP, Losada A, Núñez J, Pellicer M, et al. Usefulness of a comprehensive cardiovascular magnetic resonance imaging assessment for predicting recovery of left ventricular wall motion in the setting of myocardial stunning. *J Am Coll Cardiol*. 2005;46:1747-52.
14. Cerqueira MD, Weissman NJ, Dilsizian V, Jacobs AK, Kaul S, Laskey WK, et al. Standardized myocardial segmentation and nomenclature for tomographic imaging of the heart. *Circulation*. 2002;105:539-42.
15. Vatner SF. FGF induces hypertrophy and angiogenesis in hibernating myocardium. *Circ Res*. 2005;96:705-7.
16. Thomson LE, Kim RJ, Judd RM. Magnetic resonance imaging for the assessment of myocardial viability. *J Magn Reson Imaging*. 2004;19:771-88.