

## Coronary Artery Dissection Assessed by Optical Coherence Tomography

### To the Editor:

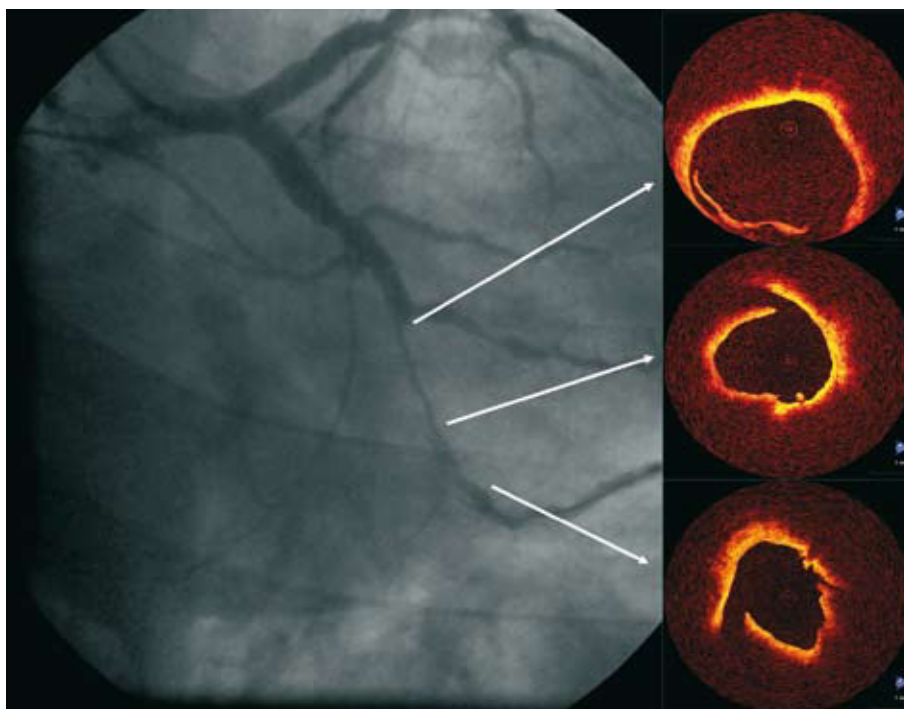
Optical coherence tomography (OCT) is a recently introduced intracoronary diagnostic technique, based on the capturing of images through the analysis of the variation in the reflection of a near-infrared light beam, according to the characteristics of the vascular tissue on which it falls and its subsequent computerised reconstruction. It obtains images with a resolution of 10-20  $\mu\text{m}$ , much superior to that of intracoronary ultrasounds (100-120  $\mu\text{m}$ ). Its incipient introduction in the haemodynamics services allows for comprehensive diagnosis of the different diseases that affect the vascular tree structure. It is currently employed in the evaluation of results after percutaneous coronary intervention,<sup>1</sup> the follow-up of neointimal proliferation in the stents<sup>2</sup> and the characterisation of the vulnerable plaque.<sup>3</sup>

We present the case of a 41-year-old male, hypertensive, smoker, and hypercholesterolemic that was referred to our department with the diagnosis of inferolateral acute myocardial infarction evolving 48 hours after the symptoms started. A diagnostic catheterisation was performed, showing heart disease with complete occlusion

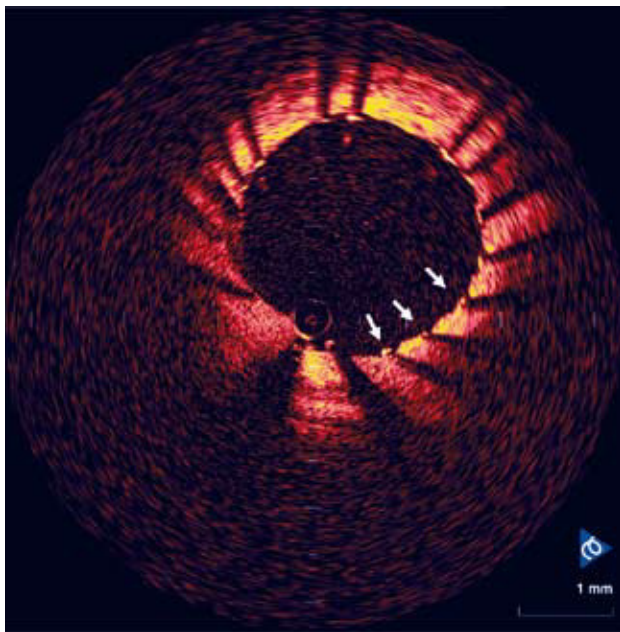
of the distal circumflex artery, severe stenosis of the first marginal artery and slightly reduced left ventricular ejection fraction. A percutaneous coronary intervention was also performed during the procedure. After the deobstruction and first dilation with balloon of the distal circumflex, the patient began to feel chest pain and an angiograph showed a dissection image. After recovering good coronary flow, a study of the vessel with OCT was carried out using the technique described as proximal coaxial balloon occlusion and manual cleansing with saline serum of the lumen, automatic removal of the probe, at a speed of 1 mm/s. An intimal flap image was viewed in the dilated vessel (Figure 1). Subsequently, it was treated through the implantation of conventional stents in the distal circumflex artery and the second marginal artery, with an optimum angiographic result re-evaluated through OCT (Figure 2). The acquisition of the images assumed a total delay of less than 10 minutes.

This is the first documented case in which a high resolution image is obtained of a wide coronary dissection before treating it, prior documentation centred on the microdissections produced by the free edge of the stent after its implantation.<sup>4</sup>

Although the OCT did not influence the decision-making when dissecting, it did allow for an evaluation of the final result, as well as characterisation of the coronary dissection anatomy to perfection. It is therefore a very illustrative



**Figure 1.** Correlation between angiography and slices obtained via optical coherence tomography, showing the progression of the dissection through the artery length.



**Figure 2.** Study of the treated segment. The arrows show the correct apposition of the stent strut in the vessel.

example of the new possibilities available with OCT in the field of intravascular analysis.

Hipólito Gutiérrez García, Ernesto del Amo Hernández, Roman Joseph Arnold, and José Alberto San Román  
ICICORELAB, Unidad de Imagen Cardíaca, Servicio de Cardiología,  
Hospital Universitario de Valladolid, Valladolid, Spain

#### BIBLIOGRAFÍA

1. Gutiérrez H, Arnold R, Gimeno F, Ramos B, López J, Amo E. Tomografía de coherencia óptica. Experiencia inicial en pacientes sometidos a intervencionismo coronario percutáneo. *Rev Esp Cardiol.* 2008;61:976-9.
2. Gerckens U, Lim VY, Grube E. Tomografía de coherencia óptica en la evaluación de las endoprótesis coronarias con capacidad de liberación de fármacos. *Rev Esp Cardiol.* 2005;58:1469.
3. Jang IK, Tearney GJ, MacNeill B, Takano M, Moselewski F, Iftima N, et al. In vivo characterization of coronary atherosclerotic plaque by use of optical coherence tomography. *Circulation.* 2005;111:1551-5.
4. Garg S, Bourantas C, Thackray S. Suspected coronary artery dissection post-stenting, confirmed by optical coherence tomography. *Heart.* 2008;94:335.