

## Endovascular Repair of Symptomatic Penetrating Atherosclerotic Aortic Ulcers

### To the Editor:

We present the case of a male patient aged 74 years, who came to our hospital's emergency room due to presenting intense central chest pain while exercising, which then descended caudally. He was a former smoker who had quit 5 years earlier, and had no other cardiovascular risk factors.

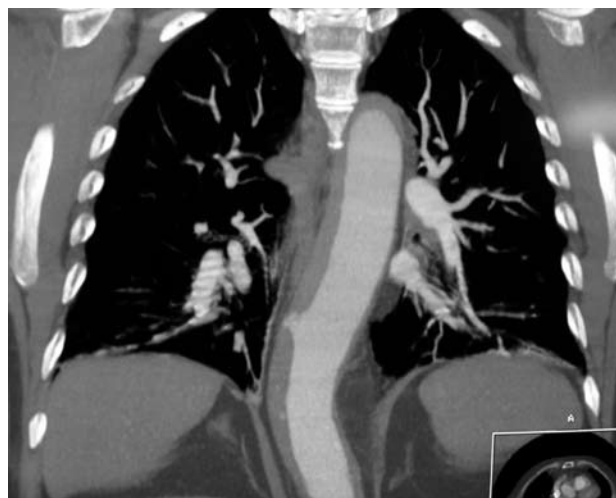As pulmonary thromboembolism was initially suspected, we performed a thoracic computerised tomography (CT) angiography which ruled out pulmonary thromboembolism; however, there were findings compatible with a penetrating atherosclerotic ulcer in the descending thoracic aorta at D9 level with an intramural haematoma extending throughout the entire descending aorta. When this diagnosis was made, our division was contacted and the patient was accepted for correction of the condition (Figure 1).

Under general anaesthesia and with a drain for cephalorachidian liquid in place, a Gore TAG 35/15 aortic endoprosthesis was implanted through the right femoral artery, with a good radiological result. Subsequent progress in the ICU was very good, with a certain tendency toward arterial hypertension which was resolved with a solinitrine (nitroglycerin) perfusion.

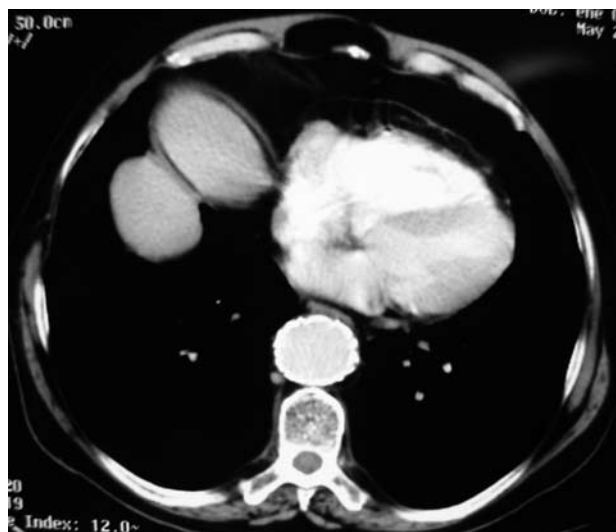
Ten days after being admitted, the patient was discharged; he was asymptomatic and without complications.

Two months later, an examination done by our division found the patient to be asymptomatic. A routine CT showed the endoprosthesis positioned correctly and absence of intramural haematoma due to reabsorption (Figure 2).

Penetrating aortic ulcers typically occur in the thoracic aorta, and primarily in elderly patients. They occur fundamentally in aortas that are significantly



**Figure 1.** Computerised tomography angiography at time of admission. The 3D reconstruction shows the image of infiltrated internal layers of the descending thoracic aorta, at D9 level, together with an intramural haematoma that affects nearly the entire descending aorta.



**Figure 2.** Routine computerised tomography taken 2 months after implanting the endoprosthesis. Along the sagittal section, at the level where the penetrating ulcer would be, we observe the image of the correctly positioned endoprosthesis and the absence of both the ulcer and the intramural haematoma.

affected by atherosclerosis,<sup>1</sup> this condition, in conjunction with advanced age, weakens the aortic wall, which facilitates the process. Furthermore, the condition is related to a higher incidence rate of secondary complications, such as intramural haematoma, dissection, the formation of aneurysms or pseudoaneurysms, or acute aortic rupture.

The natural history of this disease, and therefore, its treatment algorithm are still being debated. There are data to support the idea that the penetrating aortic ulcer is extremely malignant, which calls for more aggressive treatment given the high risk of fatal complications that it presents. Other institutions

prefer a more conservative treatment, based on the premises of a lower risk of complications.

Therefore, when it comes to deciding which treatment for this condition is the most appropriate, the best approach is to base it on patient characteristics (whether he/she has cardiovascular risk factors that lead to a higher rate of complications), patient anatomy<sup>2</sup> (whether the lesion can be reached with open surgery or if it is compatible with endovascular treatment) and the way the disease presents,<sup>3</sup> which fundamentally concerns whether or not it is symptomatic, ulcer location and size and how large the intramural haematoma is, if present, which would also increase the risk of complications.

In this particular case, the patient came in with symptoms similar to those of acute aortic syndrome; the CT revealed a penetrating aortic ulcer with an extensive intramural haematoma. Its favourable location, in the descending thoracic aorta and at a distance from the aortic arch and the celiac artery, near preserved femoral and iliac arteries, enabled us to place an aortic endoprosthesis.

For this reason, we believe that penetrating aortic ulcers represent an illness for which implanting an aortic prosthesis using the endovascular method should be considered a corrective technique of choice. Whenever patient characteristics allow, we should call for use of this technique, considering that it has a low rate of complications compared with medical treatment or invasive surgery for this disease.

María A. Gutiérrez-Martín, Omar A. Araji,  
Carlos J. Velázquez, and José M. Barquero  
Departamento de Cirugía Cardiovascular,  
Hospital Universitario Virgen Macarena, Sevilla, Spain..

## REFERENCES

1. Thoralf M. Sundt. Intramural hematoma and penetrating aortic ulcer. *Curr Opin Cardiol.* 2007;22:504-9.
2. Botta L, Buttazzi K, Russo V, Parlapino M, Gostoli V, Di Bartolomeo R, et al. Endovascular repair for penetrating atherosclerotic ulcers of the descending thoracic aorta: early and mid-term results. *Ann Thorac Surg.* 2008;85:987-92.
3. Citro R, Bossone E, Patella MM, Provenza G, Luongo F, Galasso L, et al. Endovascular treatment of painless aortic ulcer detected by transesophageal echocardiography as an incidental finding. *J Cardiovasc Med.* 1993;8:1049-51.