

## Image in cardiology

# Acute Coronary Syndrome Due to Distal Embolization of a Thrombus Located in the Left Main Coronary Artery

## Síndrome coronario agudo por embolismo distal de un trombo localizado en el tronco común

Vicens Martí,\* Joan García-Picart, and Lidia Carballeira

Unidad de Hemodinámica, Departamento de Cardiología y Cirugía Cardíaca, Hospital de Sant Pau, Barcelona, Spain

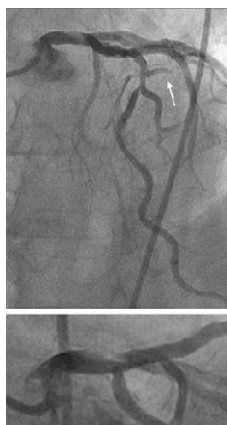

Figure 1.

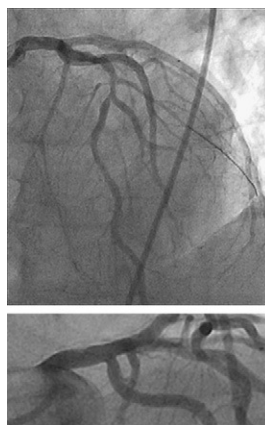


Figure 2.

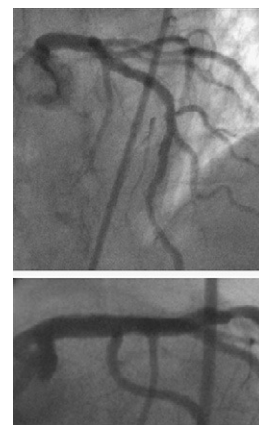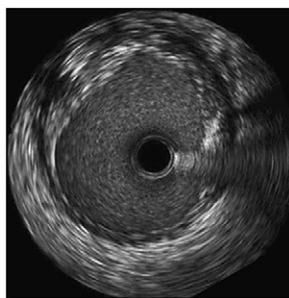


Figure 3.

A 54-year-old man with exertional angina of 2 months' evolution came to the hospital for pain that had lasted 1.45 h. The electrocardiogram showed ST segment elevation of 2 mm in leads I and aVL. Clopidogrel and acetylsalicylic acid were administered. Angiography disclosed a filling defect in the left main coronary artery (LMCA) consistent with a large thrombus, occlusion of the first diagonal artery, and slow flow in the second diagonal. Furthermore, severe stenosis was observed in the left anterior descending artery after the second diagonal (Fig. 1). Sodium heparin (1 mg/kg body weight) and abciximab (0.25 mg/kg bolus and 0.125  $\mu$ g/kg/min perfusion) were administered. A guidewire was advanced to the first diagonal and repeated thrombectomy was performed in the LMCA and first diagonal using a 6F Export XT aspiration catheter (Medtronic, Inc., Minneapolis, Minnesota, United States). The ischemia time (initiation of pain to thrombectomy) was 3 h. The following angiogram showed improvement of the LMCA image, patency of the first diagonal, and increased flow in the second diagonal. On intracoronary ultrasound, an image consistent with complicated plaque was seen between 10 and 3 o'clock (Fig. 2). Stent implantation was not performed. Enoxaparin 1 mg/kg body weight/day was prescribed. Five days later, the LMCA image had completely resolved and elective angioplasty of the left anterior descending artery with stent implantation was carried out (Fig. 3). The favorable results were maintained on follow-up coronary angiography and intracoronary ultrasound at 6 months, with no restenosis of the LMCA or the stent.

\* Corresponding author:  
E-mail address: [vmc18461b@hotmail.com](mailto:vmc18461b@hotmail.com) (V. Martí).  
Available online 17 April 2011