

Image in cardiology

TAVI Through the Left Subclavian Artery With a LIMA Graft

Prótesis aórtica vía subclavia con *bypass* de mamaria

Ignacio Cruz-González,^{a,*} Javier Martín-Moreiras,^a and Ramiro Trillo^b

^aServicio de Cardiología, Hospital Universitario de Salamanca, Salamanca, Spain

^bServicio de Cardiología, Hospital Universitario de Santiago, Santiago de Compostela, A Coruña, Spain

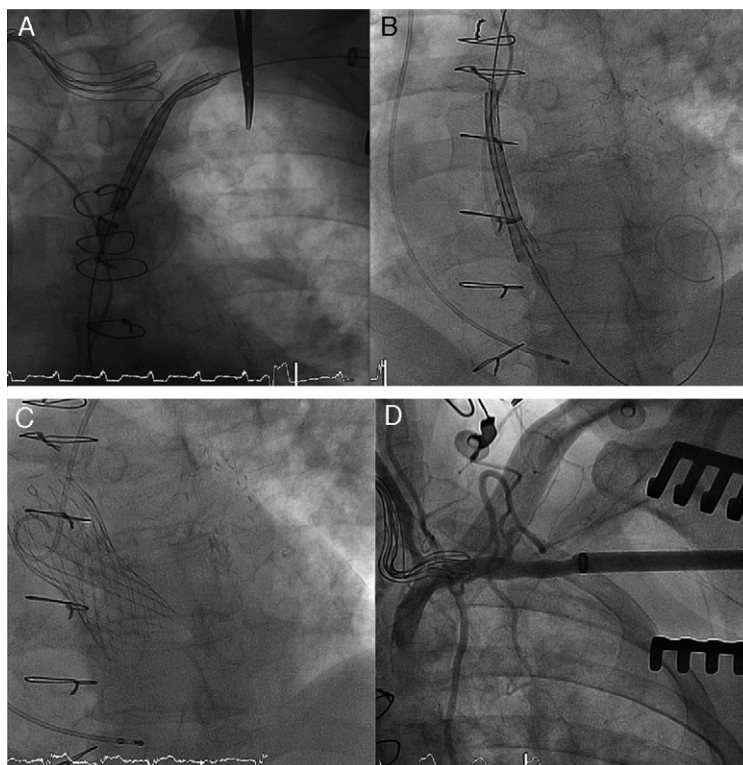


Figure 1.

We describe the case of a 64-year-old man with severe symptomatic aortic stenosis and a history of hypertension, diabetes, renal failure, peripheral arterial disease, pulmonary hypertension, moderate mitral regurgitation, ventricular dysfunction, carotid stenosis, and prior surgical coronary revascularization (internal mammary artery to the left anterior descending artery, radial to the obtuse marginal, and saphenous to the interventricular artery). Because of the patient's high surgical risk, he was considered a candidate for a transcatheter aortic valve implantation.

Following assessment of the different possibilities, implantation through a subclavian access was decided. The subclavian artery was exposed with a mini-incision and canalized following direct puncture. An 18-Fr introducer was advanced and maintained proximal to the origin of the mammary artery (Fig. 1A). A 29-mm CoreValve prosthesis (Medtronic) was implanted without complications (Figs. 1B and C). The mammary artery was seen to be unaffected on follow-up angiography (Fig. 1D).

Transaxillary or subclavian access is used as an alternative to the femoral or transapical route for transcatheter implantation of an aortic prosthesis. If the internal mammary artery has been used previously for coronary revascularization, use of this approach is considered contraindicated because of the potential for injury to the origin of the mammary artery when the introducer is advanced. It has been recently reported that this access is safe to advance the introducer to the ascending aorta, even in the presence of a mammary bypass. Nonetheless, the case presented is the first in which the implant was performed while maintaining the introducer proximal to the origin of the mammary artery, which reduces the risk of complications.

* Corresponding author:

E-mail addresses: cruzgonzalez.ignacio@gmail.com, i.cruz@usal.es (I. Cruz-González).

Available online 12 June 2011