

signs of endocarditis, leads to a strong suspicion of fibroelastoma. However, approximately one-fourth of the cases are anchored to the nonvalvular endocardium and the left ventricle is the most frequently affected site. In echocardiography, these tumors show up as mobile digitiform masses, with several villous structures originating from a stalk anchored to the endocardium. Involvement of the endocardial surface of the left atrium accounts for 1.5% to 9.5% of cases in different series,^{3,4} and the tumors are small, usually <1 cm. Our cases presented with a similar echocardiographic appearance: lobulated, highly mobile, homogeneous masses >2 cm, with a broad stalk, adhered to the endocardium of the left atrium. These atypical characteristics of papillary fibroelastoma required a differential diagnosis, essentially with a thrombus (unlikely in the absence of emboligenic structural heart disease) and with atrial myxoma. Given the similarities of our cases, we propose that the finding of a cardiac mass with the echocardiographic characteristics described above, and in the absence of emboligenic heart disease, provided diagnostic suspicion of papillary fibroelastoma at an atypical site.

Four years separated diagnosis of the 2 cases. Since 2000, 13 cases of echocardiographic suspicion of fibroelastoma have been included in our database. Apart from the 2 cases described here, the remaining 11 had a typical site and typical characteristics. Only 3 tumors were resected, and diagnosis of fibroelastoma was confirmed in 2. The 8 remaining patients are undergoing regular follow-up with imaging techniques.

When embolism is diagnosed, the whole tumor tends to be removed to avoid embolic recurrences. There is less agreement for asymptomatic tumors. If the mass is large and mobile, there is consensus about surgical resection if valve replacement is not necessary. However, in cases of typical valve location, small size (1 cm), and lack of excessive mobility, watchful waiting with anticoagulation therapy is considered appropriate.³

These recommendations do not, however, apply for fibroelastomas at atypical sites. The reasonable approach when faced with such masses is to rule out as many diagnoses as possible by noninvasive means. Gradual enhancement of magnetic resonance data may help in tumor diagnosis.⁵ Once diagnosed, surgical resection (provided the risk is not too high) can provide an indication of etiology, prognostic evaluation, and specific treatment.

Sem Briongos Figuero,^{a,*} Héctor Gerardo Pian,^b
José Luis Moya Mur,^a and Ramón Fernández Espino^b

^aServicio de Imagen Cardíaca, Instituto de Enfermedades Cardiovasculares, Hospital Ramón y Cajal, Madrid, Spain

^bServicio de Anatomía Patológica, Hospital Ramón y Cajal, Madrid, Spain

*Corresponding author:

E-mail address: Semdoc@hotmail.com (S. Briongos Figuero).

Available online 31 July 2011

REFERENCES

1. Yater WM. Tumors of the heart and pericardium: pathology, symptomatology and report of nine cases. *Arch Intern Med.* 1931;48:627–66.
2. Maraj S, Pressman GS, Figueredo VM. Primary cardiac tumors. *Int J Cardiol.* 2009;133:152–6.
3. Mariscalco G, Bruno VD, Borsani P, Dominici C, Sala A. Papillary fibroelastoma: insight to a primary cardiac valve tumor. *J Card Surg.* 2010;25:198–205.
4. Elbardissi AW, Dearani JA, Daly RC, Mullany CJ, Orszulak TA, Puga FJ, et al. Survival after resection of primary cardiac tumors: a 48-year experience. *Circulation.* 2008;118:S7–15.
5. Atalay MK, Taner AT. Gradual enhancement of a large left atrial papillary fibroelastoma on cardiac magnetic resonance. *Tex Heart Inst J.* 2010;37:612.

doi: [10.1016/j.rec.2011.04.022](https://doi.org/10.1016/j.rec.2011.04.022)

Proarrhythmic Potential of Amiodarone: An Underestimated Risk?

Potencial proarrítmico de la amiodarona: ¿un riesgo subestimado?

To the Editor,

Because of its known safety and efficacy, amiodarone is a first-line drug for the treatment of atrial and ventricular arrhythmias in patients with structural heart disease. Its proarrhythmic side effects are usually underestimated because they are less common than those experienced with other antiarrhythmic drugs. We describe a case of corrected QT interval prolongation (QTc) and *torsade de pointes* (TdP) secondary to amiodarone.

A 59-year-old woman with hypertension and chronic obstructive pulmonary disease with a significant bronchospastic component was attended at home for palpitations and dizziness. The electrocardiogram (ECG) showed self-limiting, regular, wide-QRS tachycardia at a rate of 210 bpm before admission and sinus rhythm at a rate of 90 bpm with a QRS duration of 90 ms and QTc of 415 ms on hospital admission (Fig. 1A). The cardiologic study revealed dilated cardiomyopathy with moderate ventricular dysfunction, but no major coronary lesions.

On the third day of hospitalization, the patient experienced well-tolerated sustained monomorphic ventricular tachycardia (SMVT) at a rate of 270 bpm (Fig. 2A) that reverted once intravenous perfusion of amiodarone was initiated.

Twenty-four hours later, the patient presented an episode of TdP that degenerated into ventricular fibrillation, which was treated by electrical cardioversion (Figs. 2B and C), and therefore she was transferred to our hospital.

The ECG on admission showed sinus rhythm at a rate of 75 bpm with a QRS duration of 146 ms and QTc of 714 ms (Fig. 1B). The patient presented no other recognizable factors that prolong QTc interval, except discrete hypopotassemia (3.2 mEq/L).

Although amiodarone was discontinued and potassium and magnesium supplements were given, she experienced 11 new episodes of TdP, which were controlled by implantation of a temporary ventricular pacemaker at 100 bpm (Fig. 1C) for 4 days. A week after amiodarone discontinuation, the QRS measured 110 ms and the QTc, 449 ms (Fig. 1D).

In view of the well tolerated SMVT episodes and the moderate nonischemic ventricular dysfunction, an electrophysiologic study was performed in which clinical SMVT originating in the apical lateral region of the left ventricle was induced and the circuit was ablated.

Amiodarone acts by blocking different ion channels involved in the action potential, which makes it effective for the treatment of various arrhythmias. The drug's dominant effect is class III, as it blocks potassium channels during repolarization and therefore can prolong the QTc interval.

QTc elongation is known to be the predisposing factor for the appearance of TdP, and although amiodarone can prolong the QTc few reports of amiodarone-induced TdP have been published.

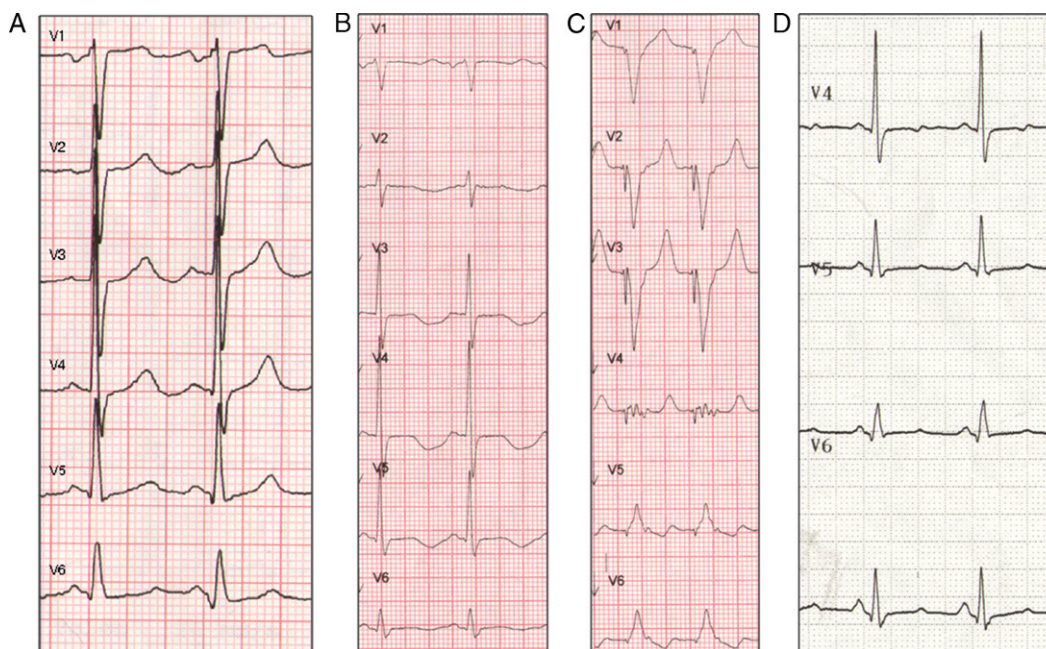


Figure 1. A, baseline electrocardiogram during sinus rhythm (90 bpm, QRS 90 ms, corrected QT interval 415 ms). B, electrocardiogram during sinus rhythm 24 h post-amiodarone dosing (75 bpm, QRS 146 ms, corrected QT interval 714 ms). C, pacemaker with pacing at 100 bpm. D, electrocardiogram during sinus rhythm 1 week after amiodarone discontinuation (75 bpm, QRS 110 ms, corrected QT interval 449 ms).

Several small series found no correlation between amiodarone-induced QTc prolongation and the onset of TdP, which indicates that it is safe even in patients with this arrhythmic complication.¹

The association was also detected in experimental animal studies, from which it can be inferred that the absence of TdP

with amiodarone may be related to homogeneous lengthening of the action potential duration and the absence of early afterdepolarizations.²

Although the incidence of TdP with amiodarone is low compared to other class III antiarrhythmic agents, it is known to be twice as high in women.^{3,4} Some published case reports have

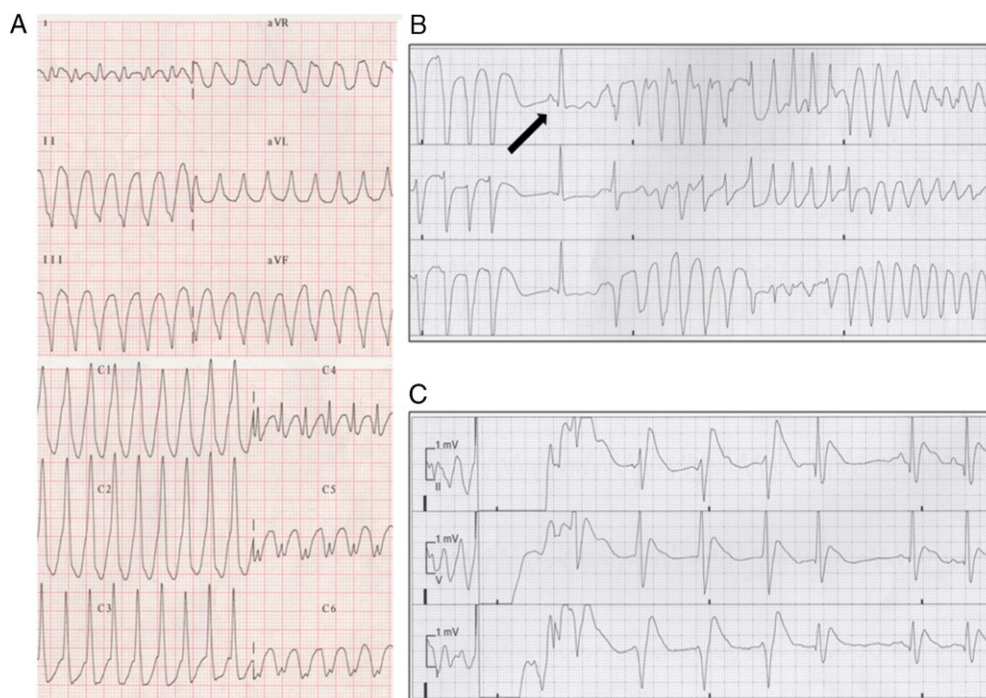


Figure 2. A, sustained monomorphic ventricular tachycardia. B, torsade de pointes. Note the sinus beat with long corrected QT interval preceding it (arrow). C, electrical cardioversion of ventricular fibrillation.

detected other associated factors that could prolong QTc (electrolyte abnormalities, bradycardia, etc.), which could enhance the proarrhythmic effect of the drug.⁵

In our patient, QTc prolongation showed a clear temporal relationship with amiodarone dosing both in terms of onset (24 h afterwards) and disappearance (1 week after the drug was discontinued).

Although slight hypokalemia was observed, TdP did not cease when the levels were corrected, which suggests that although the condition could have enhanced the proarrhythmic effect of the drug it was not the main cause.

In conclusion, although amiodarone is considered safe for the treatment of ventricular arrhythmia, its arrhythmogenic potential should not be underestimated, particularly in women and in the presence of concomitant factors that could prolong the QTc. Careful monitoring of the QTc interval and these factors can lower the risk of proarrhythmia.

Alfonso Jurado Román,* Belén Rubio Alonso, Roberto Martín Asenjo, Rafael Salguero Bodes, María López Gil, and Fernando Arribas Ynsaurriaga

Servicio de Cardiología, Hospital Universitario 12 de Octubre, Madrid, Spain

*Corresponding author:

E-mail address: alfonjroman@hotmail.com (A. Jurado Román).

Available online 2 August 2011

REFERENCES

- Mattioni TA, Zheutlin TA, Sarmiento JJ, Parker M, Lesch M, Kehoe RF. Amiodarone in patients with previous drug-mediated torsade de pointes. Long-term safety and efficacy. *Ann Intern Med.* 1989;111:574–80.
- Van Opstal JM, Schoenmakers M, Verduyn SC, De Groot SH, Leunissen JD, Van der Hulst FF, et al. Chronic amiodarone evokes no torsade de pointes arrhythmias despite QT lengthening in an animal model of acquired long-QT syndrome. *Circulation.* 2001;104:2722–7.
- Wolbrette DL. Risk of proarrhythmia with class III antiarrhythmic agents: sex-based differences and other issues. *Am J Cardiol.* 2003;91:D39–44.
- Makkar RR, Fromm BS, Steinman RT, Meissner MD, Lehmann MH. Female gender as a risk factor for torsades de pointes associated with cardiovascular drugs. *JAMA.* 1993;270:2590–7.
- Kukla P, Slowiak-Lewinska T. Amiodarone-induced torsade de pointes. Five case report. *Kardiol Pol.* 2004;60:365–70.

doi: 10.1016/j.rec.2011.05.018

Extreme QT Interval Prolongation and Helicoid Ventricular Tachycardia (Torsade de Pointes) in Non-ST-Elevation Acute Coronary Syndrome

Prolongación extrema del intervalo QT y taquicardia helicoidal (torsade de pointes) en el síndrome coronario agudo sin elevación del ST

To the Editor,

A prolonged corrected QT interval (cQT) during coronary ischemia is a well known sign that has even been incorporated into the parameters tested for the assessment of ischemic risk in acute coronary syndrome (ACS).¹ There is also a correlation

between a long QT and helicoidal ventricular tachycardia, or torsade de pointes (TdP), that has been described in this context.² Here, we present a case of ACS with a very prolonged QT interval with giant negative T-waves and a later development of TdP.

A 79-year-old woman sought emergency treatment for diffuse pain in the anterior thorax and dyspnea with 2 days evolution. She had a background of type-2 diabetes mellitus, systemic arterial hypertension, and rheumatoid arthritis. She was under treatment with metformin, vildagliptin, losartan, and indometacin. Upon admission to the hospital, the patient was dyspneic with a blood pressure of 219/96 mmHg, an O₂ saturation of 86%, and a regular pulse at 98 bpm, with notable bilateral basal crepitation. The abdomen was without abnormalities, with intact peripheral pulse. The initial electrocardiogram (ECG) (Fig. 1A) demonstrates a sinus

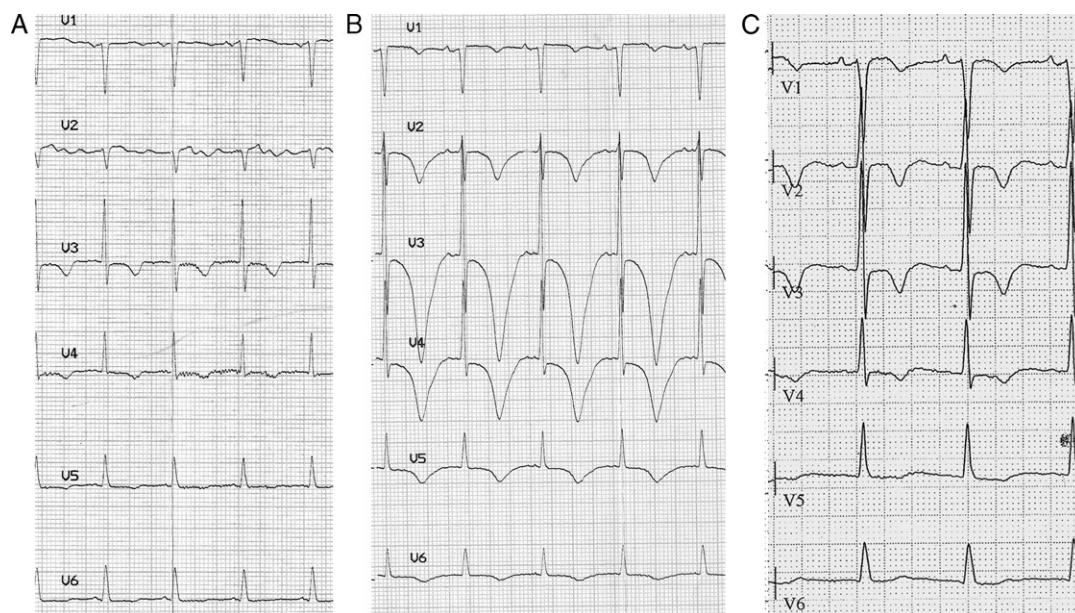


Figure 1. A, test results upon admission: RR, 640 ms; corrected QT interval, 510 ms. B, test results after 24 h: RR, 780 ms; corrected QT interval, 745 ms. C, test results after 13 days: RR, 760 ms; corrected QT interval: 504 ms. (Corrected QT intervals derived using Bazett's formula).