

Image in cardiology

Atrial Fibrillation: Misleading Physical Examination



Fibrilación auricular. La exploración física nos engaña

Juan C. Bonaque,* Rosa M. Soto, and Ramón Rubio-Patón

Servicio de Cardiología, Hospital General Universitario Santa Lucía, Cartagena, Murcia, Spain

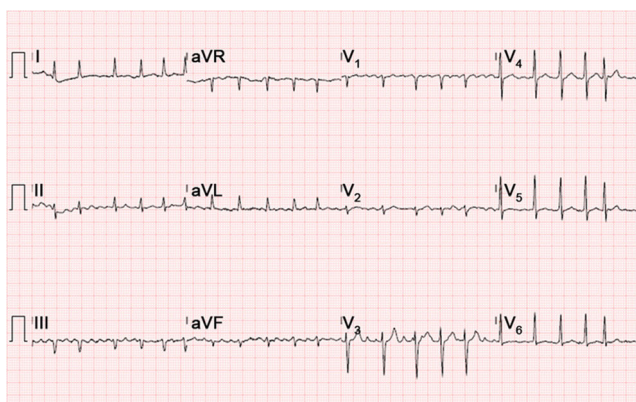


Figure 1.

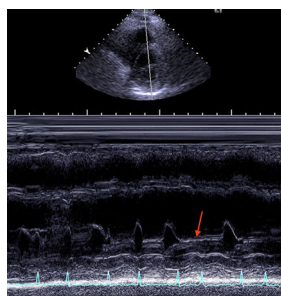


Figure 2.

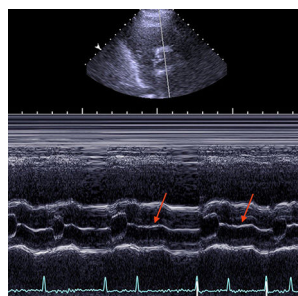


Figure 3.

A 70-year-old man presented to the emergency department of our hospital with acute heart failure in the context of atrial fibrillation with rapid ventricular response (Figure 1). Physical examination revealed an irregular pulse, with moist rales in lung fields and lower extremity edema. In addition, a simultaneous electrocardiographic recording disclosed the absence of heart sounds during short diastoles. This finding of “silent” heartbeats led us to perform an echocardiogram, which revealed a left ventricular ejection fraction dependent on the R-R interval, which was normal during long diastoles and showed severe systolic dysfunction during short diastoles. M-mode recording of the mitral and aortic valves was carried out to acquire short-axis images from the parasternal window; they disclosed the failure of the mitral valve to open during short R-R intervals (Figure 2, arrow), as well as the failure of the aortic valve to open during the beat that followed (Figure 3, arrows).

To the best of our knowledge, there have been no previous reports of the presence of isovolumetric beats. Indeed, a reduction in diastole during short cardiac cycles has been documented in patients with atrial fibrillation. The present case report describes this phenomenon in what is probably its most extreme form, with the absence of ventricular filling and failure of the mitral valve to open during very short cardiac cycles. Likewise, the systole following the absence of ventricular filling was ineffective in mechanical terms, as shown by the failure of the aortic valve to open. This unusual echocardiographic finding is clinically relevant as it demonstrates that cardiac auscultation can underestimate the heart rate of patients with atrial fibrillation.

* Corresponding author:
E-mail address: jc_bonaque@hotmail.es (J.C. Bonaque).
Available online 14 April 2015