

Image in cardiology

Raghib Syndrome. Surgical Treatment



Síndrome de Raghib. Tratamiento quirúrgico

Ramón Pérez-Caballero,^{a,*} Beatriz Plata Izquierdo,^b and Juan-Miguel Gil-Jaurena^a

^aServicio de Cirugía Cardiovascular Infantil, Hospital Materno-Infantil Gregorio Marañón, Madrid, Spain

^bUnidad de Cardiología Infantil, Complejo Asistencial Universitario de Salamanca, Salamanca, Spain

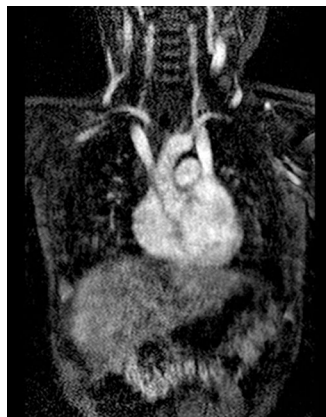

Figure 1.

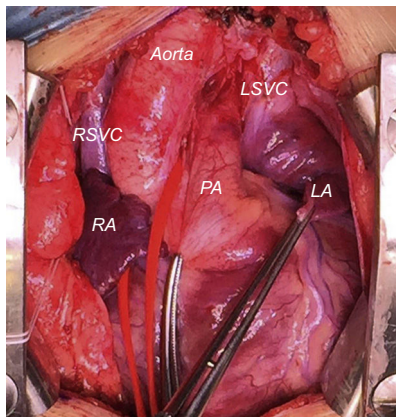


Figure 2.

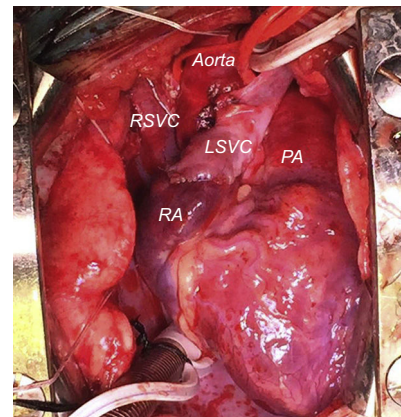


Figure 3.

Raghib syndrome is an extremely rare congenital heart defect characterized by persistent left superior vena cava (LSVC) draining into the left atrium and absence of the coronary sinus. Although few cases have been reported in the literature, there are a number of techniques to redirect the LSVC flow to the right atrium. These procedures include surgery to establish intracardiac flow using atrial patches to form a tunnel (along the roof of left atrium or the theoretical course of the coronary sinus), techniques for repositioning the interatrial septum, and techniques for extracardiac mobilization of the anomalous vein.

We present the case of an 18-month-old boy weighing 11 kg who had been diagnosed with Raghib syndrome. The boy was brought to our center for suspected heart disease secondary to progressive desaturation. Magnetic resonance imaging revealed persistent LSVC draining into the left atrium at the base of the atrial appendage and the absence of the coronary sinus (Figure 1). During the surgical intervention, we encountered 2 superior venae cavae of similar size and confirmed the anomalous drainage of the LSVC (Figure 2; LA, left atrium; LSVC, left superior vena cava; PA, pulmonary artery; RA, right atrium; RSVc, right superior vena cava). After evaluating all the surgical options, we decided to perform extracardiac correction of the defect with anastomosis of the LSVC to the right atrial appendage, passing in front of the aortic root (Figure 3). In our opinion, the extracardiac approach to this condition reduces suture tension in the left atrium and could prevent future arrhythmias; likewise, the absence of atrial tunnels avoids possible obstruction of pulmonary vein flow.

* Corresponding author:

E-mail address: ramonpc2003@yahoo.es (R. Pérez-Caballero).

Available online 17 July 2015