

**Table**

Theoretical Low-density Lipoprotein Reduction in Percentage Induced by Drugs in Monotherapy or in Combination

Drugs in monotherapy or in combination	Theoretical LDL cholesterol reduction, %
Low intensity statin	30
Moderate intensity statin	40
High intensity statin	50
Ezetimibe	20
PCSK9 inhibitor	60
Low intensity statin + ezetimibe	44
Moderate intensity statin + ezetimibe	52
High intensity statin + ezetimibe	60
Low intensity statin + PCSK9 inhibitor	72
Moderate intensity statin + PCSK9 inhibitor	76
High intensity statin + PCSK9 inhibitor	80
Low intensity statin + ezetimibe + PCSK9 inhibitor	78
Moderate intensity statin + ezetimibe + PCSK9 inhibitor	80
High intensity statin + ezetimibe + PCSK9 inhibitor	84

Low, moderate and high intensity statins are defined according to Stone et al.<sup>6</sup> LDL, low-density lipoprotein.

**CONFLICTS OF INTEREST**

L. Masana receives lecture or advisory fees from Amgen, Sanofi, MSD, Kowa, Recordati, Esteve, Danone, Chiesi; Praxis. N. Plana receives lecture fees from MSD Esteve, and D. Ibarretxe receives lecture fees from MSD.

Lluís Masana,\* Daiana Ibarretxe, and Nuria Plana

Unidad de Medicina Vascular y Metabolismo, Hospital Universitario Sant Joan, Universidad Rovira I Virgili, Instituto Investigación Sanitaria Pere Virgili (IISPV), CIBERDEM, Reus, Tarragona, Spain

\* Corresponding author:

E-mail address: [luis.masana@urv.cat](mailto:luis.masana@urv.cat) (L. Masana).

Available online 5 February 2016

**REFERENCES**

1. Cannon CP, Blazing MA, Giugliano RP, McCagg A, White JA, Theroux P, et al.; IMPROVE-IT Investigators. Ezetimibe added to statin therapy after acute coronary syndromes. *N Engl J Med*. 2015;372:2387-97.
2. Ference BA, Majeed F, Penumetcha R, Flack JM, Brook RD. Effect of naturally random allocation to lower low-density lipoprotein cholesterol on the risk of coronary heart disease mediated by polymorphisms in NPC1L1, HMGCR, or both: a 2 × 2 factorial mendelian randomization study. *J Am Coll Cardiol*. 2015; 65:1552-61.
3. Masana L, Pedro-Botet J, Civeira F. IMPROVE-IT clinical implications. Should the "high-intensity cholesterol-lowering therapy" strategy replace the "high-intensity statin therapy"? *Atherosclerosis*. 2015;240:161-2.
4. Robinson JG, Farnier M, Krempf M, Bergeron J, Luc G, Averna M, et al. ODYSSEY LONG TERM Investigators. Efficacy and safety of alirocumab in reducing lipids and cardiovascular events. *N Engl J Med*. 2015;372:1489-99.
5. Sabatine MS, Giugliano RP, Wiviott SD, Raal FJ, Blom DJ, Robinson J, et al. Open-label Study of Long-term Evaluation against LDL Cholesterol (OSLER) Investigators. Efficacy and safety of evolocumab in reducing lipids and cardiovascular events. *N Engl J Med*. 2015;372:1500-9.
6. Stone NJ, Robinson JG, Lichtenstein AH, Bairey Merz CN, Blum CB, Eckel RH, et al. 2013 ACC/AHA guideline on the treatment of blood cholesterol to reduce atherosclerotic cardiovascular risk in adults: a report of the American College of Cardiology/American Heart Association Task Force on Practice Guidelines. *Circulation*. 2014;129(25 Suppl 2):S1-45.

<http://dx.doi.org/10.1016/j.rec.2015.11.014>

### Subcutaneous Defibrillator: Role in the Prevention of Sudden Cardiac Death in the Setting of Mechanical Tricuspid Prosthesis



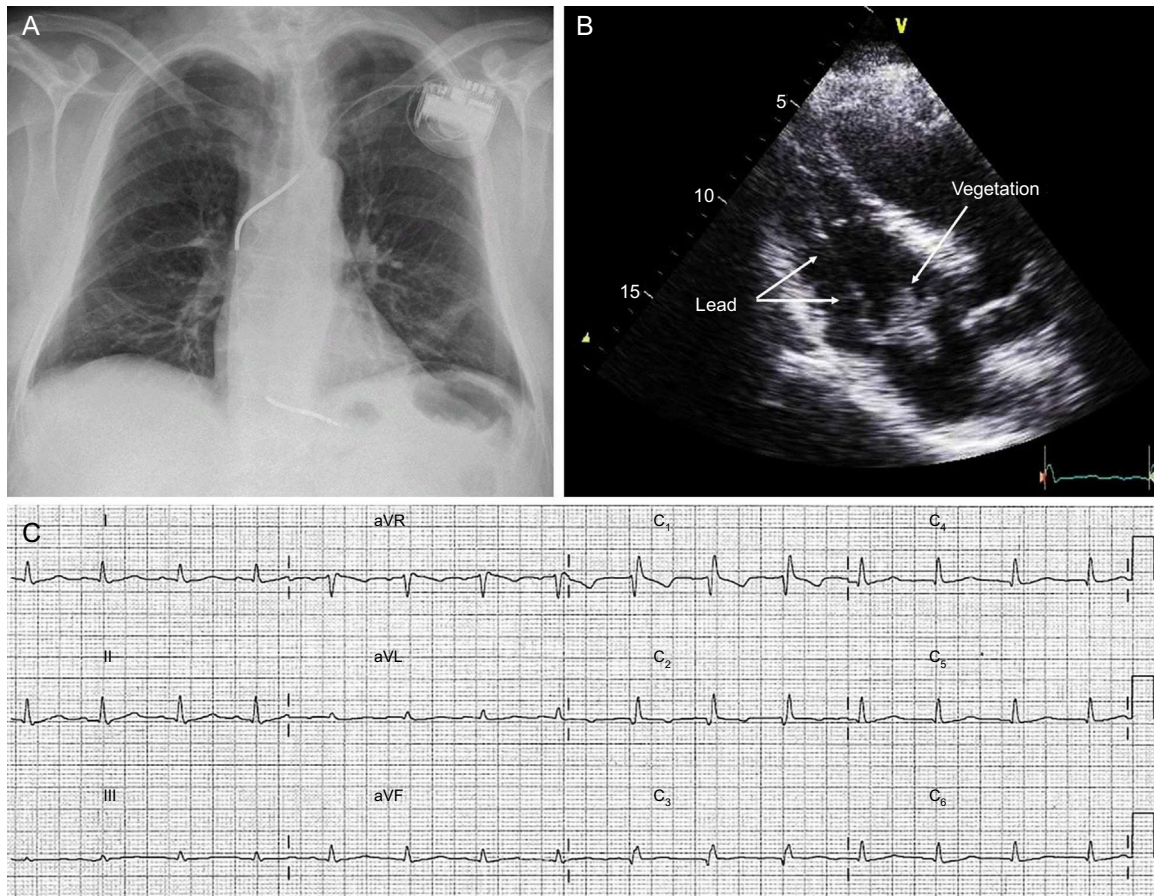
#### Desfibrilador subcutáneo: papel en la prevención de la muerte súbita en presencia de una prótesis mecánica tricúspide

**To the Editor,**

Adequate cardiac defibrillation with a conventional transvenous defibrillation system requires a defibrillation coil to be positioned in the right ventricle. However, this is contraindicated in patients with mechanical tricuspid prostheses. In these patients, implantation of defibrillation systems with epicardial patches via thoracotomy is a valid alternative, although it carries considerable morbidity and mortality. In the literature, isolated cases have been described of alternative techniques using the coronary sinus, which could allow a completely transvenous implantation.<sup>1</sup> The entirely subcutaneous implantable cardioverter-defibrillator (S-ICD) could represent a simple, effective, and safe alternative in many patients with a tricuspid mechanical prosthesis.

We present the case of a 58-year-old man who had an episode of ventricular tachycardia at 190 bpm, which was electrically cardioverted. He had documented ischemic heart disease, with a chronic anterior infarct of unknown duration, chronic occlusion of the mid-left anterior descending artery, and severe left ventricular systolic dysfunction. As secondary prevention, a

single-chamber transvenous ICD was implanted without complication (Figure 1), and he was started on treatment with antiplatelet agents, statins, bisoprolol, ramipril, and amiodarone. Sinus rhythm was maintained at 70 bpm, with right bundle branch block. Seven months later, having had no complications, the patient was admitted to hospital with a clinical picture of septic shock with symptoms of lumbar spondylodiscitis. Investigations included an echocardiogram, which revealed the presence of a large vegetation involving the defibrillation lead and the anterolateral leaflet of the tricuspid valve (Figure 1). Blood cultures were positive for methicillin-sensitive *Staphylococcus aureus*. Intravenous antibiotic therapy was started and cardiac surgery was performed via sternotomy for complete removal of the defibrillation system. Due to intraoperative findings, it was necessary to replace the tricuspid valve with a mechanical prosthesis. A deactivated epicardial permanent pacing lead was also placed, in case it was needed at follow-up. The patient progressed satisfactorily, and 6 weeks later, once stable, on anticoagulation with acenocoumarol, and with no residual sequelae, he underwent electrocardiographic screening for S-ICD implantation: all 3 vectors were positive. As permanent pacing was not required (Figure 1), an S-ICD (SQ-RX 1010, Boston Scientific) was implanted at the level of the left lateral thoracic wall, with a single-coil defibrillation lead (Q-Trak 3010, Boston Scientific S-ICD) at the left parasternal level, using a 2-incision technique (Figure 2). Acenocoumarol was continued throughout, with an international normalized ration (INR) of 3. A defibrillation

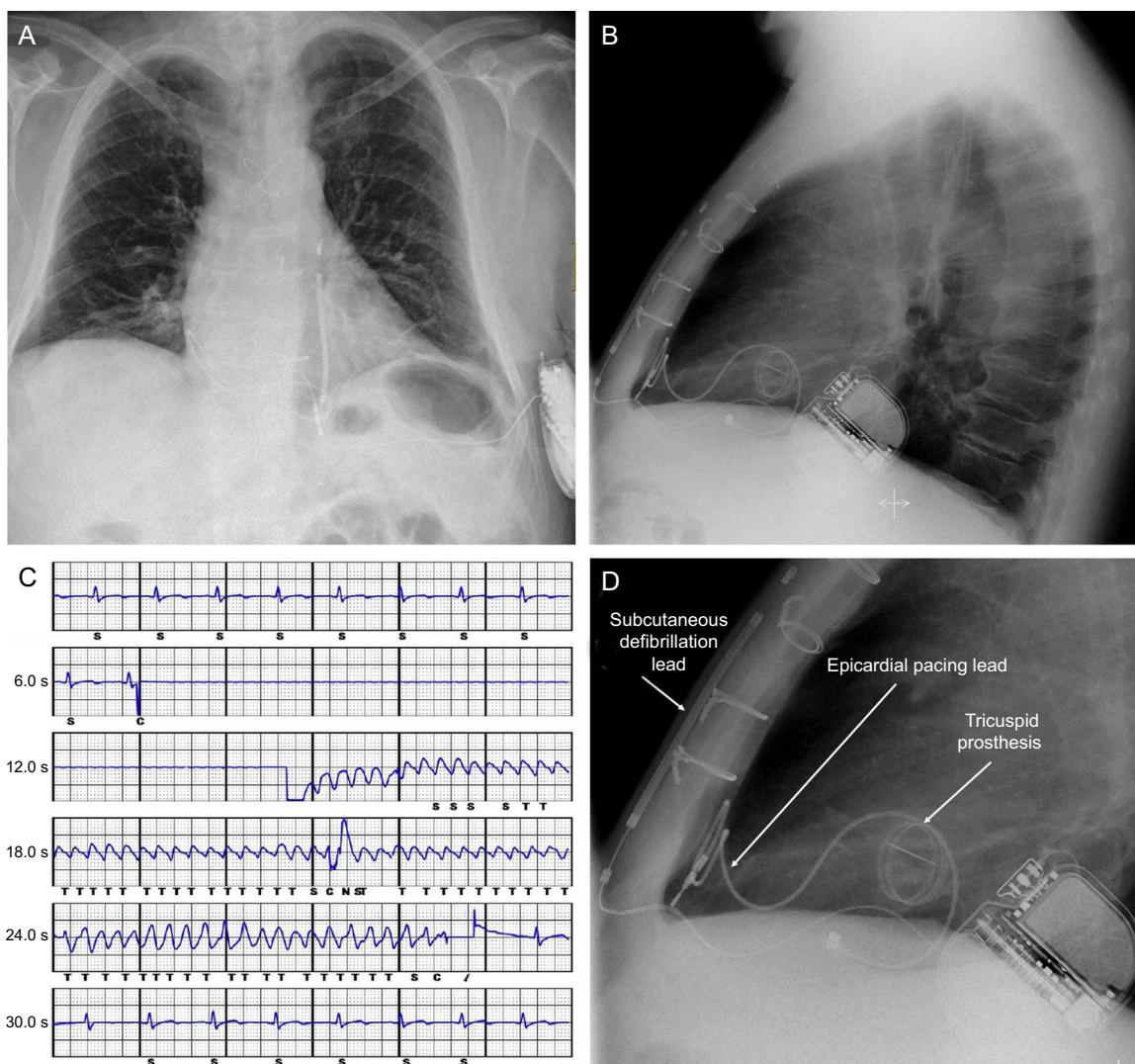


**Figure 1.** A: Chest X-ray with implanted transvenous defibrillator. B: Image from transthoracic echocardiogram showing the defibrillation lead and a large vegetation involving the tricuspid valve. C: Electrocardiogram following cardiac surgery.

check was performed: ventricular fibrillation was induced, which the device detected and treated effectively with the first programmed shock of 65 J (Figure 2). The secondary vector (distal-can electrode) was programmed for detection, with a conditional zone of 170 bpm and a shock zone of 250 bpm, with up to 5 shocks of 80 J. The patient was discharged from hospital the following day, with no complications. Seven months later, there have been no clinical events, and at device checks the parameters have been appropriate and no episodes have been recorded.

The cumulative experience of the S-ICD, developed to detect and treat malignant ventricular arrhythmias without the need for lead-implantation in the heart via the vascular system, is promising,<sup>2,3</sup> to say the least, as reflected in the recently published 2015 European guidelines on the treatment of ventricular arrhythmias and the prevention of sudden cardiac death.<sup>4</sup> In addition, in individuals such as this patient, requiring not only complete removal of the transvenous system due to infection, which makes the patient high-risk for subsequent infection, but

also replacement of the tricuspid valve with a mechanical prosthesis, the S-ICD has been shown to be an attractive alternative due to its efficacy and safety, avoiding the risks inherent to other more invasive and complex techniques. Moreover, in patients who have received an S-ICD as a replacement for a transvenous system removed due to infection, the rate of S-ICD infections has been reported as low,<sup>5</sup> adding value to this new therapy in this context. In patients who have a tricuspid valve prosthesis and require permanent pacing for whatever reason, an S-ICD is not suitable, although it can be compatible with other pacing systems (such as bipolar epicardial pacemakers) (Figure 2).<sup>6</sup> In such situations, the decision on the technique and system to be used should be individualized to obtain the best result. Moreover, given the current inability of the S-ICD to treat sustained ventricular tachycardia with antitachycardia pacing (which in many patients leads to a reduction in shocks), in patients at risk, S-ICD can be complemented with an ablation procedure of the ventricular substrate.



**Figure 2.** A and B: Posterior-anterior and lateral chest X-ray after removal of transvenous system and implantation of tricuspid mechanical prosthesis and subcutaneous implantable cardioverter-defibrillator. C: Recording of ventricular fibrillation induction test with the subcutaneous implantable cardioverter-defibrillator. D: Details of the tricuspid prosthesis, the epicardial lead for potential pacing, and the lead and generator of the subcutaneous implantable cardioverter-defibrillator.

## CONFLICTS OF INTEREST

M.A. Arias is a proctor of the Boston Scientific S-ICD system and a member of the editorial team of *Revista Española de Cardiología*.

Miguel A. Arias,\* Marta Pachón, Finn Akerström, Alberto Puchol, Andrés Sánchez-Pérez, and Luis Rodríguez-Padial

Unidad de Arritmias y Electrofisiología Cardíaca, Servicio de Cardiología, Hospital Virgen de la Salud, Toledo, Spain

\*Corresponding author:

E-mail address: [maapalomares@secardiologia.es](mailto:maapalomares@secardiologia.es) (M.A. Arias).

Available online 29 January 2016

## REFERENCES

1. Lopez JA. Implantable cardioverter defibrillator lead placement in the middle cardiac vein after tricuspid valve surgery. *Europace*. 2012;14:853-8.

2. Burke MC, Gold MR, Knight BP, Barr CS, Theuns DA, Boersma LV, et al. Safety and efficacy of the totally subcutaneous implantable defibrillator: 2-year results from a pooled analysis of the IDE Study and EFFORTLESS Registry. *J Am Coll Cardiol*. 2015;65:1605-15.
3. Arias MA, Pachón M, Akerström F, Puchol A, Giacoman-Hernández S, Rodríguez-Padial L. Implantation of the subcutaneous implantable defibrillator S-ICD(TM): initial experience in a single Spanish center. *Rev Esp Cardiol*. 2015;68:629-30.
4. Priori SG, Blomström-Lundqvist C, Mazzanti A, Blom N, Borggrefe M, Camm J, et al. Task Force Members. 2015 ESC Guidelines for the management of patients with ventricular arrhythmias and the prevention of sudden cardiac death: the task force for the management of patients with ventricular arrhythmias and the prevention of sudden cardiac death of the European Society of Cardiology (ESC). *Eur Heart J*. 2015;36:2793-867.
5. Boersma L, Burke MC, Neuzil P, Lambiase P, Friehling T, Theuns DA, et al. Infection and mortality after implantation of a subcutaneous ICD after transvenous ICD extraction. *Heart Rhythm*. 2015. <http://dx.doi.org/10.1016/j.hrthm.2015.08.039>.
6. Kuschyk J, Stach K, Tülümen E, Rudic B, Liebe V, Schimpf R, et al. Subcutaneous implantable cardioverter-defibrillator: first single-center experience with other cardiac implantable electronic devices. *Heart Rhythm*. 2015;12:2230-8.

<http://dx.doi.org/10.1016/j.rec.2015.11.015>