

patients should be closely followed-up by echocardiography during and after the procedure. On echocardiography, detection of thrombus formation on the implanted aortic valve is essential after TAVI and interventional cardiologist should promptly start antiplatelet and antithrombotic treatment after TAVI in those patients.

In conclusion, it is very important to be aware of this catastrophic event and all interventional cardiologists should take all preventive actions such as placing a guiding catheter in the left coronary ostium.

Cengiz Ozturk,* Ali Osman Yildirim, Mustafa Demir, and Sevket Balta

Department of Cardiology, Gulhane Military Medical Academy, School of Medicine, Etilik-Ankara, Turkey

*Corresponding author:

E-mail address: drcengizozturk@yahoo.com.tr (C. Ozturk).

Available online 3 March 2016

REFERENCES

1. Mori Junco R, Domínguez Melcon F, Moreno Yangüela M. Coronary Thromboembolism During Transcatheter Aortic Valve Replacement. *Rev Esp Cardiol.* 2015;68:893.

2. Chandrasekhar J, Hibbert B, Ruel M, Lam BK, Labinaz M, Glover C. Transfemoral vs Non-transfemoral Access for Transcatheter Aortic Valve Implantation: A Systematic Review and Meta-analysis. *Can J Cardiol.* 2015. <http://dx.doi.org/10.1016/j.cjca.2015.04.023>
3. Demirkol S, Ozturk C, Balta S, Unlu M. Right ventricular function in patients undergoing surgical or transcatheter aortic valve replacement. *Eur J Cardiothorac Surg.* 2015. pii: ezv307. [Epub ahead of print] No abstract available.
4. Ozturk C, Demirkol S, Demir M, Yildirim AO, Balta S, Celik T, et al. Mobile mass lesion in the aorta after transcatheter aortic valve implantation: Thrombus or residue calcification. *Int J Cardiol.* 2015;198:45–6.
5. Ilysoy A, Ozturk C, Demirkol S, Celik T, Aparci M, Demir M, et al. Aortic and right ventricular rupture in a patient after transcatheter aortic valve implantation; The direction of the calcification predicts aortic annulus rupture. *Int J Cardiol.* 2015;193:49–52.
6. Córdoba-Soriano JG, Puri R, Amat-Santos I, Ribeiro HB, Abdul-Jawad Altisent O, del Trigo M, et al. Valve Thrombosis Following Transcatheter Aortic Valve Implantation: A Systematic Review. *Rev Esp Cardiol.* 2015;68:198–204.
7. Ielasi A, Latib A, Montorfano M, Colombo A. Sandwich Stenting to Treat an Ostial Left Main Narrowing Following Transcatheter Aortic Valve Implantation. *Rev Esp Cardiol.* 2011;64:1220–2.
8. Dağdelen S, Gök H, Alhan C. Acute left main coronary artery occlusion following TAVI and emergency solution. *Anatol J Cardiol.* 2011;11:747–8.
9. Ergene O, Emren V, Duygu H, Eren NK. A case of occurring hemodynamic deterioration and ST-segment elevation during transcatheter aortic valve implantation. *Turk Kardiyol Dern Ars.* 2014;42:556–9.

SEE RELATED ARTICLES:

<http://dx.doi.org/10.1016/j.rec.2014.11.020>

<http://dx.doi.org/10.1016/j.rec.2016.01.007>

<http://dx.doi.org/10.1016/j.rec.2015.12.012>

Coronary Obstruction During Transcatheter Aortic Valve Replacement: Related to Calcification or Thrombus? Response



Obstrucción coronaria durante el implante percutáneo de válvula aórtica: ¿relacionada con calcificación o con trombo? Respuesta

To the Editor,

We appreciate the comments of Ozturk et al on our publication entitled, “Coronary Thromboembolism During Transcatheter Aortic Valve Replacement”.¹

The case in question concerned a patient with high thromboembolic risk who received 2 drug-eluting stents in the anterior descending artery during coronary angiography 1 month before the valve replacement procedure. The patient received dual antiplatelet therapy after the angioplasty and, later, unfractionated heparin during the transcatheter aortic valve implantation to maintain an activated clotting time between 200 and 250 s. Thus, the patient received complete antithrombotic therapy despite a high risk of bleeding (hypertension, diabetic nephropathy, and chronic alcoholic liver disease). We do not know if there were fluctuations in the anticoagulation level during the procedure. After the implant, the patient continued to receive dual antiplatelet therapy. Although coronary thromboembolic complications during aortic valve implantation are infrequent (around 1%²), they can be catastrophic³ and thus require urgent treatment.

Calcifications in the left ventricular outflow tract, the native aortic valve itself, and the ascending aorta can lead to certain complications.^{4–6} Another possible complication to bear in mind is coronary embolism of calcified material. In our patient, the

presence of an intracoronary thrombus was revealed using a thromboaspiration device. Because this device is designed to remove intravascular thrombi, it helped to achieve optimal myocardial perfusion.

Cases such as this one reinforce the need for adequate procedure-related antithrombotic therapy, in addition to transesophageal echocardiography monitoring to permit early detection of complications requiring urgent management, as well as for other uses.

Ricardo Mori Junco,^{a,*} Francisco Domínguez Melcón,^b and Mar Moreno Yangüela^b

^aServicio de Cardiología. Hospital Universitario La Paz, Madrid, Spain

^bUnidad de Imagen Cardíaca, Servicio de Cardiología, Hospital Universitario La Paz, Madrid, Spain

*Corresponding author:

E-mail address: ricardomori22@gmail.com (R. Mori Junco).

Available online 3 March 2016

REFERENCES

1. Mori Junco R, Domínguez Melcon F, Moreno Yangüela M. Tromboembolia coronaria durante implante percutáneo de prótesis aórtica. *Rev Esp Cardiol.* 2015;68:893.
2. Seiffert M, Conradi L, Baldus S, Schirmer J, Blankenberg S, Reichenspurner H, et al. Severe intraprocedural complications after transcatheter aortic valve implantation: calling for a heart team approach. *Eur J Cardiothorac.* 2013;44:478–84.
3. Seiffert M, Schnabel R, Conradi L, Diemert P, Schirmer J, Koschyk D. Predictors and outcomes after transcatheter aortic valve implantation using different

approaches according to the valve academic research consortium definitions. *Catheter Cardiovasc Interv.* 2013;82:640-52.

4. Montarello N, Copus B, Prakash R, Worthley SG. Peripheral embolization of aortic valve calcium following trans-femoral Sapien XT valve implantation requiring emergency surgical embolectomy. *Int J Cardiol.* 2015;181:17-8.

5. Colli A, D'Amico R, Sci S, Kempfert J, Borger MA, Mohr F, et al. Transesophageal echocardiographic scoring for transcatheter aortic valve implantation: Impact of aortic cusp calcification on postoperative aortic regurgitation. *J Thorac Cardiovasc Surg.* 2011;142:1229-35.

6. Ozturk C, Demirkol S, Demir M, Yildirim AO, Balta S, Celik T, et al. Mobile mass lesion in the aorta after transcatheter aortic valve implantation: Thrombus or residue calcification. *Int J Cardiol.* 2015;198:45-6.

SEE RELATED ARTICLE:
<http://dx.doi.org/10.1016/j.rec.2015.12.012>

<http://dx.doi.org/10.1016/j.rec.2016.01.007>

Could Descending Septal Artery Be Another Variant of the Dual Left Anterior Descending Artery?



¿Podría ser la arteria septal descendente otra variante de la doble arteria descendente anterior?

To the Editor,

We read with great interest the article by Montero-Cabezas et al,¹ which prompted us to ask the question forming the title of this letter.

Absence of the first septal branch of the left anterior descending artery (LAD) on left coronary angiography not only raises the suspicion of the presence of a descending septal artery, or Bonapace's branch, as mentioned by the authors themselves mention,¹ but also clearly demonstrates the existence of a congenital coronary anomaly of the LAD.

According to Spindola-Franco et al,² the LAD is the coronary artery with the most constant origin, course, and distribution in the

human heart; however, many anatomical variants have been described in the literature.²⁻¹⁰

Such congenital coronary anomalies are rare. Their incidence is between 0.64% and 1.3% but can reach almost 6%. Dual LAD represents 1.2% to 6.1% of all coronary anomalies.³

Notably, the definition of the descending septal artery by Montero-Cabezas et al¹ has similarities to the updated classification of type IV dual LAD,³ except that it could be considered the opposite: in the description by Montero-Cabezas et al, it is the short LAD (in this case the descending septal artery) that originates from the right coronary artery, or close to it, and the long LAD continues normally as a branch of the left coronary artery (Figure 1).

In such cases, the descending septal artery could be considered a new type of dual LAD, rather than an isolated variant of coronary anomalies. The types proposed by Montero-Cabezas et al¹ would constitute its anatomical variants; therefore, the classification of dual LAD would remain as described in Figure 2.

The possibility of combining these types of anomaly of the origin, course, and distribution of the LAD could have important implications in clinical practice.

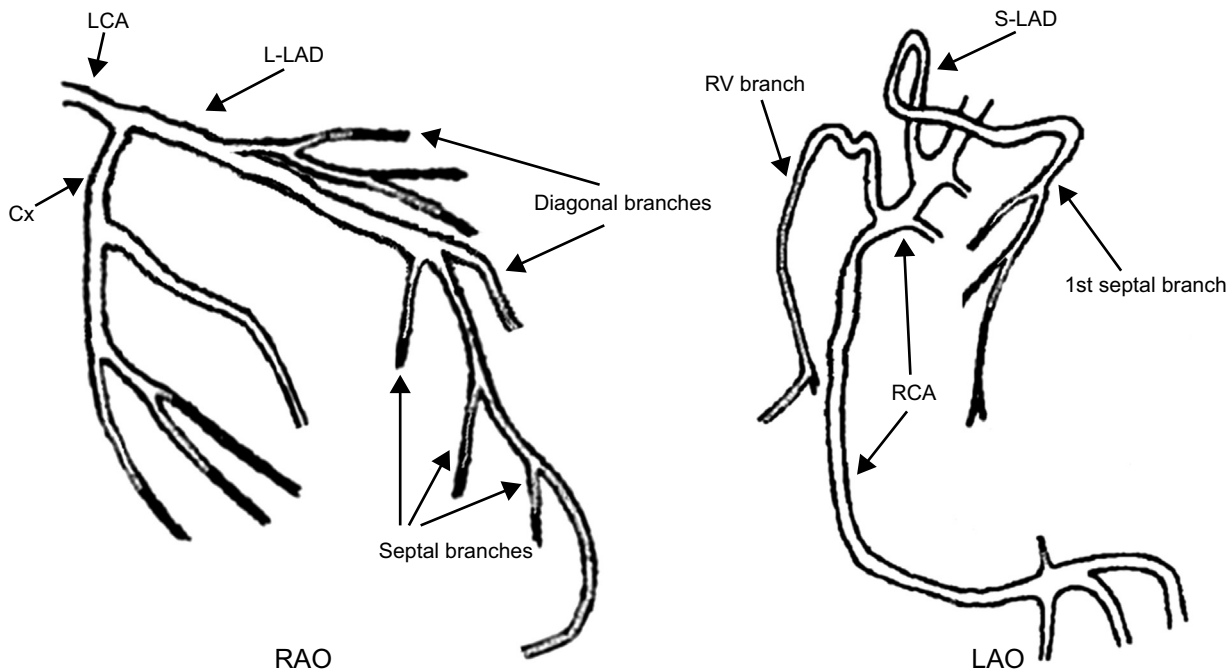


Figure 1. Type V left anterior descending artery. Modified with permission from Moreno-Martínez et al,³ showing a graphical representation of the other types of dual left anterior descending artery. Cx, circumflex artery; LAO, left anterior oblique; LCA, left coronary artery; L-LAD, long left anterior descending artery; RAO, right anterior oblique; RCA, right coronary artery; RV, right ventricle; S-LAD, short left anterior descending artery.