

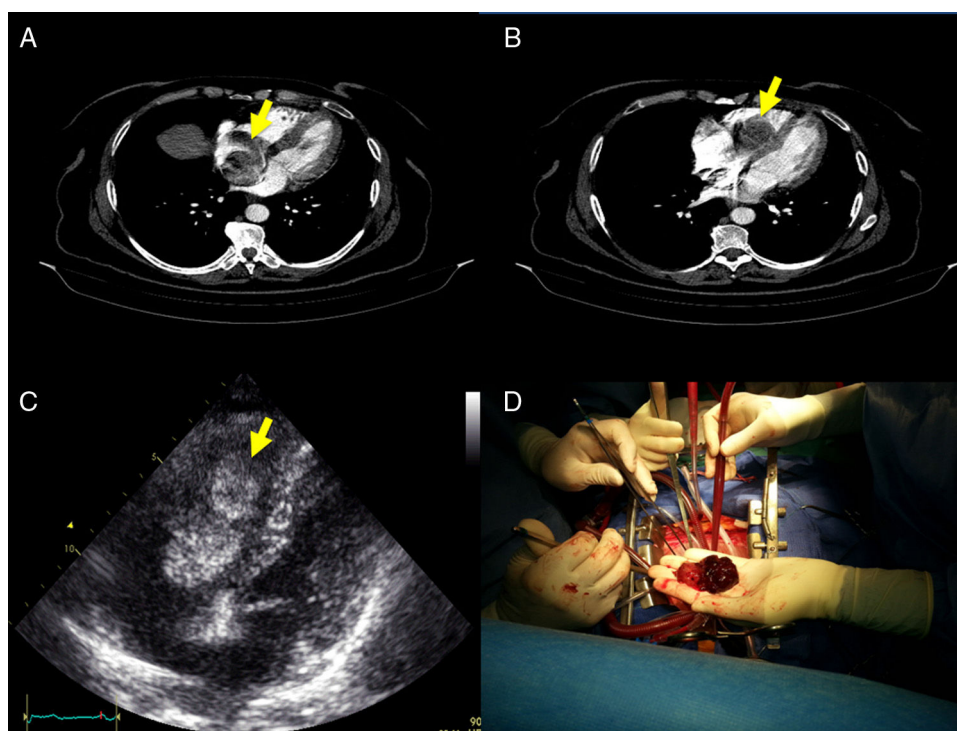
## Scientific letters

**Giant Right Atrial Myxoma and Refractory Hypoxia: An Unexpected Combination****Mixoma gigante e hipoxia refractaria: una combinación inesperada****To the Editor,**

Myxoma is the most frequent cardiac tumor, representing 50% of cases, and is considered benign, although there have been some reports of associated cerebral or pulmonary emboli.<sup>1–3</sup> We describe the case of a woman with right atrial myxoma with an unusual clinical presentation due to the location of the tumor, which posed a difficult diagnostic dilemma. This was a 57-year-old woman who was admitted from the emergency department with a 6-month history of progressive dyspnea with associated occasional episodes of palpitations, dizziness, and general malaise. The patient had hypertension, diabetes, and obesity, but no past cardiological history.

On arrival, blood pressure was 115/73 mmHg, heart rate was 78 bpm, and oxygen saturation was 80% at rest on room air, which was recorded on various occasions. Arterial blood gases showed severe hypoxemia (pO<sub>2</sub>, 49 mmHg) with hypocapnia (pCO<sub>2</sub>, 24 mmHg). There were no signs of pulmonary edema, but there were signs of right heart failure in the form of jugular venous distension, hepatojugular reflux, hepatomegaly of 2 cm, and mild ankle edema. Auscultation revealed a systolic murmur and an early

diastolic tumor “plop” at the left parasternal edge. Electrocardiography showed sinus rhythm and an S1Q3T3 pattern. Full blood count showed mild polycythemia (hemoglobin, 16.7 g/dL; hematocrit, 51.8%). On chest X-ray, there was a mild increase in right atrial volume with no pulmonary changes. The first suspected diagnosis was pulmonary thromboembolism. However, computed tomography with contrast showed no evidence of acute emboli but did show a large mass in the right atrium (Figures A-B). Transthoracic echocardiography confirmed the existence of a mass suggestive of myxoma, which was anchored to the interatrial septum and prolapsed through the tricuspid annulus, causing obstruction during diastole, with alternating severe tricuspid regurgitation-stenosis (Figure C). Pulmonary artery pressures could not be assessed. The patient was admitted to the acute coronary care unit, where, in the first few hours, persistent dyspnea and severe desaturation were recorded, which worsened on sitting up despite administration of high-flow oxygen. Cardiac telemetry revealed atrial tachycardia alternating with periods of sinus bradycardia. The patient’s refractory hypoxemia, not fully explained by the obstruction from the right atrial myxoma or by pulmonary disease, led to suspicion of an intracardiac shunt. An echocardiogram was performed with administration of agitated saline, which held the key to the diagnosis. Bubbles were observed passing into the left atrium in the first 3 cardiac cycles through a patent foramen ovale with a significant right-to-left shunt (video in [supplementary material](#)).



**Figure.** A: multidetector computed tomography identified a mobile RA mass (arrow); B: the mass prolapsed through the tricuspid annulus; C: transthoracic echocardiography showed a large right atrial mass suggestive of myxoma, measuring 31 mm × 59 mm, anchored to the interatrial septum, which prolapsed through the tricuspid annulus and caused obstruction during diastole; and D: these findings were confirmed at surgery.

Surgery was performed within 12 hours from admission, with resection of a large gelatinous mass from the right atrium, anchored to the interatrial septum at the opening of the coronary sinus (Figure D), and primary closure of the foramen ovale. Pathological studies showed a myxoid matrix with an excess of blood vessels and areas of hemorrhage, which was confirmed with immunohistochemical analysis. The postoperative period was uneventful and the patient has remained asymptomatic during the first year of follow-up.

Only 15% to 20% of myxomas are in the right atrium.<sup>1,2</sup> To date, there are fewer than 10 reported cases of right atrial myxoma with associated foramen ovale in the literature.<sup>4,5</sup> The reverse interatrial shunt may be explained by high interatrial pressures, if there is severe tricuspid stenosis with regurgitation. Cyanosis and hypoxemia may change with the patient's positioning. As with all right-to-left shunts, this case was resistant to oxygen therapy. In patients such as ours, there is a considerable risk of systemic embolism and sudden death secondary to tricuspid valve obstruction, and they should be treated as a surgical emergency.

This patient had an unusual presentation, with an obstructive myxoma in the right atrium and an associated patent foramen ovale that led to a right-to-left shunt, causing the onset of orthodeoxia, which posed a difficult diagnostic dilemma.<sup>6</sup> The possibility of complications with myxomas should not be underestimated, and an intracardiac shunt should be suspected in patients with refractory hypoxia with no obvious cause.

#### SUPPLEMENTARY MATERIAL



Supplementary material associated with this article can be found in the online version at [doi:10.1016/j.rec.2016.05.023](https://doi.org/10.1016/j.rec.2016.05.023).

Alba Santos-Ortega,<sup>a</sup> Antonia Sambola,<sup>a,\*</sup> Gerard Martí,<sup>a</sup> José A. Barrabés,<sup>a</sup> Rafael Rodríguez,<sup>b</sup> and David García-Dorado<sup>a</sup>

<sup>a</sup>Departamento de Cardiología, Hospital Universitari Vall d'Hebron, Universitat Autònoma de Barcelona, Barcelona, Spain

<sup>b</sup>Departamento de Cirugía Cardíaca, Hospital Universitari Vall d'Hebron, Universitat Autònoma de Barcelona, Barcelona, Spain

\*Corresponding author:

E-mail address: [asambola@vhebron.net](mailto:asambola@vhebron.net) (A. Sambola).

Available online 14 September 2016

#### REFERENCES

1. Reynen K. Cardiac myxomas. *N Engl J Med*. 1995;333:1610–7.
2. Cheema U, Thomas J. A giant right atrial myxoma presenting as acute pulmonary emboli. *Eur Heart J Cardiovasc Imaging*. 2012;13:799.
3. Saitoh H, Tsuchiya K, Osawa H, Kurihara H, Iida Y. Surgical removal of right atrial myxoma with severe hypoxemia caused by right to left shunt through persistent foramen ovale. *Kyobu Geka*. 1998;51:1135–6.
4. Saitoh H, Kubota H, Takeshita M, Mizuno A, Suzuki M. Right atrial myxoma with right to left shunt and coronary artery disease. *Jpn Circ J*. 1994;58:76–9.
5. Rosso J, Lemaire F, Geschwind H, Vouhe P, Atassi K, Teisseire B. Right atrial myxoma: an unusual cause of intracardiac right-to-left shunt. *Bull Eur Physio-pathol Respir*. 1985;21:179–82.
6. Casanovas-Marbà N, Feijoo-Massó C, Guillaumon-Torán L, Guillaumet-Gasa E, Blanco BG, Martínez-Rubio A. Hipoxemia grave por shunt derecha-izquierda a través del foramen oval en ausencia de hipertensión pulmonar. Existe y se puede tratar con éxito. *Rev Esp Cardiol*. 2014;67:324–5.

<http://dx.doi.org/10.1016/j.rec.2016.05.023>  
1885-5857/

© 2016 Sociedad Española de Cardiología. Published by Elsevier España, S.L.U. All rights reserved.

#### One Heart for Two Recipients: An Effective Option to Increase Donor Organ Availability in Heart Transplantation



*Un corazón para dos receptores: una medida eficaz para aumentar la disponibilidad de órganos en el trasplante cardíaco*

To the Editor,

Heart transplant (HT) is the treatment of choice for patients with advanced heart failure, with outcomes of significantly improved life expectancy and quality of life. The main limitation is the lack of donors, which justifies the adoption of exceptional measures to make greater use of the organs available.

The first recipient was a 58-year-old man with a diagnosis of idiopathic dilated cardiomyopathy with refractory cardiogenic shock, who had received a Levitronix CentriMag left ventricular assist device as a bridge to transplant. The patient subsequently woke up and was extubated; HT was performed at 26 days postimplant and with a national priority status. The original donor was a 34-year-old man with no cardiovascular history, who died from a subarachnoid hemorrhage secondary to a ruptured cerebral aneurism. The patient had been in intensive care for 48 hours, was hemodynamically stable, requiring noradrenaline infusion at 0.5 µg/kg/min, and had a normal echocardiogram.

There were no complications of note during the HT. The ischemia time of the organ was 205 minutes. At 48 hours, the patient did not wake up, and brain computed tomography showed a massive ischemic stroke that led to brain death at 6 days post-HT. The patient maintained an excellent hemodynamic status, with no

arrhythmias, and was able to be weaned off isoproterenol on the third day with normal graft function on echocardiogram.

The second recipient was a 62-year-old man, who had been on the HT waiting list for 14 months due to ischemic dilated cardiomyopathy. He had undergone previous surgical revascularization and was inotrope-dependent (INTERMACS 3) on home treatment with intravenous milrinone. Echocardiography showed severe biventricular dysfunction and an apical mural thrombus.

A second transplant of the same organ was proposed after confirmation of the brain death of the first recipient on 2 consecutive electroencephalograms at 6 days post-transplant. The recipient was informed of the unusual origin of the donor organ and gave his consent. The hospital ethics committee approved the procedure. The implantation technique used was biatrial anastomosis, which is the standard practice in our hospital. The ischemia time was 50 minutes, and the extracorporeal circulation time was 75 minutes. Epicardial biopsy of the graft ruled out significant acute cellular rejection.

The recipient was treated with intravenous methylprednisolone intraoperatively, basiliximab as induction immunosuppression, and cyclosporine, mycophenolate mofetil, and prednisone as maintenance immunosuppression.

The patient progressed favorably in the immediate postoperative period, with early extubation and a 48-hour stay in the surgical intensive care unit. Subsequent complications of note consisted of prolonged symptomatic sinus node dysfunction for more than 2 weeks, requiring implantation of a dual chamber pacemaker, and symptomatic infection with cytomegalovirus, treated with valganciclovir.