

morbidity and mortality. Compared with Portugal, Sweden, and Japan, the endemic area of Mallorca shows more frequent left ventricular hypertrophy and heart failure and worse prognosis. Cardiologists should perform close follow-up of these patients—with annual ECG, echocardiography, and Holter monitoring—and expand the evaluation (eg, cardiac magnetic resonance imaging, diphosphonate scintigraphy) in the presence of symptoms or changes.

FUNDING

CIBEROBN (CB12/03/30038), Madrid, Spain.

Tomás Ripoll-Vera,^{a,b,c,*} Juan Buades,^{b,d} Eugenia Cisneros,^{b,d} Yolanda Gómez,^{a,b} Juana Núñez,^{a,b} and Manuel Raya^{b,d}

^aServicio de Cardiología, Hospital Universitario Son Llàtzer, Palma de Mallorca, Balearic Islands, Spain

^bInstituto de Investigación Sanitaria de Baleares (IdISBa), Palma de Mallorca, Balearic Islands, Spain

^cCiberOBN, Instituto de Salud Carlos III, Madrid, Spain

^dServicio de Medicina Interna, Hospital Universitario Son Llàtzer, Palma de Mallorca, Balearic Islands, Spain

*Corresponding author:

E-mail address: tripoll@hsll.es (T. Ripoll-Vera).

Available online 7 December 2017

REFERENCES

1. Ruberg FL, Berk JL. Transthyretin (TTR) cardiac amyloidosis. *Circulation*. 2012;126:1286–1300.
2. García-Pavía P, Tomé-Esteban M, Rapezzi C. Abordaje familiar en la amiloidosis cardiaca hereditaria por transtiretina. *Rev Esp Cardiol*. 2011;64:797–808.
3. Buades Reinés J, Ripoll Vera T, Uson Martin M, et al. Epidemiology of transthyretin associated familial amyloid polyneuropathy in the Majorcan area: Son Llatzer Hospital descriptive study. *Orphanet J Rare Dis*. 2014;9:29.
4. Rapezzi C, Perugini E, Salvi F, et al. Phenotypic and genotypic heterogeneity in transthyretin-related cardiac amyloidosis: towards tailoring of therapeutic strategies? *Amyloid*. 2006;13:143–153.
5. Gallego-Delgado M, González-López E, Muñoz-Beamud F, et al. El volumen extracelular detecta la amiloidosis cardiaca y está correlacionado con el deterioro neurológico en la amiloidosis familiar relacionada con la transtiretina. *Rev Esp Cardiol*. 2016;69:923–930.

<https://doi.org/10.1016/j.rec.2017.11.017>
1885-5857/

© 2017 Sociedad Española de Cardiología. Published by Elsevier España, S.L.U. All rights reserved.

Coronary Angiography and Interventions in Patients With Hereditary Hemorrhagic Telangiectasia



Angiografía coronaria e intervencionismo en pacientes con telangiectasia hemorrágica hereditaria

To the Editor,

Hereditary hemorrhagic telangiectasia (HHT) or Rendu–Osler–Weber syndrome is a rare autosomal dominant vascular disorder caused by mutations in the endoglin, *ACVRL1* or *SMAD4* genes that encode proteins involved in the transforming growth factor-beta superfamily, resulting in multiorgan vascular dysplasia. Clinical manifestations include spontaneous epistaxis, gastrointestinal bleeding, anemia, mucocutaneous telangiectasia, and multiorgan arteriovenous malformations.¹

Cardiovascular involvement encompasses high-output heart failure, paradoxical emboli, and venous thromboembolism. Arrhythmias are common, whereas myocardial infarction rates appear to be low.^{1,2}

Coronary angiography (CA) and percutaneous coronary intervention (PCI) in patients with HHT can be challenging in terms of the underlying coronary anatomy (atheromatosis, spontaneous coronary artery dissection [SCAD], and spasm), technical aspects, antithrombotic therapy, and increased bleeding risk.^{2–4} We sought to assess the potential risks of CA and PCI in HHT patients by identifying retrospectively all HHT patients undergoing CA in the University Hospitals of Leuven between January 2002 and July 2017.

During this 15-year period, 655 HHT patients were followed up in our tertiary referral center and 18 underwent a CA. A full list of baseline characteristics is summarized in the Table. Six patients (33.3%) underwent CA due to an acute coronary syndrome (ACS), 2 patients (11.1%) due to stable angina, 5 (27.7%) due to heart failure, 3 (16.6%) due to valvular disease, and 2 (11.1%) as part of pretransplant work-up. Thirteen patients (72.2%) had normal coronaries whereas 5 (27.8%) had abnormal findings. Coronary

artery disease was noted in 2 patients (11.1%), 1 presenting with a ST-segment elevation myocardial infarction (STEMI) treated with a bare-metal stent in the left anterior descending (LAD) and 1 with unstable angina treated with a bare-metal stent in the right coronary artery. Three patients (16.7%) exhibited SCAD of the LAD, 1 presenting as a STEMI treated with a drug-eluting stent and 2 as a non-STEMI treated conservatively. One ACS presenter had normal coronaries. Periprocedural complications occurred in 3 patients (16.6%), all ACS presenters. Accordingly, 3 out of 6 HHT patients (50%) undergoing CA in the context of an ACS had a major periprocedural complication, 2 of which occurred during PCI.

The first patient, a 67-year old man presenting with unstable angina, experienced a type-D dissection with a spiral luminal filling defect during PCI of the right coronary artery, which was treated with a bare-metal stent. The second patient, a 73-year old woman, presented with a STEMI and CA showed SCAD with TIMI flow 0 in the LAD. Predilatation with an undersized balloon,

Table

Baseline Characteristics (n = 18)

Age, y	61.6 ± 12.9
Male sex	5 (27.8)
Body mass index	19.6 ± 11.7
Current smoker	6 (33.3)
Hypertension	6 (33.3)
Hyperlipidemia	3 (16.7)
Diabetes mellitus	0 (0.0)
Renal dysfunction	1 (5.6)
Prior coronary artery bypass graft surgery	1 (5.6)
History of myocardial infarction	6 (33.3)
History of stroke	2 (11.1)
Peripheral vascular disease	3 (16.7)

Values are expressed as mean ± standard deviation or No. (%). Renal dysfunction was defined as serum glomerular filtration rate (eGFR) < 60 mL/min/1.73 m².

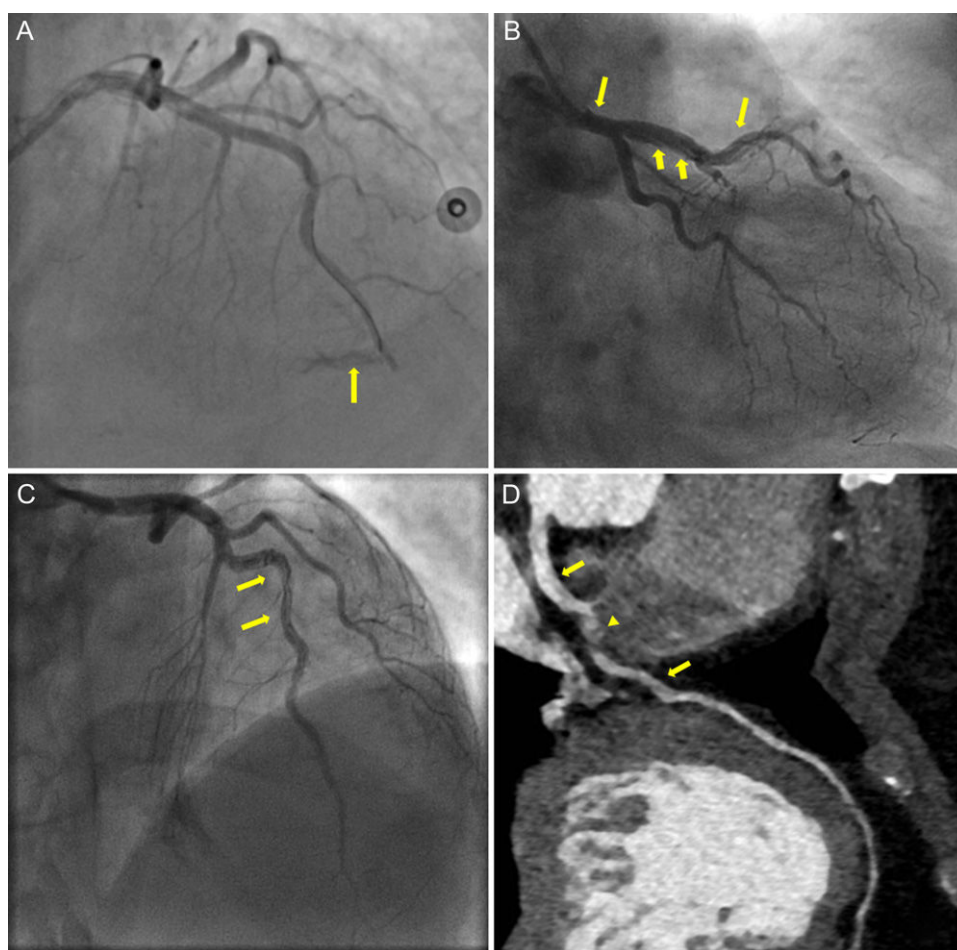


Figure. Coronary angiography showing mid-LAD perforation (panel A, arrow). Dissection flap extending from mid-LAD up to the left main illustrated in CA (panel B, C, arrows) and in computed tomography CA (panel D, arrows), with intramural hematoma causing minimal stenosis in mid-LAD (panel D, arrowhead). CA, coronary angiography; LAD, left anterior descending.

resulted in mid-LAD perforation (Figure A, arrow), which was successfully sealed with prolonged balloon inflation and was subsequently stented with a drug-eluting stent. The patient was treated with aspirin and ticagrelor. A few hours later, she showed massive gastrointestinal and pericardial bleeding leading to death. The third patient, a 47-year old woman, presented with a non-STEMI and urgent CA revealed a SCAD in the mid-LAD. With contrast injections, the dissection propagated retrograde to involve the left main (Figure B and C, arrows). As the patient remained hemodynamically stable, we opted for conservative medical treatment with dual antiplatelet therapy. During follow-up, she was asymptomatic, although a computed tomography CA at 3-months demonstrated a residual intimal flap extending from the left main to mid-LAD (Figure D, arrows) with intramural hematoma causing minimal stenosis in mid-LAD (Figure D, arrowhead).

Our data stress that CA is rarely needed in HHT patients (2.7%). In a population of 1025 HHT patients, Shovlin et al.¹ reported a low rate of myocardial infarction and abnormal CA of 2.2% and < 54%, respectively, while our data demonstrate even lower rates of 0.9% and 27.8%, respectively. Nevertheless, reports have suggested that the underlying coronary anatomy and the

procedural hazards can complicate CA and PCI in these patients.^{2–4} In particular, apart from atherosclerotic lesions, other causes of myocardial infarction have been reported, such as SCAD, endothelial dysfunction, and emboli.^{2–4} In our study, 50% of HHT patients presenting with an ACS had a SCAD. Additionally, 50% of ACS presenters experienced a major periprocedural complication, most of them during PCI.

Endothelial damage in HHT patients is attributed to mutations causing endothelial nitric oxide synthase uncoupling and generation of reactive oxygen species, while impaired transforming growth factor-beta signaling induces cytoskeleton disorganization and fragility of the vessel wall.^{5,6} Vessel wall fragility could be further aggravated by the proinflammatory milieu during an ACS, making HHT patients more vulnerable to complications during urgent CA and PCI. Additionally, such patients bear a substantial bleeding risk associated with PCI antithrombotic treatment and their inherent bleeding predisposition.¹ Additional research is essential to clarify the underlying pathophysiology.

In conclusion, physicians must be alert for periprocedural pitfalls during CA and PCI in HHT patients presenting with an ACS and these should be taken into consideration in decision-making and interventional planning.

Andreas S. Triantafyllis,^{a,*} Andreas S. Kalogeropoulos,^b
Keir McCutcheon,^a Walter Desmet,^a and Johan Bennett^a

^aDepartment of Cardiovascular Medicine, University Hospitals Leuven, Leuven, Belgium

^bDepartment of Cardiology, Barts NHS Trust, London, United Kingdom

*Corresponding author:

E-mail address: andtridoc@yahoo.gr (A.S. Triantafyllis).

Available online 11 November 2017

REFERENCES

1. Shovlin CL, Awan I, Cahilog Z, Abdulla FN, Guttmacher AE. Reported cardiac phenotypes in hereditary hemorrhagic telangiectasia emphasize burdens from arrhythmias, anemia and its treatments, but suggest reduced rates of myocardial infarction. *Int J Cardiol.* 2016;215:179–185. <http://dx.doi.org/10.1016/j.ijcard.2016.04.006>.

- Clark K, Pyeritz RE, Trerotola SO. Angina pectoris or myocardial infarctions, pulmonary arteriovenous malformations, hereditary hemorrhagic telangiectasia, and paradoxical emboli. *Am J Cardiol.* 2013;112:731–734.
- Mieghem CA, Ligthart JM, Cademartiri F. Spontaneous dissection of the left main coronary artery in a patient with Osler-Weber-Rendu disease. *Heart.* 2006;92:195–196.
- Talha S, Brandt C, Maamari G, Mossard JM, Germain P, Andres E. Myocardial infarction in a patient with normal coronary arteries and hereditary haemorrhagic telangiectasia. *QJM.* 2006;99:195–196.
- Jerjic M, Letarte M. Contribution of oxidative stress to endothelial dysfunction in hereditary hemorrhagic telangiectasia. *Front Genet.* 2015;6:. <http://dx.doi.org/10.3389/fgene.2015.00034>.
- Fernández LA, Sanz-Rodríguez F, Blanco FJ, Bernabéu C, Botella LM. Hereditary hemorrhagic telangiectasia, a vascular dysplasia affecting the TGF-beta signaling pathway. *Clin Med Res.* 2006;4:66–78.

<https://doi.org/10.1016/j.rec.2017.10.010>
1885-5857/

© 2017 Sociedad Española de Cardiología. Published by Elsevier España, S.L.U. All rights reserved.

Pulmonary Valve Perforation and Stent Implantation in the Right Ventricle Outflow Tract Using a Hybrid Procedure as an Alternative to a Central Shunt



Perforación de válvula pulmonar e implante de stent en el tracto de salida del ventrículo derecho por procedimiento híbrido como alternativa a la fístula central

To the Editor,

Pulmonary atresia with a ventricular septal defect is a complex congenital condition associated with a poor prognosis in patients with hypoplastic or nonexistent pulmonary branches and large aortopulmonary collateral vessels. In this situation, a staged strategy is preferred to provide pulmonary flow as promptly as possible and achieve growth and development of the pulmonary arteries before corrective surgery is undertaken.¹ The most commonly used traditional palliative surgery techniques were a central systemic-to-pulmonary shunt¹ and placement of a transannular patch or a synthetic conduit between the right ventricle and the pulmonary artery. Later, a percutaneous approach was described, consisting of pulmonary valve perforation by radiofrequency² and stent implantation in the right ventricular

outflow tract, as an alternative to surgery. A hybrid approach is used in low-weight newborns, such as the patient described here.

A term neonate weighing 2.6 kg was diagnosed with a double outlet right ventricle and an unrelated ventricular septal defect, overriding tricuspid valve, and pulmonary atresia, with compensatory circulation through multiple aortopulmonary collateral vessels. The pulmonary trunk and both branches were hypoplastic (trunk, 2.5 mm; branches, 1.3 mm). A central shunt and partial correction were ruled out, and a decision was taken to perform a hybrid procedure consisting of a surgical sternotomy and perforation of the pulmonary valve, with periventricular stent placement. Periventricular puncture of the right ventricle was carried out using a 22-G needle. A 0.018-inch guidewire was inserted, enabling passage of a 5-Fr Cook radial introducer, which was placed just below the pulmonary valve ([Figure A](#) and [video 1 of the supplementary material](#)). Contrast material was injected and minimal antegrade pulmonary flow was observed. Passage of a 0.014-inch Whisper coronary guidewire (Abbot) was achieved and the introducer was then advanced through the dilator. Patency of the pulmonary trunk and branches was verified. A premounted 6 × 16-mm Formula stent (Cook) was then implanted in the pulmonary valve. The procedure was successful, achieving adequate perfusion of the pulmonary tree and showing hypoplasia of the left pulmonary branch ([Figure B](#)

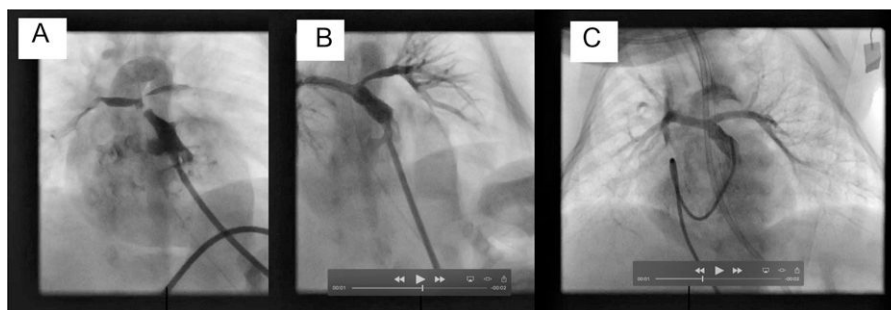


Figure. A, Right ventriculogram with cranial angulation in the posteroanterior view shows minimal antegrade pulmonary flow and the confluence of the trunk and the hypoplastic pulmonary branches. B, Pulmonary arteriogram with cranial angulation in the posteroanterior view depicts correct stent placement and adequate perfusion of both pulmonary branches, although with hypoplasia of the left pulmonary branch. C, The posteroanterior pulmonary arteriography image with cranial angulation at the second catheterization shows that both pulmonary branches have grown and there is adequate perfusion of the lung segments.