

domized to either fractional flow reserve-guided complete revascularization or no revascularization of noninfarct-related arteries. The patients assigned to the fractional flow reserve-guided complete revascularization had lower incidence of the primary composite end point of cardiovascular death, myocardial infarction, stroke, or repeat revascularization (8% vs 21%; HR = 0.35; 95%CI, 0.22–0.55; $P < .001$), largely due to the variable new revascularization, defined as urgent revascularizations at any time or elective revascularizations performed within 45 days.

Roberto Martín-Asenjo,^{a,*} Jaime Aboal,^b Josep Masip,^c Esteban López de Sá,^d and Alessandro Sionis^e

^aServicio de Cardiología, Hospital 12 de Octubre, Madrid, Spain

^bServicio de Cardiología, Hospital Universitario Doctor Josep Trueta, Girona, Spain

^cServicio de Cardiología, Hospital Sanitas CIMA, Barcelona; Servei de Medicina Intensiva, Consorci Sanitari Integral, Universitat de Barcelona, Barcelona, Spain

^dUnidad Coronaria, Servicio de Cardiología, Hospital Universitario La Paz, Madrid, Spain

^eUnidad de Cuidados Agudos Cardiológicos, Hospital de la Santa Creu i Sant Pau, IIB-Sant Pau, CIBER-CV, Universidad Autónoma de Barcelona, Barcelona, Spain

*Corresponding author:

E-mail address: robertomartinassenjo@gmail.com

(R. Martín-Asenjo).

Available online 6 December 2017

REFERENCES

1. Sabatine MS, Giugliano RP, Keech AC, et al. Evolocumab and clinical outcomes in patients with cardiovascular disease. *N Engl J Med*. 2017;376:1713–1722.
2. Eikelboom JW, Connolly SJ, Bosch J, et al. Rivaroxaban with or without aspirin in stable cardiovascular disease. *N Engl J Med*. 2017. <http://dx.doi.org/10.1056/NEJMoa1709118>. Consultado 31 Ago 2017.
3. Ridker PM, Everett BM, Thuren T, et al. Antiinflammatory therapy with canakinumab for atherosclerotic disease. *N Engl J Med*. 2017. <http://dx.doi.org/10.1056/NEJMoa1707914>. Consultado 31 Ago 2017.
4. Boeddinghaus J, Nestelberger T, Twerenbold R, et al. Direct comparison of 4 very early rule-out strategies for acute myocardial infarction using high-sensitivity cardiac troponin I. *Circulation*. 2017;135:1597–1611.
5. Jobs A, Mehta SR, Montalescot G, et al. Optimal timing of an invasive strategy in patients with non-ST-elevation acute coronary syndrome: a meta-analysis of randomised trials. *Lancet*. 2017;390:737–746.
6. Smits PC, Abdel-Wahab M, Neumann FJ, et al. Fractional flow reserve-guided multivessel angioplasty in myocardial infarction. *N Engl J Med*. 2017;376:1234–1244.

SEE RELATED CONTENT:

<http://dx.doi.org/10.1016/j.rec.2017.10.034>

<http://dx.doi.org/10.1016/j.rec.2017.10.033>

1885-5857/

© 2017 Sociedad Española de Cardiología. Published by Elsevier España, S.L.U. All rights reserved.

Selection of the Best of 2017 in Cardiac Imaging and Structural Interventionism



Selección de lo mejor del año 2017 en imagen cardiovascular en el intervencionismo estructural

To the Editor,

The number and type of percutaneous catheterization techniques used for structural heart disease have exponentially increased in recent years. Diverse imaging techniques play fundamental roles before, during, and after these procedures.^{10.1016/j.recesp.2017.10.003}

For transcatheter aortic valve implantation (TAVI), 2017 began with the publication of the 5-year echocardiographic follow-up of the PARTNER-I study,¹ which confirmed the mid-to-long-term durability and stability of hemodynamic parameters after this procedure. Computed tomography (CT) continues to show superior reproducibility and ability to determine prosthesis size and the degree of its oversizing. In addition, during the postimplantation follow-up, CT is essential for detecting subclinical prosthetic thrombosis (areas of hypoattenuation in the prosthetic cusps), with an approximate incidence of 14.3%, which was not associated with increased prosthetic gradients or embolic events.

The field of percutaneous mitral valve interventions is expanding to include new devices aimed at repairing the valve using neo-chord implantation, rings, and edge-to-edge plication, together with the development of percutaneous mitral prostheses. The role of imaging in indication evaluation and monitoring has been strengthened. Publications from 2017 were oriented at identifying prognostic indicators based on percutaneous repair outcomes. A notable work by Neuss et al.² reported worse 2-year vital prognosis for patients with a mean residual gradient > 4.4 mmHg by echocardiography (or 5 mmHg using invasive measurement), with a significant difference in the number of

clips implanted per patient (1.3 vs 1.5 in the stenotic group). Regarding tricuspid valve interventions, the year began with multiple new repair systems and promising results. Because echocardiographic analysis of the tricuspid valve is poorly established, various groups have published recommendations on imaging analysis of the so-called forgotten valve. Another standout is the work by Hahn,³ with an excellent interventional cardiology-focused evaluation of the functional anatomy of the tricuspid valve.

Regarding periprosthetic leaks, an expert consensus was published in 2017 that includes recommendations for the quantification and characterization of periprosthetic leaks with multimodality imaging.⁴ In addition, the results were presented of a real-life Spanish clinical practice registry that shows the reliability and safety of the procedure.

In the field of left atrial appendage closure, one particularly pertinent article used various imaging techniques to show a significant intraprocedural increase in atrial appendage size after volume loading, with 3-dimensional echocardiography the most accurate technique for gauging the correct size of the device.⁵ In addition, prospective data from clinical practice, with more than 1000 patients treated with the Amulet device and 3-month echocardiographic follow-up in more than half of the patients, revealed a high rate of appendage occlusion (98.2%) with low rates of device thrombus (1.5%) in follow-up.

For percutaneous closure of the patent foramen ovale, the main contribution in 2017 has been the presentation of the preliminary results of the GORE-REDUCE study (NCT00738894), which showed the superiority of percutaneous occlusion over medical treatment in secondary prevention for patients younger than 60 years with septal aneurysm and a large defect, with echocardiography used to select ideal candidates. These results will probably be incorporated into the next guidelines.

Regarding congenital heart diseases, recommendations were published in 2017 on the value of 3-dimensional echocardiogra-

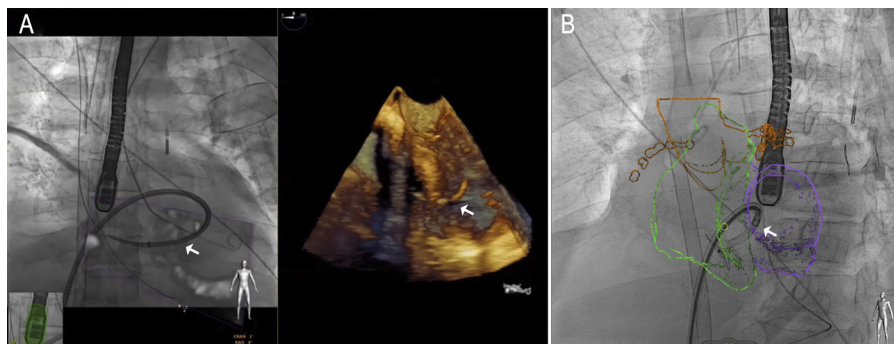


Figure. Example of fusion imaging with echocardiography (A) and computed tomography (B) during percutaneous occlusion of a postinfarction interventricular communication. Note the sheath passing through the defect.

phy,⁶ found to be particularly useful in the study and closure of abnormal and multiple communications or residual defects after surgery.

Good results in structural catheterization can be obtained with precise monitoring of the procedure. In contrast, the use of a transesophageal probe for more than 60 minutes has been associated with an increase in oropharyngeal lesions, which may be indicated by an increased peripheral blood leukocyte count. A promising alternative is the transnasal probe, which, in addition to avoiding the need for general anesthesia, has shown good anatomical quality in various procedures. Fusion imaging (Figure) also safely reduces the procedural time and has become the best approach for transseptal puncture; for atrial appendage closure, fusion imaging with CT has also been shown to reduce the procedural contrast volume and time. Another emerging technology, especially suited to preprocedural planning, is 3-dimensional printing. Various articles have reported its ability to predict residual leaks after TAVI, test the safety of novel procedures, take accurate measurements and reduce the radiation dose in atrial appendage closure, and print material with different textures in the mitral valve field.

Manuel Barreiro-Pérez,^{a,*} Chi Hion Li,^b Dolores Mesa,^c Covadonga Fernandez-Golfín,^d Teresa López-Fernández,^e and Leopoldo Pérez de Isla^f

^aServicio de Cardiología, Complejo Asistencial Universitario de Salamanca, IBSAL, CIBERCV, Salamanca, Spain

^bServicio de Cardiología, Hospital de la Santa Creu i Sant Pau, IIB-SantPau, CIBERCV, Universidad Autónoma de Barcelona, Barcelona, Spain

^cServicio de Cardiología, Hospital Reina Sofía, Córdoba, Spain

^dServicio de Cardiología, Hospital Ramón y Cajal, Instituto Ramón y Cajal de Investigación Sanitaria IRYCIS, CIBERCV, Madrid, Spain

^eServicio de Cardiología, Hospital Universitario La Paz, IdiPaz, CIBERCV, Madrid, Spain

^fServicio de Cardiología, Instituto Cardiovascular, Hospital Clínico San Carlos, IdISSC, Universidad Complutense, Madrid, Spain

* Corresponding author:

E-mail address: manuelbarreiroper@gmail.com (M. Barreiro-Pérez).

Available online 21 December 2017

BIBLIOGRAFÍA

1. Daubert MA, Weissman NJ, Hahn RT, et al. Long-term valve performance of TAVR and SAVR. A report from the PARTNER I trial. *J Am Coll Cardiol Img.* 2017;10:15–25.
2. Ruiz CE, Hahn RT, Berrebi A, et al. Paravalvular Leak Academic Research Consortium. Clinical trial principles and endpoint definitions for paravalvular leaks in surgical prosthesis: an expert statement. *J Am Coll Cardiol.* 2017;69:2067–2087.
3. Neuss M, Schau T, Isotani A, et al. Elevated mitral valve pressure gradient after MitraClip implantation deteriorates long-term outcome in patients with severe mitral regurgitation and severe heart failure. *JACC Cardiovasc Interv.* 2017;10:931–939.
4. Hahn RT. State-of-the-art review of echocardiographic imaging in the evaluation and treatment of functional tricuspid regurgitation. *Circ Cardiovasc Imaging.* 2016;9:e005332.
5. Al-Kassou B, Tzikas A, Stock F, et al. A comparison of two-dimensional and real-time 3 D transoesophageal echocardiography and angiography for assessing the left atrial appendage anatomy for sizing a left atrial appendage occlusion system: impact of volume loading. *EuroIntervention.* 2017;12:2083–2091.
6. Simpson J, Lopez L, Acar P, et al. Three-dimensional echocardiography in congenital heart disease: an expert consensus document from the European Association of Cardiovascular Imaging and the American Society of Echocardiography. *Eur Heart J Cardiovasc Imaging.* 2016;7:1071–1097.

SEE RELATED CONTENT:

<http://dx.doi.org/10.1016/j.rec.2017.10.051>

<http://dx.doi.org/10.1016/j.rec.2017.10.036>

1885–5857/

© 2017 Sociedad Española de Cardiología. Published by Elsevier España, S.L.U. All rights reserved.

Selection of the Best of the Year 2017 in Cardiovascular Imaging in Familial Cardiopathies

Selección de lo mejor del año 2017 en imagen cardiovascular en las cardiopatías familiares

To the Editor,

The use of cardiovascular imaging techniques (CVIT) in clinical processes in the context of inherited cardiac conditions (ICC)



presents specific opportunities and challenges in a clinical scenario marked by ever-changing understanding of their biology, the speed of technological development, and the need to adapt to the different social, economic, and health characteristics of each population.

The availability of different CVITs for approaching the same clinical problem can make it difficult to choose the most appropriate technique. A consensus document from several North American societies aims to present, in a structured way, the appropriate use criteria for the various CVITs in primary and secondary valvular heart disease in patients with ICC.¹ However,