

atrioventricular block inherent to peri-Hisian ablation via the atria. Therefore, our group systematically maps the aortic root in cases of AT in which the earliest right atrial activation site is posterior or superior to the bundle of His. The originality of the case presented here lies in the recent implantation of an aortic prosthesis as the possible trigger of the AT, which, to the best of our knowledge, has not been previously described in the literature. Because of this, we attempted ablation from the right atrium before mapping the aortic root. We did not map the left interatrial septum, which we could have considered, given the low efficacy that has been reported on ablation from this location (25%–64%)^{5,6} and the sufficient distance from the earliest atrial electrogram in the aortic root to the prosthesis, which made the ablation safe (Figure 2).

In our hospital, since 2014, 46 patients have undergone focal AT ablations (Figure of the supplementary material); 11 had AT of peri-Hisian origin and were treated with ablation from the aortic root (all from a noncoronary sinus). These patients had similar acute success rates for ablation (100% vs 91%; $P = .431$) but fewer recurrences of atrial arrhythmias at follow-up (0% vs 26%; $P = .009$) than patients with AT of other origins.

CONFLICTS OF INTEREST

E. Franco and J. Moreno have received consultancy fees from Biosense Webster.

SUPPLEMENTARY MATERIAL



Supplementary material associated with this article can be found in the online version available at <https://doi.org/10.1016/j.rec.2018.06.001>.

Eduardo Franco,^{a,*} Daniel Rodríguez Muñoz,^a Roberto Matía Francés,^a Antonio Hernández-Madrid,^a Inmaculada Sánchez Pérez,^b and Javier Moreno^a

^aServicio de Cardiología, Hospital Universitario Ramón y Cajal, Madrid, Spain

^bServicio de Cardiología Infantil, Hospital Universitario Ramón y Cajal, Madrid, Spain

* Corresponding author:

E-mail address: efranco@academiamir.com (E. Franco).

Available online 2 July 2018

REFERENCES

1. Beukema RJ, Smit JJ, Adiyaman A, et al. Ablation of focal atrial tachycardia from the non-coronary aortic cusp: case series and review of the literature. *Europace*. 2015;17:953–961.
2. Fontenla A, García-Fernández J, Ibáñez JL; Spanish Catheter Ablation Registry collaborators. Spanish Catheter Ablation Registry. 16th Official Report of the Spanish Society of Cardiology Working Group on Electrophysiology and Arrhythmias (2016). *Rev Esp Cardiol*. 2017;70:971–982.
3. Yanni J, Boyett MR, Anderson RH, Dobrzynski H. The extent of the specialized atrioventricular ring tissues. *Heart Rhythm*. 2009;6:672–680.
4. Toniolo M, Rebellato L, Poli S, Daleffe E, Proclemer A. Efficacy and safety of catheter ablation of atrial tachycardia through a direct approach from noncoronary sinus of Valsalva. *Am J Cardiol*. 2016;118:1847–1854.
5. Lyan E, Toniolo M, Tsyganov A. Comparison of strategies for catheter ablation of focal atrial tachycardia originating near the His bundle region. *Heart Rhythm*. 2017;14:998–1005.
6. Pap R, Makai A, Szilágyi J, et al. Should the aortic root be the preferred route for ablation of focal atrial tachycardia around the AV node? Support from intracardiac echocardiography. *JACC Clin Electrophysiol*. 2016;2:193–199.

<https://doi.org/10.1016/j.rec.2018.06.001>
1885–5857/

© 2018 Sociedad Española de Cardiología. Published by Elsevier España, S.L.U. All rights reserved.

Functional and Structural Coronary Recovery at the 5-year Follow-up After Bioresorbable Vascular Scaffold Implantation. An Optical Coherence Tomography Analysis



Recuperación estructural y funcional tras 5 años del implante de armazón vascular bioabsorbible. Un análisis con tomografía de coherencia óptica

To the Editor,

The bioresorbable everolimus-eluting vascular scaffold (Absorb-BVS, Abbott-Vascular; California, USA), designed to reduce late complications of bare-metal stents, received the CE mark in 2011 and became available in Europe in 2012. Although the initial results were promising, recent studies have brought into question the safety of the device due to a high incidence of thrombosis and infarction.¹ However, little has been said about the resorption of the device or the structural and functional recovery of the vessel in patients in real-life clinical practice.

We present a single-center prospective cohort study that examined the structure and function of the coronary arteries after Absorb-BVS implantation, using angiography, optical coherence tomography (OCT), and quantitative flow ratio (QFR) in a consecutive series of patients with 5 years of follow-up. The coronary arteries were assessed retrospectively with 3-dimensional reconstruction angiography (QAngio XA-3D research edition 1.0, Medis Special BV; the Netherlands) and OCT images were

obtained with Dragonfly catheter at 180 cps and 18 mm/s (C7Fourier-Domain System, LightLab-Imaging, Inc.).

OCT analysis (of the treated segment and 5 mm adjacent) was performed with LightLab software at 1 mm intervals (Abbott; Abbott Park, USA). The markers on the Absorb-BVS, angiography, and anatomical references were used to locate the treated segment. The morphological aspects studied were: resorption of the device, lumen area, asymmetry index, eccentricity index, residual stenosis area, neointimal thickness, minimum plaque thickness, and side branch ostia.² These parameters were also reassessed after the intracoronary administration of 200 µg of glyceryl trinitrate as part of the functional study.

Data were analyzed with the chi-squared test and Fisher exact test (categorical variables) and with the Student *t* test for paired data (continuous variables). The Shapiro-Wilk test confirmed normality. $P \leq .05$ was considered statistically significant and the analyses were performed with IBM-SPSS-23.0.

Eleven Absorb-BVS were analyzed in 9 patients. Mean age was 70 ± 8 years, 89% were male, acute coronary syndrome was reported in 78% of cases, and the most commonly treated artery was the left anterior descending (64%) with a type B2-C lesion (American Heart Association/American College of Cardiology) in 46%. Predilatation was performed in 91% and postdilatation in 55%. Although there were no complications during implantation, 1 patient had restenosis in the distal right coronary artery after 6 months (underexpansion of the 2.5×18 mm Absorb-BVS), and was treated, ultimately, with a drug-eluting stent.

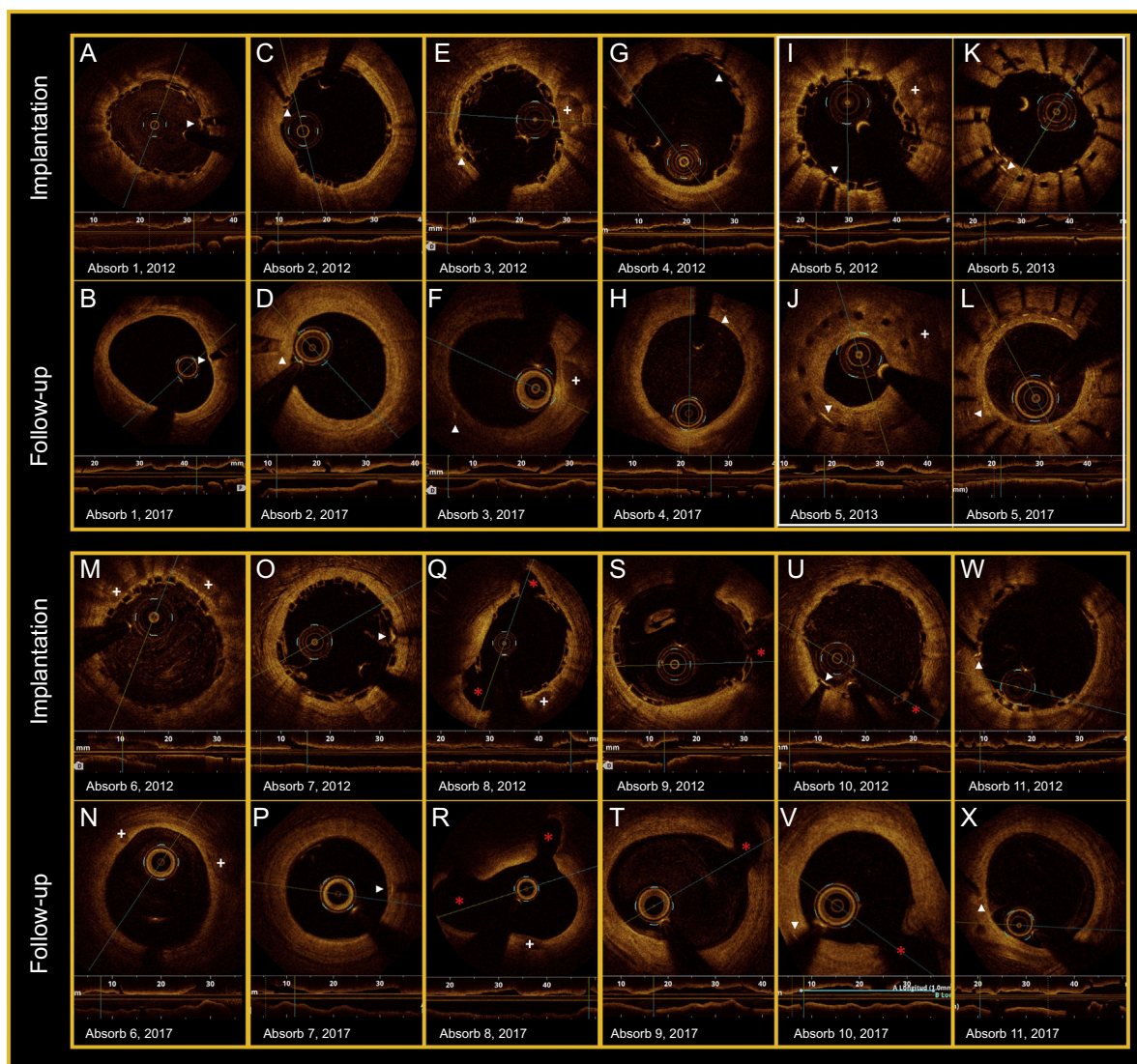


Figure. All panels show the OCT findings (implantation-follow-up). The white arrows indicate the radiopaque markers on the Absorb-BVS. The white crosses indicate plaques and calcium nodules. The red asterisks mark the lateral branches. I-L: severe restenosis of the Absorb-BVS (6 months), which was treated with a drug-eluting stent (2013) without compromising resorption (2017). OCT, optical coherence tomography.

Table
OCT Findings in Patients Treated With Absorb-BVS After 5 Years of Follow-up

Morphological study	2012	2017	P
Variables studied	After implantation, n (11)	At follow-up, n (11)	
Minimum lumen area, mm ²	7.50 ± 1.48	4.52 ± 1.25	< .001
Mean lumen area, mm ²	8.84 ± 1.60	6.64 ± 2.19	< .001
Mean lumen diameter, mm	3.33 ± 0.31	2.86 ± 0.46	< .001
Eccentricity index	0.84 ± 0.02	0.87 ± 0.04	< .001
Asymmetry index	0.35 ± 0.09	0.39 ± 0.1	.204
Residual stenosis area, %	-2.21 ± 18.24	30.62 ± 14.61	< .001
Number of struts identified	2119	0	
Malapposed struts	65 (3.1)	n/a	
Malapposition distance, μm	120.7 ± 65.37	n/a	
Mean Absorb-BVS area, mm ²	-7.41 ± 1.55	n/a	
MFCT within treated segment, μm	80.85 ± 21.89	159.67 ± 74.20	.012
Coronary plaques in treated segment	271	257	< .001
MFCT < 65 μm within treated segment	153 (56.5)	43 (16.7)	
MFCT in reference segment, μm	82.77 ± 39.72	121.02 ± 96.78	.336
Coronary plaques in reference segment	52	79	.770
MFCT < 65 μm in reference segment	29 (55.8)	42 (53.2)	

Table (Continued)

OCT Findings in Patients Treated With Absorb-BVS After 5 Years of Follow-up

Morphological study	2012	2017	
Variables studied	After implantation, n (11)	At follow-up, n (11)	P
Functional study	2017s		
<i>Variables studied</i>	Pre-GTN	Post-GTN	
Minimum lumen area, mm ²	4.83 ± 1.12	4.82 ± 1.22	.887
Mean lumen area, mm ²	7.44 ± 1.38	7.55 ± 1.26	.490
Mean lumen diameter, mm	3.04 ± 0.29	3.07 ± 0.26	.500
Eccentricity index	0.87 ± 0.03	0.87 ± 0.04	.701
Asymmetry index	0.38 ± 0.11	0.42 ± 0.12	.523
Residual stenosis area, %	27.63 ± 16.9	28.07 ± 18.5	.854

GTN, glyceryl trinitrate; MFCT, minimum fibrous cap thickness; OCT, optical coherence tomography. Values are presented as No. (%) or mean ± standard deviation.

The functional impact of each lesion was evaluated at baseline with quantitative flow ratio, and after implantation a mean 0.59 ± 0.15 was obtained. The mean diameter obtained after implantation was 0.32 mm greater than the reference diameter. Late lumen loss was $18.7 \pm 21\%$ after 5 years' follow-up. After implantation, 119 struts were identified on OCT, but none were identified at follow-up (Figure 1). The main changes found in the lumen area, diameter, and morphology are presented in Table 1.

The mean distance from the lumen edge of the markers to the endothelium (neointimal growth) was $-134.7 \pm 30.6 \mu\text{m}$ after implantation and $213.5 \pm 112.4 \mu\text{m}$ at follow-up. Regarding atherosclerotic plaques, 271 were identified after implantation and 257 at 5 years; an increase in minimum fibrous cap thickness was recorded, from $80.85 \pm 21.89 \mu\text{m}$ to $159.67 \pm 74.2 \mu\text{m}$ ($P = .012$) and there was a reduction in the percentage of vulnerable plaques ($< 65 \mu\text{m}$), from 56.5% to 16.7%, respectively.

Angiographic and OCT analysis revealed that jailed branches remained patent after 5 years with various types of neointimal bridges. The vasodilation test with glyceryl trinitrate did not produce significant changes in the variables analyzed on OCT (Table 1).

In summary, after 5 years of follow-up, we observed: a) complete resorption of the Absorb-BVS scaffolds, neointimal development (golden-tube appearance) and stabilization of vulnerable plaques; b) progressive changes in the lumen area and concentricity, and c) absence of vasodilatation after intracoronary administration of glyceryl trinitrate.

Although the morphological findings are comparable to those found in previous studies, the absence of coronary vasoreactivity differs from the results described in the Absorb trials,^{3,4} which may have clinical and prognostic effects.⁵ Thus, while the angiographic assessment of coronary vasomotion may have been subjective, quantification of the lumen area and diameter with OCT is an objective parameter. The authors acknowledge the small sample size and the consequent inability to detect complications such as late thrombosis or neoatherosclerosis. Furthermore, the lack of data on the intermediate phases of the resorption process means that we cannot rule out the possibility that changes occurred in the arterial wall or in the BVS, such as coronary evaginations or strut fracture.⁶ Finally, although the reduction in lumen area could be due to the sample size and the coronary vasoreactivity test was not compared with healthy coronary segments, this is the first study that reports structural and functional findings in patients in real clinical practice treated with Absorb-BVS after 5 years of follow-up and may represent the first step toward further studies in the area.

CONFLICTS OF INTEREST

The institution received an unconditional grant from Abbott Vascular to conduct the REPARA and REPARA-QALY studies.

Luis R. Goncalves-Ramírez,^{a,*} Hipólito Gutiérrez,^{a,b} Carlos Cortés,^a Itziar Gómez,^a José A. San Román,^{a,b} and Ignacio J. Amat-Santos^{a,b}

^aCentro de Investigación Biomédica en Red Enfermedades Cardiovasculares (CIBERCV), Hospital Clínico Universitario, Valladolid, Spain

^bHemodinámica y Cardiología Intervencionista, Instituto de Ciencias del Corazón, Hospital Clínico Universitario, Valladolid, Spain

* Corresponding author:

E-mail address: luisrenier@hotmail.com (L.R. Goncalves-Ramírez).

Available online 7 July 2018

REFERENCES

- Onuma Y, Dudek D, Thuesen L, et al. Five-year clinical and functional multislice computed tomography angiographic results after coronary implantation of the fully resorbable polymeric everolimus-eluting scaffold in patients with de novo coronary artery disease: the ABSORB cohort A trial. *JACC Cardiovasc-Interv.* 2013;6:999–1009.
- Suwannasom P, Sotomi Y, Asano T, et al. Change in lumen eccentricity and asymmetry after treatment with Absorb bioresorbable vascular scaffolds in the ABSORB cohort B trial: a five-year serial optical coherence tomography imaging study. *EuroIntervention.* 2017;12:e2244–e2252.
- Serruys PW, Onuma Y, Garcia-Garcia HM, et al. Dynamics of vessel wall changes following the implantation of the absorb everolimus-eluting bioresorbable vascular scaffold: a multi-imaging modality study at 6, 12, 24 and 36 months. *EuroIntervention.* 2014;9:1271–1284.
- Simsek C, Karanasos A, Magro M, et al. Long-term invasive follow-up of the everolimus-eluting bioresorbable vascular scaffold: five-year results of multiple invasive imaging modalities. *EuroIntervention.* 2016;11:996–1003.
- De la Torre Hernandez JM, Rumoroso JR, Ojeda S, et al. Angina and ischemia at 2 years with bioresorbable vascular scaffolds and metallic drug-eluting stents. ESTROFA Ischemia BVS-mDES Study. *Rev Esp Cardiol.* 2018;71:327–334.
- Gori T, Jansen T, Weissner M, et al. Coronary evaginations and peri-scaffold aneurysms following implantation of bioresorbable scaffolds: incidence, outcome, and optical coherence tomography analysis of possible mechanisms. *Eur Heart J.* 2016;37:2040–2049.

<https://doi.org/10.1016/j.rec.2018.04.026>

1885–5857/

© 2018 Sociedad Española de Cardiología. Published by Elsevier España, S.L.U. All rights reserved.