

Image in cardiology

Atrial appendage closure hampered by an anomalous band

Cierre percutáneo de orejuela dificultado por tendón accesorio

María Elena Tundidor-Sanz, Manuel Barreiro-Perez,* and Ignacio Cruz-González

Servicio de Cardiología, Complejo Asistencial Universitario de Salamanca, Instituto de Investigación Biomédica de Salamanca (IBSAL), CIBER-CV, Salamanca, Spain

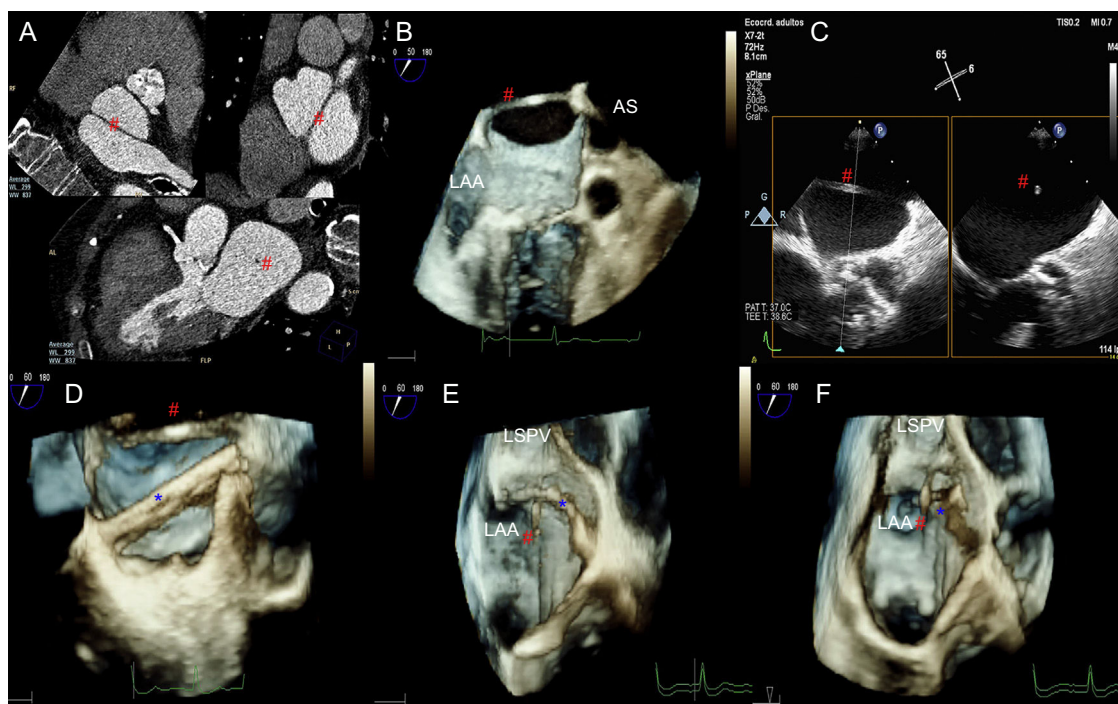


Figure 1.

Percutaneous closure of the left atrial appendage (LAA) was indicated in an 83-year-old woman with intestinal bleeding who was receiving anticoagulation therapy for atrial fibrillation. Initial study with computed tomography ruled out thrombosis and determined the size of the device to be implanted. An anomalous band (#) was detected in the left atrium as an incidental finding. The band was anchored to the central position of the atrial septum (AS) and the ostium of the left superior pulmonary vein (LSPV). An isolated avascular structure with a circular section was also detected (Figure 1A). Transeptal puncture was performed with transesophageal echocardiography (TEE) monitoring (Figure 1B and C). The guide was advanced toward the LSPV before being exchanged for a sheaf (Figure 1D, *). During withdrawal, superimposition of the band and catheter prevented coaxial advancement toward the left appendage. Three-dimensional TEE enabled early detection of this situation (Figure 1E) and monitoring of the necessary movements to advance below the band without interference (Figure 1F and video in the additional material). The Amulet device no. 28 (St Jude Medical) was finally released without complications.

The presence of an atrial anomalous band is an uncommon finding (present in 2% of autopsies) and is usually associated with coexistence of a Chiari network, foramen ovale, or connection with the mitral apparatus. The presence of this structure may hamper or even contraindicate transeptal puncture. Detailed prior study and the use of 3-dimensional TEE during the procedure enables anticipation and resolution of complications resulting from anomalous structures. To our knowledge, this is the first description of a percutaneous procedure hampered by an atrial anomalous band.

APPENDIX. SUPPLEMENTARY DATA

Supplementary data associated with this article can be found in the online version, at <https://doi.org/10.1016/j.rec.2018.10.015>.

* Corresponding author:

E-mail address: manuelbarreiroper@gmail.com (M. Barreiro-Perez).

Available online 18 January 2019

<https://doi.org/10.1016/j.rec.2018.10.015>

1885-5857/© 2018 Sociedad Española de Cardiología. Published by Elsevier España, S.L.U. All rights reserved.