

Long-term outcomes of aortic valve reimplantation in Marfan syndrome



Resultados a largo plazo en la preservación valvular aórtica en el síndrome de Marfan

To the Editor,

The prognosis of Marfan syndrome (MS) is principally determined by aortic involvement (especially affecting the aortic root), which is the most common cause of death and reduced life expectancy in MS patients.

The classic standard treatment for aortic root aneurysm is root replacement with a valved conduit (the Bentall procedure); however, the complications inherent in the use of prosthetic valves¹ has driven the development of techniques for aortic root replacement that preserve the aortic valve, and aortic valve reimplantation has shown excellent short- and long-term results.² Nevertheless, the use of this method in MS patients remains controversial due to the small number of cases, the short follow-up, and the uncertain long-term stability and functioning of the repaired aortic root.

We analyzed long-term survival and the rates of reoperation and recurrent aortic regurgitation (AoR) > grade II among MS patients undergoing valve-sparing aortic root repair at our center.

Between March 2004 and June 2018, 134 patients diagnosed with MS according to clinical criteria and genetic analysis underwent aortic valve reimplantation (the David procedure) (Table 1). Surgery was indicated for emergency repair of type A aortic dissection or as an elective intervention in patients with an aortic root diameter ≥ 50 mm or ≥ 45 mm in the presence of risk factors.¹ In 35 patients, aortic valve reimplantation was combined with other aortic repair techniques, and 18.7% of patients also required other cardiac procedures. In-hospital mortality was 0%. Mean follow-up was 6.2 ± 3.9 years, with an annual echocardiography examination and computed tomography or magnetic resonance every 2 years. All patients were periodically assessed at our Marfan unit.

Survival at 1 year was 100% and remained high at 5 and 10 years ($99\% \pm 1\%$ and $97.1\% \pm 2\%$, respectively) (Figure 1). During follow-up, moderate or severe AoR developed in 7 patients (5.4%), 3 of whom underwent reintervention, mild AoR developed in 9 patients, and AoR was trivial or absent in the rest of the study population. Of 17 patients with a postoperative valve leaflet coaptation height ≤ 7 mm, 3 (18%) developed significant AoR (\geq grade II), and poor leaflet coaptation was the only predictor of significant postoperative AoR (hazard ratio [HR], 1.9; $P = .02$). Freedom from significant AoR at 1, 5, and 10 years postintervention was $99.1\% \pm 0.8\%$, $94.4\% \pm 2.2\%$, and $92.7\% \pm 2.5\%$, respectively; freedom from reoperation at the same follow-up times was $99.1\% \pm 1\%$, $97\% \pm 2\%$, and $97\% \pm 2\%$ (Figure 1).

At end follow-up, there were no recorded incidences of endocarditis or stroke, and more than 97% of the patients were not receiving anticoagulant therapy and were in a normal functional class.

Authors from centers experienced in aortic valve reimplantation have reported very low in-hospital mortality after valve-sparing aortic root repair ($< 2\%$).^{3,4} In our series, there was no in-hospital mortality, and 10-year mortality was 2.9%. This is significantly lower than the rate reported for aortic root replacement with a valved conduit.⁵

A central goal of all aortic valve conservation techniques is long-term stability. In the longest follow-up study to date, David et al.³ analyzed data from 333 patients (37.2% with MS), reporting 20-year rates for freedom from significant AoR and reoperation of $96.2\% \pm 1.0\%$ and $96.9\% \pm 1.3\%$, respectively. In another center with extensive experience in this surgical procedure, 10-year freedom

Table 1

Preoperative Clinical Characteristics and Echocardiography Parameters.

	Patients (N = 134)
Age, y	33.4 \pm 12.3
Sex	
Men	89 (66.4)
Women	45 (33.6)
Surgical indication	
Elective	131 (97.9)
Emergency	3 (2.1)
NYHA functional class	
I	124 (92.5)
II	9 (6.7)
III	1 (0.7)
IV	0
Type A acute aortic dissection	3 (2.1)
Diabetes mellitus	6 (4.5)
Hypertension	10 (7.5)
Dyslipidemia	9 (6.7)
LVEF	
> 55%	124 (92.5)
35-55%	9 (6.7)
< 35%	0
LV diameter	
Normal	123 (91.8)
Moderate dilation	9 (6.7)
Severe dilation	2 (1.5)
Bicuspid aortic valve	7 (5.2)
Aortic regurgitation	
0	98 (73.1)
1	16 (11.9)
2	12 (9)
3	7 (5.2)
4	1 (0.7)
Aortic annulus diameter, mm	27.1 \pm 2.9
Sinus of Valsalva diameter, mm	49.1 \pm 4.9
Ascending aorta diameter, mm	29.7 \pm 8.5
Mitral regurgitation > 2	15 (11.2)

LV, left ventricle; LVEF, left ventricular ejection fraction; NYHA, New York Heart Association.

Data are expressed as no. (%) or mean \pm standard deviation

from reoperation was $> 90\%$.⁴ In our series, the 10-year rates of significant AoR and reoperation were 7.3% and 3.8%, respectively.

Nevertheless, achieving correct coaptation sometimes requires direct repair of the aortic valve. In our series, 30.6% of the patients required procedures to repair the valve leaflets during aortic valve reimplantation. Detailed analysis of preoperative and intraoperative echocardiograms is thus essential to determine the cause of the AoR and to ensure correct initial repair and long-term stability.

In line with our results, several authors have identified valve prolapse and particularly a postoperative leaflet coaptation height < 8 mm as independent predictors of long-term significant AoR and reoperation.⁶ There is thus an evident need to confirm optimal aortic root geometry and proper leaflet configuration after aortic valve reimplantation in order to reduce the risk of valve prolapse and subsequent mid-term and long-term AoR.

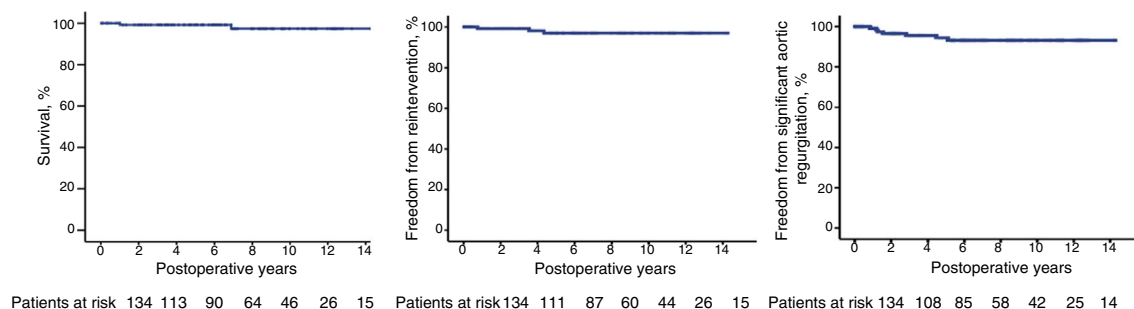


Figure 1. Patient survival and freedom from reoperation and significant aortic regurgitation.

Valve-sparing aortic root repair by the David procedure provides excellent long-term clinical and functional results and should therefore be the gold standard treatment for aortic root aneurysm in MS.

Carlos E. Martín,^{a,*} Susana Villar,^a Santiago Serrano-Fiz,^a Vanessa Moñivas,^b Ana González,^c and Alberto Forteza^a

^aServicio de Cirugía Cardíaca, Hospital Universitario Puerta de Hierro, Madrid, Spain

^bServicio de Cardiología, Hospital Universitario Puerta de Hierro, Madrid, Spain

^cServicio de Anestesiología, Hospital Universitario Puerta de Hierro, Madrid, Spain

* Corresponding author:

E-mail address: carlosestebanmartin@hotmail.com (C.E. Martín).

Available online 25 September 2019

REFERENCES

- Baumgartner H, Alfieri O, Falk V, et al. Guía ESC/EACTS 2017 sobre el tratamiento de las valvulopatías. Grupo de Trabajo de la Sociedad Europea de Cardiología (ESC) y de la European Association for Cardio-Thoracic Surgery (EACTS). *Rev Esp Cardiol.* 2018;71:110e1–1147e.
- David TE, Feindel CM. An aortic valve-sparing operation for patients with aortic incompetence and aneurysm of the ascending aorta. *J Thorac Cardiovasc Surg.* 1992;103:617–621.
- David TE, David CM, Feindel CM, Manlhiot C. Reimplantation of aortic valve at 20 years. *J Thorac Cardiovasc Surg.* 2017;153:232–238.
- Martens A, Beckmann E, Kaufeld T, et al. Valve-sparing aortic root replacement (David I procedure) in Marfan disease: single-centre 20-year experience in more than 100 patients. *Eur J Cardiothorac Surg.* 2019;55:476–483.
- Burgstaller JM, Held U, Mosbahi S, et al. A systemic review and meta-analysis: long-term results of the Bentall versus the David procedure in patients with Marfan syndrome. *Eur J Cardiothorac Surg.* 2018;54:411–419.
- Kunihara T, Aicher D, Rodionicheva S, et al. Preoperative aortic root geometry and postoperative cusp configuration primarily determine long-term outcome after valve-preserving aortic root repair. *J Thorac Cardiovasc Surg.* 2012;143:1389–1395.

<https://doi.org/10.1016/j.rec.2019.06.011>
1885-5857/

© 2019 Sociedad Española de Cardiología. Published by Elsevier España, S.L.U. All rights reserved.

Noninvasive ablation of ventricular tachycardia with stereotactic radiotherapy in a patient with arrhythmogenic right ventricular cardiomyopathy



Ablación no invasiva de taquicardia ventricular con radioterapia estereotáctica en un paciente con miocardiopatía arritmogénica de ventrículo derecho

To the Editor,

We present the case of a 64-year-old man diagnosed with arrhythmogenic right ventricular cardiomyopathy in 2007, following multiple sustained monomorphic ventricular tachycardia (VT) episodes. In 2008, an endocardial ablation was performed and an automatic cardioverter-defibrillator (ICD) was implanted. After some late recurrences, a second endocardial ablation was attempted in 2015. The patient's clinical course was favorable under sotalol and subsequently amiodarone, with several recurrences, treated mainly with antitachycardia pacing until 2018, when he had incessant episodes (Figure 1A) requiring high doses of intravenous amiodarone.

The patient was proposed for a third endocardial ablation procedure with the Rhythmia System (Boston Scientific, Marlborough, Massachusetts, United States). The sustained monomorphic VT was not inducible and therefore we used a substrate approach. The endocardium voltage map was fairly well preserved except for the outflow tract, but the pacemapping was acceptable in the

anterior midbasal free wall, quite close to the anchorage of the ICD lead (Figure 1B, C), and radiofrequency energy was delivered at this point. Two weeks after the ablation, the patient had new episodes of incessant sustained monomorphic VT, with the same morphology. Magnetic resonance imaging showed a hypocontractile right ventricle, with late gadolinium enhancement displaying a heterogeneous transmural scar in the midbasal region of the right ventricular free wall (Figure 1D).

In view of the need to perform a fourth procedure in a patient with transmural and epicardial substrate in a center without backup cardiac surgery, the decision was made to propose a noninvasive ablation with stereotactic radiotherapy (SBRT). Various options were extensively discussed with the patient, who provided informed consent. Because a noninvasive electroanatomic mapping system was not available in our center, we defined the target region for SBRT ablation from previous endocardial ablation procedures, facing it to the right ventricle scar by magnetic resonance imaging and computed tomography (CT) scan. This information was then transferred onto 4 dimensions to define the target volume.

The patient was immobilized with a vacuum-assisted device and SBRT radioablation was performed by a LINAC (Varian Medical Systems Inc, TRUE BEAM STX), with a cone-beam CT scan to align the radiation treatment with the target volume. A single dose of 25 Gy (Figure 1F) was prescribed for treatment volume, with the goal of maximal coverage within the volume while avoiding exposure to the surrounding organs at risk. The lung, esophagus,