

## Scientific letters

## Early and mid-term outcomes of mitral repair due to leaflet prolapse in a national referral center



## Resultados inmediatos y a medio plazo de la reparación del prolapso mitral en un centro de referencia nacional

## To the Editor,

Primary mitral regurgitation (MR) is the most frequent valve dysfunction in developed countries and mitral prolapse is the most common etiology. Although percutaneous therapy has emerged as an option for the treatment of MR in selected cases,<sup>1</sup> surgical repair is the gold-standard treatment and most of these valves are repairable in expert centers.<sup>2,3</sup> Driven by the excellent results of surgical repair, a trend toward earlier intervention has emerged, provided a successful and durable result is likely. However, 50% of patients currently undergoing surgery in Europe and North America still receive a prosthetic replacement instead.<sup>4</sup>

Our objective was to describe our early and mid-term results of the surgical repair of mitral prolapse. We conducted a retrospec-

tive review of all patients who underwent surgery due to severe MR secondary to valve prolapse from November-2011 to December-2018, excluding all concomitant procedures other than atrial fibrillation ablation. All patients had a comprehensive transthoracic echocardiogram shortly before the intervention and before discharge, and intraoperative transesophageal echocardiography was performed in all cases. All patients underwent at least 1 year of annual clinical and echocardiographic follow-up.

During the study period, 1456 patients underwent a mitral intervention and 229 met the inclusion criteria (table 1). Of these, 147 patients underwent a minimally-invasive mitral valve surgery (MIMVS) (64%) and 82 a median sternotomy (36%) (figure 1). MIMVS was performed almost entirely by 1 surgeon (93%). Complex morphologies (isolated anterior, commissural or bileaflet prolapse) were present in more than one third of patients. Concomitant atrial fibrillation ablation was performed in 30 patients (13%).

Successful mitral repair was achieved in 224 patients (97.8%) and the incidence of adverse events was low (table 1). Median intensive care unit and hospital stay were 1 and 7 days,

**Table 1**  
Patient characteristics and perioperative results

	Total (n = 229)	MIMVS (n = 147)	Conventional (n = 82)	P
<b>Preoperative data</b>				
Age, y	61 ± 12	60 ± 12	63 ± 12	.04
Male sex, %	157 (69)	100 (68)	57 (70)	.87
Weight, kg	73 ± 14	73 ± 14	74 ± 13	.42
Height, cm	169 ± 10	170 ± 10	168 ± 9	.29
Creatinine, mg/dL	0.95 ± 0.32	0.93 ± 0.31	1.00 ± 0.34	.11
Smoking, %	64 (28)	39 (27)	25 (30)	.56
Ischemic heart disease, %	11 (5)	4 (3)	7 (9)	.06
Hypertension, %	97 (43)	61 (42)	36 (44)	.79
Dyslipidemia, %	65 (29)	40 (28)	25 (31)	.60
Diabetes, %	16 (7)	10 (7)	6 (7)	1.00
Prior stroke, %	10 (4)	5 (3)	5 (6)	.34
AF, %	63 (28)	36 (25)	27 (33)	.17
COPD, %	17 (8)	8 (6)	9 (11)	.13
NYHA, %				<.01
I-II	150 (66)	106 (72)	44 (54)	
III-IV	79 (34)	41 (28)	38 (46)	
Left ventricular ejection fraction, %	61 ± 7	61 ± 7	60 ± 8	.47
End-diastolic diameter, mm	57 ± 7	56 ± 7	58 ± 6	.12
End-systolic diameter, mm	35 ± 6	35 ± 6	36 ± 5	.19
Prolapse location, %				.34
Posterior	149 (65)	98 (67)	51 (62)	
Anterior	20 (9)	14 (10)	7 (9)	
Bileaflet	58 (25)	34 (23)	24 (29)	
Previous cardiac operation, %	7 (3)	2 (1)	5 (6)	.10
EuroSCORE II	1.95 ± 2.34	1.57 ± 1.37	2.64 ± 3.36	<.01
<b>Perioperative results</b>				
Prosthetic mitral replacement, %	5 (2)	2 (1.4)	3 (4)	.35
In-hospital mortality, %	2 (0.9)	1 (0.7)	1 (1.2)	1
Intensive care unit stay, d	1 [1-1]	1 [1-1]	1 [1-2]	<.01

**Table 1** (Continued)

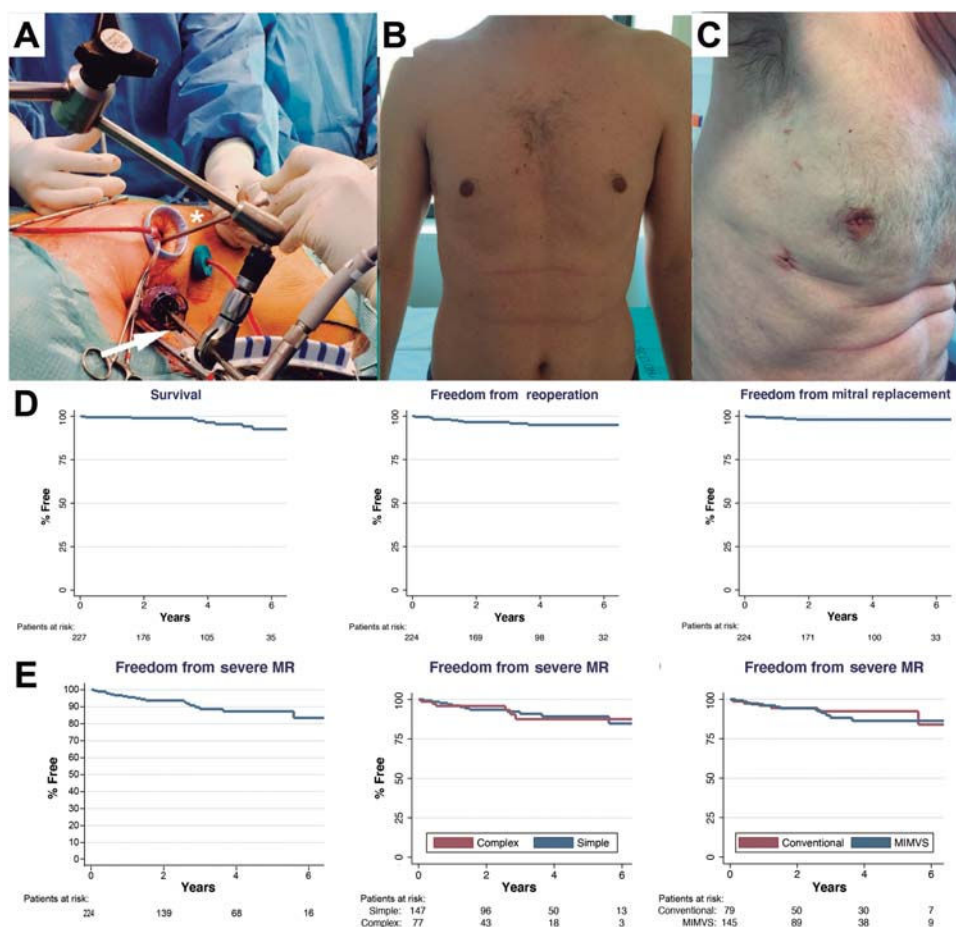
Patient characteristics and perioperative results

	Total (n=229)	MIMVS (n=147)	Conventional (n=82)	P
Hospital stay, d	7 [6-11]	7 [6-10]	8 [7-11]	.03
RBC units transfused	0 [0-0]	0 [0-0]	0 [0-1]	.19
Hemoglobin on day 5, mg/dL	11 ± 2	11 ± 2	10 ± 2	<.01
Mechanical ventilation duration, h	3 [0-7]	0 [0-6]	6 [3-10]	<.01
De novo postoperative AF, %	68 (30)	39 (27)	29 (36)	.14
Permanent pacemaker, %	7 (3)	4 (3)	3 (4)	.70
Permanent stroke, %	3 (1)	2 (1)	1 (1)	.66
Hemodialysis or CRRT	2 (1)	1(1)	1 (1)	1
Tamponade, %	4 (2)	1(1)	3 (4)	.13
Echocardiographic MR at discharge, %	n = 224*	n = 145*	n = 79*	.28
No MR	183 (81.7)	118 (81.4)	65 (82.3)	
Mild (and trace)	38 (17.0)	26 (17.9)	12 (15.2)	
Moderate	3 (1.3)	1 (0.7)	2 (2.5)	
Severe	0	0	0	

AF, atrial fibrillation; AKI, acute kidney insufficiency; COPD, chronic obstructive pulmonary disease; CRRT, continuous renal replacement therapy; MIMVS, minimally-invasive mitral valve surgery; MR, mitral regurgitation; NYHA, New York Heart Association; RBC, red blood cells.

Values are expressed as No. (%), mean ± standard deviation, or median [interquartile range].

\* After removing the patients who had a valve replacement.



**Figure 1.** Transareolar MIMVS picture. Arrow demonstrates the videocamera used, asterisk shows the long-shafted instruments (A). Cosmetic result after MIMVS using a minithoracotomy (B) or periareolar approach (C). Follow-up data showing overall survival, freedom from reoperation and from mitral replacement (D). Echocardiographic follow-up showing: overall freedom from recurrent moderate-or-severe regurgitation, the same for simple and complex forms and after Conventional or MIMVS repair (E). MIMVS, minimally-invasive mitral valve surgery; MR, mitral regurgitation.

respectively. Five patients underwent reoperation before hospital discharge due to increased MR compared with the intraoperative assessment. In all patients, we performed a

successful immediate re-repair during the same admission. A total of 99% of the patients repaired were discharged from the hospital with mild-or-less MR.

Clinical follow-up (median: 4; maximum: 8.3 years) showed that at 1-, 3- and 5-year survival was 99%, 99% and 95%, freedom from reoperation was 98%, 97%, and 95% and, finally, freedom from mitral replacement was 99%, 98%, and 98%, respectively. Echocardiographic follow-up (median: 3 years; maximum: 8.3 years) showed a freedom from recurrent MR (moderate-or-more) after 1, 3 and 5 years of 96%, 90%, and 89%, respectively. During follow-up, 10 patients underwent reoperation (range: 1 month to 7 years), in all cases for recurrent severe MR (due to disease progression in 60%). In 6 of these patients (60%), the mitral valve was re-repaired successfully. There were no reoperations for mitral stenosis or endocarditis and there were no differences in follow-up duration between groups.

Our data show that surgical repair of MR due to leaflet prolapse can be safely accomplished in most patients in a referral center. In contrast to most published series, which analyze patients undergoing repair excluding patients selected for other treatments, our cohort was defined by the valve dysfunction regardless of the procedure planned or performed.

Regarding the approach, thoracoscopic MIMVS was performed in 64% of patients, with increasing frequency over time. MIMVS provided excellent results, with decreased length of hospital stay (7 vs 8 days;  $P < .01$ ), intensive care unit stay (1 vs 1 day;  $P < .01$ ) and mechanical ventilation (median 0 vs 6 h;  $P < .001$ ), although the procedure required longer cardiopulmonary bypass (+30 min;  $P < .01$ ) and aortic cross-clamp duration (+19 min;  $P < .01$ ). Blood loss was reduced after MIMVS, as shown by the higher hemoglobin level after surgery (11 vs 10 mg/dL;  $P < .01$ ). MIMVS had no negative impact on repair quality, despite being offered to all types of patients regardless of repair complexity. Mid-term outcomes were similar with both approaches and freedom from valve replacement at 5 years was higher after MIMVS (100% vs 95%;  $P < .01$ ). The main limitation of this study comparing the 2 approaches is the risk of selection bias due to its retrospective nature. To account for this, we performed a propensity score matching (79 matched-pairs), which confirmed that all these differences, with the exception of total hospital stay, remained significant (data not shown).

Since we are currently recommending early surgery to younger, asymptomatic patients, there is growing demand to achieve excellent long-lasting results, with the lowest possible risk and surgical aggression. As shown in this study, equivalent or even superior results can be obtained with MIMVS in expert centers.<sup>5</sup> This highlights the importance of publishing institutional results of surgical repair, making this key information

available to cardiologists and patients to help them make the best decisions about options and timing of intervention.<sup>6</sup>

Mitral repair of severe MR due to leaflet prolapse can be accomplished with very good results (97.8% repair rate and 0.87% mortality). MIMVS can be offered to most patients without compromising outcomes and providing a faster recovery. Results up to 8 years after the procedure suggest excellent durability, regardless of the approach. Extended follow-up is required to establish long-term results.

María Ascaso,<sup>a</sup> Elena Sandoval,<sup>a</sup> Eduard Quintana,<sup>a</sup> Bàrbara Vidal,<sup>b,c</sup> Manuel Castellà,<sup>a</sup> and Daniel Pereda<sup>a,c,\*</sup>

<sup>a</sup>Servicio de Cirugía Cardiovascular, Instituto Clínico Cardiovascular, Hospital Clínic de Barcelona, Barcelona, Spain

<sup>b</sup>Servicio de Cardiología, Instituto Clínico Cardiovascular, Hospital Clínic de Barcelona, Barcelona, Spain

<sup>c</sup>Centro de Investigación Biomédica en Red de Enfermedades Cardiovasculares (CIBERCV), Spain

\*Corresponding author:

E-mail address: [dpereda@clinic.cat](mailto:dpereda@clinic.cat) (D. Pereda).

Available online 5 November 2020

## REFERENCES

1. Pascual I, Arzamendi D, Carrasco-Chinchilla F, et al. Reparación mitral transcateéter según la etiología de la insuficiencia mitral: datos de la vida real procedentes del registro español de MitraClip. *Rev Esp Cardiol.* 2020;73:643–651.
2. Castillo JG, Anyanwu AC, Fuster V, Adams DH. A near 100% repair rate for mitral valve prolapse is achievable in a reference center: implications for future guidelines. *J Thorac Cardiovasc Surg.* 2012;144:308–312.
3. David TE, Armstrong S, McCrindle BW, Manlihot C. Late outcomes of mitral valve repair for mitral regurgitation due to degenerative disease. *Circulation.* 2013;127:1485–1492.
4. Lung B, Baron G, Butchart EG, et al. A prospective survey of patients with valvular heart disease in Europe: The Euro Heart Survey on Valvular Heart Disease. *Eur Heart J.* 2003;24:1231–1243.
5. Perier P, Hohenberger W, Lakew F, Batz G, Diegeler A. Rate of repair in minimally invasive mitral valve surgery. *Ann Cardiothorac Surg.* 2013;2:751–757.
6. Adams DH, Anyanwu AC. The cardiologist's role in increasing the rate of mitral valve repair in degenerative disease. *Curr Opin Cardiol.* 2008;2:105–110.

<https://doi.org/10.1016/j.rec.2020.10.002>  
1885-5857/

© 2020 Published by Elsevier España, S.L.U. on behalf of Sociedad Española de Cardiología.

## Prognostic value of right ventricular function in light-chain cardiac amyloidosis treated with bortezomib



### Valor pronóstico de la función del ventrículo derecho en pacientes con amiloidosis cardíaca por cadenas ligeras tratados con bortezomib

#### To the Editor,

Amyloid light-chain (AL) amyloidosis is the most common form of cardiac amyloidosis; it is caused by hematological disorders. Cardiac involvement is observed in over 70% of patients at diagnosis and is a marker of poor prognosis.<sup>1</sup> Current treatment options are chemotherapy with bortezomib, hematopoietic stem cell transplant, and heart transplant.<sup>2</sup>

Two-dimensional strain echocardiography is the diagnostic<sup>3</sup> and prognostic technique of choice,<sup>4</sup> and right

ventricle (RV) parameters in particular provide important information.<sup>5,6</sup>

We investigated the prognostic value of echocardiographic parameters in patients with AL cardiac amyloidosis treated with bortezomib following the detection of cardiac involvement. Prognostic markers would enable the prompt institution of alternative treatments in patients expected to respond poorly to bortezomib and also avoid the use of futile treatment.

AL cardiac amyloidosis was diagnosed by endomyocardial biopsy using standard stains, including immunohistochemical staining with specific kappa and lambda light-chain antibodies. None of the patients underwent spectrophotometry. The primary outcome was death or heart transplant.

We prospectively included 47 patients with AL cardiac amyloidosis, all bortezomib-naïve at the time of echocardiography. Eight patients were excluded because they died before receiving the first cycle of bortezomib. Fifteen patients (38.5%) experienced a