

## Echocardiography in the acute phase of COVID-19 infection: impact on management and prognosis



### Ecocardiografía en la fase aguda de la infección por COVID-19: impacto en el tratamiento clínico y pronóstico

#### To the Editor,

Although coronavirus disease 2019 (COVID-19) is a systemic viral infection leading to severe acute respiratory syndromes, an increasing number of reports suggest that myocardial involvement is common and is associated with higher mortality.<sup>1</sup> It has been observed that left (LV) and right ventricular (RV) abnormalities may not be uncommon, raising concern for systemic inflammation.<sup>2</sup> However, there are few data on the performance of transthoracic echocardiography (TTE) to understand whether myocardial injury is a bystander phenomenon or a contributor to severe damage. Thus, this study aimed to define abnormalities on advanced TTE analysis in acute COVID-19 infection and to determine their implications in management and prognosis.

We performed a prospective cohort study including 200 patients admitted with COVID-19 and undergoing a TTE at the discretion of the clinician between March 1 and May 25, 2020. Due to the lack of familiarity with COVID-19, imaging was limited to patients who were expected to derive a benefit from its findings.<sup>3</sup> Exclusion criteria were as follows: absence of confirmed SARS-CoV-2, age < 18 years, handheld echocardiograms, and lack of quality. Each patient's chart was reviewed following TTE assessment to evaluate changes in management: treatment changes (antibiotics, diuretics, anticoagulation), hemodynamic support titration, facilitating decisions regarding patient care level, and no changes. Echocardiographic assessment, 2D-strain imaging, and myocardial work analysis was performed. Approval for the study was obtained from the center's Institutional Review Board. All patients included in the study signed the consent form prior to inclusion.

Sixty-six studies were included in the final analysis after exclusion of 134 patients (handheld echocardiograms, not following quality protocols). No differences regarding demographics and clinical characteristics were found between patients included and excluded in the analysis ( $P > .05$ ). The median age was 62 years [IQR, 55-70] and 59.1% of patients were males (Table 1). Median time between hospital admission and TTE was 14 days [IQR, 6-22]. Indication for TTE was: 50% systemic conditions concern (endocarditis, pulmonary embolism), 30.3% hemodynamic assessment (shock, heart failure), 19.7% cardiac conditions (elevated biomarkers, chest pain). Patients with an abnormal TTE were older and presented more cardiovascular risk factors compared with patients with a normal TTE. Overall, 36 patients (54.5%) had an abnormal TTE study (Table 2). The most frequent abnormality was diastolic dysfunction (defined according to the 2016 ASE/EACVI guidelines) (33.3%), followed by RV dysfunction (12.1%), LV dysfunction (6.1%), and severe valvular heart disease or endocarditis (3%). 2-dimensional strain imaging and myocardial work analysis were performed only in 33 and 16 patients, respectively, due to the required high-resolution image quality. LV global longitudinal strain (GLS) was reduced in 48.5% of the patients and myocardial work performance were all reduced in patients with an abnormal TTE, although differences were not significant. The RV was dysfunctional in 12.1% and RV strain was reduced in 17.7% of the patients. There were no significant differences between a normal or an abnormal TTE study and the presence of elevated high-sensitivity troponin I (hs-cTnI), N-terminal pro-B-type natriuretic peptide (NT-proBNP), or D-dimer levels ( $P > .3$  for all parameters). LV performance assessed by GLS

showed a significant association with hs-cTnI ( $r = -0.556$ ,  $P = .039$ ), as well as global myocardial work index (GWI) ( $r = -0.900$ ,  $P = .037$ ). An abnormal TTE was one of the steps that impacted the clinical decision-making process in 60 patients: 28 treatment changes, 22 discharges from intensive care, and 10 titrations of hemodynamic support. The median length of hospital stay was 34 (interquartile range [IQR], 16-49) days, and in-hospital death did not significantly differ between a normal or abnormal TTE result.

To our knowledge, this is the first prospective report on a cohort of selected patients with COVID-19 infection admitted to a tertiary referral center undergoing TTE at the physician's discretion. The main findings are: a) more than half of the patients with COVID-19 had an abnormal TTE study and the most prevalent abnormality was diastolic dysfunction, with only less than 12% of the patients showing RV or LV dysfunction; b) patients with an abnormal TTE study were older and had more cardiovascular risk factors than patients with a normal TTE; c) there were no significant differences between TTE result and cardiac biomarkers; d) the most common indications were concerns about a systemic condition and the TTE result directly modified management in most cases, being one of the analytic steps in the treatment decision-making process.

Recent studies showing troponins to be associated with higher C-reactive protein, cytokines and NT-proBNP levels in SARS-CoV-2 infection have suggested a link between myocardial injury, inflammation, and ventricular dysfunction<sup>1</sup>; however, these studies lack imaging findings. In our study, despite biological cardiac injury, LV systolic dysfunction and wall motion abnormalities were uncommon, suggesting it may be related to the inflammatory syndrome. LV GLS has been described to be reduced in 52% to 70% of COVID-19 patients, emerging as a strong predictor of mortality<sup>4</sup> and, in our data, myocardial work analysis was also significantly associated with hs-cTnI levels. Therefore, the most prevalent findings were subclinical changes, reinforcing evidence from other cohort studies, that cardiac involvement is high but mainly subclinical<sup>4,5</sup> (reduced GLS and persistent myocardial inflammation on cardiovascular magnetic resonance). In our cohort, strain and myocardial work analysis were not considered as surrogate markers of LV dysfunction in COVID-19 patients with a normal echocardiogram and did not influence the decision-making process. It remains unknown whether clinical decisions based on these parameters result in a better outcome. Further multimodality imaging and large-scale biomarker studies are necessary to understand the pathophysiology. In previous reports, a major cardiovascular event was the main factors indicating TTE<sup>2</sup>; however, in our study, the most frequent indicator was a systemic condition, because myocardial injury was carefully interpreted with integration of symptoms, electrocardiographic changes, and the likelihood of coronary disease. Based on our results and in agreement with previous publications,<sup>6</sup> an echocardiographic study should be limited to patients with a primary concern about a systemic condition, to rule out long-term intensive care unit complications, or to evaluate causes of hemodynamic instability and facilitate the decision-making process regarding patient care level and de-escalation of medical treatments.

This study has the limitations of selection bias, as echocardiography and biomarker testing were left to the physician's decision. Second, the single site and small sample size may have led to type II errors. However, the study was performed in a tertiary center representative of a large suburban area admitting 2025 patients with COVID-19 during the first wave of the pandemic. Third, it is unknown whether imaging abnormalities (diastolic dysfunction) were previously present and were thus unrelated to the infection. Finally, our results should be interpreted in light of the low

**Table 1**

Demographic and clinical characteristics of patients with and without a normal echocardiogram.

Variables	Overall (n = 66)	Normal echocardiogram (n = 30)	Abnormal echocardiogram (n = 36)	P
<i>Demographics and risk factors</i>				
Age, y	62 [55-70]	58 [51-65]	65 [58-71]	.015
Female sex	27 (40.9)	15 (50)	12 (33.3)	.131
BSA, kg/m <sup>2</sup>	2 [1.9-2.1]	2 [1.9-2.1]	2 [1.8-2.1]	.585
Current or previous smoker	20 (30.3)	3 (10)	17 (47.2)	.001
Diabetes mellitus	18 (27.3)	7 (23.3)	11 (30.6)	.354
Hypertension	31 (47.0)	9 (30)	22 (61.1)	.011
Hypercholesterolemia	19 (28.8)	7 (23.3)	12 (33.3)	.269
Chronic kidney disease	11 (16.7)	5 (16.7)	6 (16.7)	.627
Atrial fibrillation	6 (9.1)	0	6 (16.7)	.021
Ischemic heart disease	3 (4.6)	0	3 (8.3)	.156
Chronic obstructive pulmonary disease	5 (7.9)	0	5 (13.9)	.042
Previous organ transplant	7 (10.6)	4 (13.3)	3 (8.3)	.397
Heart failure	4 (6.1)	1 (3.3)	3 (8.3)	.379
Severe valvular heart disease	5 (7.6)	1 (3.3)	4 (11.1)	.257
Charlson comorbidity index	2 (1-4)	1 (0-2)	3.5 (1-5)	.004
<i>Baseline treatment</i>				
ACEI	6 (9.1)	2 (6.7)	4 (11.1)	.413
ARB	16 (24.2)	5 (16.7)	11 (30.5)	.155
Beta-blocker	14 (21.2)	5 (16.7)	9 (26.0)	.306
Loop diuretics	3 (4.8)	2 (6.7)	1 (2.8)	.429
Insulin therapy	8 (12.7)	3 (10)	5 (13.9)	.488
Anticoagulant therapy	8 (12.7)	0	8 (22.2)	.006
<i>Cause of admission</i>				
Respiratory	40 (67.8)	18 (66.7)	22 (68.8)	.542
Fever	52 (88.1)	26 (96.3)	26 (81.25)	.082
Gastrointestinal	13 (22.0)	8 (29.6)	5 (15.6)	.164
Asymptomatic	7 (10.6)	3 (10)	4 (11.1)	.603
<i>Laboratory findings</i>				
Elevated hs-cTnI levels	22 (57.9)	11 (57.9)	11 (57.9)	.628
hs-cTnI, ng/L	50 [12-188]	74 [9-296]	48 [12-188]	.930
Elevated NT-proBNP levels	24 (72.7)	12 (75.0)	12 (70.1)	.543
NT-proBNP, pg/mL	1429 [198-5849]	1272 [267-4101]	1429 [198-5849]	.943
Elevated D-dimer levels	52 (85.3)	24 (85.7)	28 (84.9)	.607
D-Dimer, ng/mL	3251 [1489-7763]	3362 [1638-7262]	3251 [1246-12 192]	.965
<i>Management</i>				
Intensive care level	39 (59.1)	22 (73.3)	17 (47.2)	.028
Noninvasive ventilation or high flow oxygen therapy	8 (12.1)	0	8 (22.2)	.005
Invasive mechanical ventilation	33 (50.0)	22 (73.3)	11 (30.6)	.001
PEEP, mmHg	10 (8-12)	10 (8-12)	10 (8-14)	.457
Vasopressor requirement	24 (36.4)	13 (42.2)	11 (30.6)	.207
<i>In-hospital outcomes</i>				
Venous thromboembolism	20 (32.3)	10 (33.3)	10 (27.8)	.412
Pulmonary embolism	9 (14.5)	3 (10)	6 (16.7)	.339
Stroke	5 (7.6)	2 (6.7)	3 (8.3)	.587
Acute coronary syndrome	1 (1.5)	1 (3.3)	0	.455
In-hospital mortality	7 (10.6)	2 (6.7)	5 (13.9)	.296

ACEI, angiotensin-converting-enzyme inhibitors; ARB, angiotensin II receptor blockers; BSA, body surface area; hs-cTnI, high-sensitivity cardiac-specific troponin I; NT-proBNP, N-terminal pro-B-type natriuretic peptide; PEEP, positive end-expiratory pressure.

Categorical values are expressed as No. (%) and continuous values as median [interquartile range]

mortality of our population and the absence of a short-term impact does not allow conclusions to be drawn on the absence of long-term consequences.

In conclusion, severe echocardiographic abnormalities are uncommon in hospitalized patients with COVID-19 infection, who show mostly subclinical myocardial changes. However, in

**Table 2**  
Echocardiographic findings in patients with a normal and abnormal echocardiographic study and COVID-19.

Variables	Normal echocardiogram (n = 30)	Abnormal echocardiogram (n = 36)	P
<b>Left ventricle</b>			
LV dysfunction	0	7 (19.4)	.011
LV end-diastolic dimension, mm	44 (40-50)	45 (41-50)	.775
LV end-systolic dimension, mm	27 (23-31)	29 (24-33)	.314
LV ejection fraction 4Ch, %	63 (60-66)	57 (52-65)	.032
LV GLS, %	-18.2 [-14.2-22.7]	-17.1 [-12.3-22.2]	.649
Reduced LV GLS	7 (50)	9 (47.4)	.580
Regional motion abnormalities	0	5 (13.9)	.042
<b>Right ventricle</b>			
RV dysfunction	0	8 (22.2)	.006
TAPSE, mm	22 [20-24]	19 (18-22)	.031
Reduced TAPSE	0	8 (22.2)	.021
S' wave, cm/s	14.7 [12-17]	13.8 [12-15.5]	.452
RV fractional area change %	50 [43-59]	45 [41-54]	.157
Reduced RV fractional area change	0	5 (19.2)	.158
RVFWLS %	-25 [-23.5-27.2]	-23 [-21-29]	.955
Reduced RVFWLS	0	3 (23.1)	.421
<b>Myocardial work (available for 16 patients)</b>			
Reduced GWI	0	3 (30)	.250
GWI, mmHg%	2010 [1780-2138]	1908 [1474-2362]	
Reduced GCW	1 (16.7)	3 (30)	.999
GCW, mmHg%	2211 [1966-2374]	2185 [1513-2650]	
Elevated GWW	0	4 (40)	.234
GWW, mmHg%	68 [49-73]	124 [80-142]	
Reduced GWE	0	4 (40)	.234
GWE, %	96 [95-97]	93 [89-96]	
<b>Diastolic function</b>			
LV diastolic dysfunction	0 (0)	28 (77.8)	.001
Types of diastolic dysfunction			.001
Diastolic dysfunction type I	0 (0)	23 (63.9)	
Diastolic dysfunction type II	0 (0)	2 (5.6)	
Diastolic dysfunction type III	0 (0)	3 (8.3)	
E/A ratio	1.1 [0.9-1.2]	0.7 [0.6-1.0]	.002
Mitral valve deceleration time, ms	219 [202-233]	207 [275-250]	.414
E/e' ratio	9 [7-10]	9 [7-11]	.947
Elevated E/e' ratio	0	3 (15)	.244
<b>Mitral regurgitation</b>			
None	17 (73.9)	22 (61.1)	.305
Mild-moderate	6 (26.1)	13 (36.1)	.402
Severe	0	1 (2.8)	.610
<b>Tricuspid regurgitation</b>			
None	10 (50)	19 (52.8)	.531
Mild-moderate	10 (50)	15 (41.7)	.586
Severe	0	2 (5.6)	.532
<b>Severe valvular heart disease</b>			
	0	5 (13.9)	.034
<b>Pulmonary hypertension (RVSP <math>\geq</math> 35 mm Hg)</b>			
	2 (6.8)	9 (25.0)	.047

FAC, fraction area change; GCW, global constructive work; GLS, global longitudinal strain; GWE, global work efficiency; GWI, global work index; GWW, global wasted work; LV, left ventricle; RV, right ventricle; RVFWLS, right ventricle free wall longitudinal strain; RVSP, right ventricle systolic pressure. Data are expressed as no. (%) or median [interquartile range].

these patients echocardiographic study is useful to guide the treatment and clinical decision-making process.

## FUNDING

There are no funding sources for this article for any author.

## AUTHORS' CONTRIBUTIONS

All authors had access to the data and participated in the preparation of this manuscript. All authors have contributed to the conceptualization of the study, data curation, formal analysis, investigation, methodology, validation, writing, and reviewing.

## CONFLICTS OF INTEREST

None.

Maribel González-Del-Hoyo,<sup>a</sup> Luz Servato,<sup>a</sup> Eduardo Ródenas,<sup>a,b</sup>  
Jordi Bañeras,<sup>a,b</sup> Ignacio Ferreira-González,<sup>a,c,\*</sup>  
and Jose Rodríguez-Palomares<sup>a,b,\*</sup>

<sup>a</sup>Departamento de Cardiología, Hospital Universitari Vall d'Hebron, Vall d'Hebron Institut de Recerca, Universitat Autònoma de Barcelona, Barcelona, Spain

<sup>b</sup>Centro de Investigación Biomédica en Red de Enfermedades Cardiovasculares (CIBERCV), Spain

<sup>c</sup>Consortio de Investigación Biomédica en Red de Epidemiología y Salud Pública (CIBERESP), Instituto de Salud Carlos III, Madrid, Spain

\*Corresponding author:

E-mail addresses: [jfrodrig@vhebron.net](mailto:jfrodrig@vhebron.net) (J. Rodríguez-Palomares), [iferreir@vhebron.net](mailto:iferreir@vhebron.net) (I. Ferreira-González).

## REFERENCES

1. Shi S, Qin M, Shen B, et al. Association of Cardiac Injury With Mortality in Hospitalized Patients With COVID-19 in Wuhan China. *JAMA Cardiol.* 2020;5:802–810.
2. Jain SS, Liu Q, Raikhelkar J, et al. Indications for and Findings on Transthoracic Echocardiography in COVID-19. *J Am Soc Echocardiogr.* 2020;33:1278–1284.
3. Skulstad H, Cosyns B, Popescu BA, et al. COVID-19 pandemic and cardiac imaging: EACVI recommendations on precautions, indications, prioritization, and protection for patients and healthcare personnel. *Eur Heart J Cardiovasc Imaging.* 2020;21:592–598.
4. Lairez O, Blanchard V, Houard V, et al. Cardiac imaging phenotype in patients with coronavirus disease 2019 (COVID-19): results of the cocarde study. *Int J Cardiovasc Imaging.* 2020;9:1–9.
5. Weckbach LT, Curta A, Bieber S, et al. Myocardial Inflammation and Dysfunction in COVID-19-Associated Myocardial Injury. *Circ Cardiovasc Imaging.* 2021;14:e012220.
6. Rodríguez-Santamarta M, Minguito-Carazo C, Echarte-Morales JC, et al. Echocardiographic findings in critical patients with COVID-19. *Rev Esp Cardiol.* 2020;73:861–863.

<https://doi.org/10.1016/j.rec.2021.11.012>

1885-5857/© 2021 Sociedad Española de Cardiología. Published by Elsevier España, S.L.U. All rights reserved.

### An adolescent girl with severe biventricular dysfunction and pediatric inflammatory multisystem syndrome after COVID-19



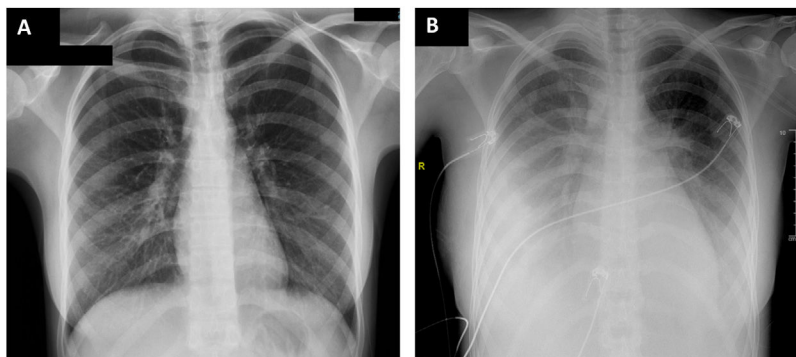
#### Mujer joven con disfunción biventricular y síndrome inflamatorio multisistémico pediátrico tras la COVID-19

##### To the Editor,

Pediatric inflammatory multisystem syndrome (PIMS) is a recently described entity with onset 2 to 6 weeks after a severe acute respiratory syndrome coronavirus 2 (SARS-CoV-2) infection in children.<sup>1</sup>

We describe a 17-year-old girl with PIMS and severe myocardial involvement who presented to the emergency department (informed consent for this publication was given by the patient and her legal guardian). The patient had no relevant medical history, except for paucisymptomatic SARS-CoV-2 infection 1 month earlier that was treated on an outpatient basis. The patient reported headache, fever of up to 39 °C, odynophagia, diffuse abdominal pain, vomiting, and dry cough lasting 1 week.

On arrival at the emergency department, blood pressure was 105/67 mmHg, heart rate 120 bpm, baseline oxygen saturation 94%, and temperature 37.4 °C. The physical examination revealed diffuse abdominal pain on palpation and skin rash in the hypogastric area. Electrocardiography and chest radiography on admission showed no abnormalities (**figure 1A**). Laboratory tests revealed elevated C-reactive protein (256 mg/L), D-dimer (4844 ng/mL), procalcitonin (4.04 ng/mL), high-sensitivity troponin I (162 ng/L), and N-terminal pro-brain natriuretic peptide (NT-proBNP) (9140 ng/L). Echocardiography showed preserved biventricular function with no other pathologic findings (**video 1 of the supplementary data**). Abdominal and pelvic ultrasound and computed tomography ruled out acute abdominal disease, but revealed enlarged mesenteric lymph nodes smaller than 1 cm. A gynecological ultrasound disclosed free fluid in the pouch of Douglas; a sample was collected under ultrasound guidance and showed a predominance of polymorphonuclear cells (85%) but cultures were negative. Blood cultures were also negative. Empirical antibiotic therapy was started with meropenem, clindamycin, and vancomycin, and the patient was admitted to the ward.



**Figure 1.** Chest radiograph: on admission (A) and 24 hours later (B).