

BRIEF REPORTS

Middle Aortic Syndrome Caused by Takayasu's Disease and Treated by Stent Implantation: A Report of Medium-Term Follow-Up

Jacek Bialkowski, Malgorzata Szkutnik, Ramón Bermúdez-Cañete^a, Jacek Kusa, Stanislaw Regiec and Charles E. Mullins^b

Silesian Center for Heart Diseases. Zabrze. Polonia. ^aHospital Ramón y Cajal. Madrid. España.
^bBaylor College of Medicine. Houston, Texas. USA.

A 13-year-old girl with middle aortic syndrome caused by Takayasu's disease was treated by balloon angioplasty of the right renal artery stenosis and the implantation of 3 stents, 2 in the stenosed thoracic segment and 1 in the abdominal segment of the aorta. Spiral computed tomography one and two years after the stents were inserted showed that the disease had progressed despite treatment with immunosuppressants.

Key words: *Takayasu's disease. Stent. Follow-up.*

Full English text available at: www.revespcardiol.org

Síndrome de la aorta media causado por enfermedad de Takayasu: tratamiento con stents y seguimiento a medio plazo

Se presenta el caso de una niña de 13 años de edad con síndrome de aorta media causado por enfermedad de Takayasu. Fue tratada con angioplastia con balón de la arteria renal derecha e implante de 3 *stents*: dos en el segmento estenótico torácico y uno en la aorta abdominal. Después de 1 y 2 años de la implantación de los *stents* se realizó una TC helicoidal, que puso de manifiesto una progresión de la enfermedad a pesar del tratamiento con inmunodepresores.

Palabras clave: *Enfermedad de Takayasu. Stent. Seguimiento.*

INTRODUCTION

The middle aortic syndrome with localized or diffuse stenosis of the inferior thoracic aorta or the abdominal aorta is an unusual cause of arterial hypertension in the upper extremities.¹ This syndrome may be caused by Takayasu disease,² usually diagnosed by angiography, which shows stenosis of the affected segments. We present the case of a 13-year-old girl with involvement of the aorta and renal arteries, treated with renal balloon angioplasty and stent implantation in several segments. Follow-up 2.5 years later was documented by computerized helicoidal tomography images with contrast.

Este trabajo ha sido realizado según el programa gubernamental de cooperación hispano-polaca.

Correspondence: Dr. J. Bialkowski.
41 800 Zabrze, Szpitalna 2. Polonia.
E-mail: jabi_med@priv4.onet.pl

Received 3 May 2001.
Accepted for publication 28 September 2001.

CLINICAL CASE

A 13-year-old girl was admitted to our hospital with severe cardiac insufficiency and basal rales, hepatomegaly, and significant cardiomegaly. She was treated with diuretics, digital, and steroids, with rapid clinical improvement. During the examination, 160/70/95 mm Hg hypertension was found in the upper extremities associated with weak femoral pulses and a systolic murmur in the back. Cardiac catheterization was performed under general anesthesia, by accessing a vein to the aorta with 5 Fr Multipurpose and Pigtail catheters. Angiographic study revealed a stenotic segment in the thoracic aorta, located in the diaphragm, 8 cm long by 5 mm in diameter (Figure 1A) and other severe stenosis of the abdominal aorta (3 mm in diameter) between the origin of the renal arteries and the iliac bifurcation, without opacification of the iliac or left femoral arteries (Figure 2A). Selective injection of contrast material revealed additional stenosis in the right renal artery (Figure 3). A peak to peak systolic gradient of 45 mm Hg in the thoracic aorta and 35 mm Hg between the proximal and distal abdominal aorta were observed, as was a 40 mm Hg gradient of the right renal artery.

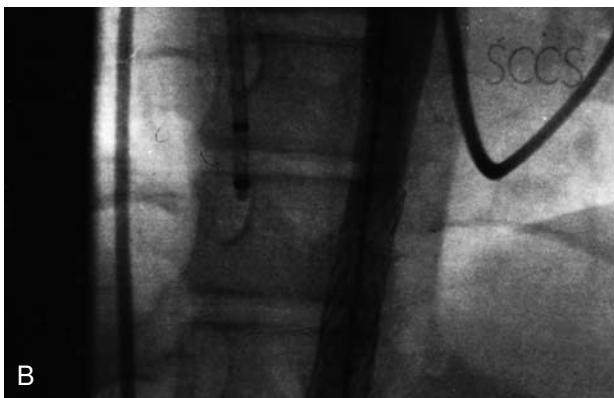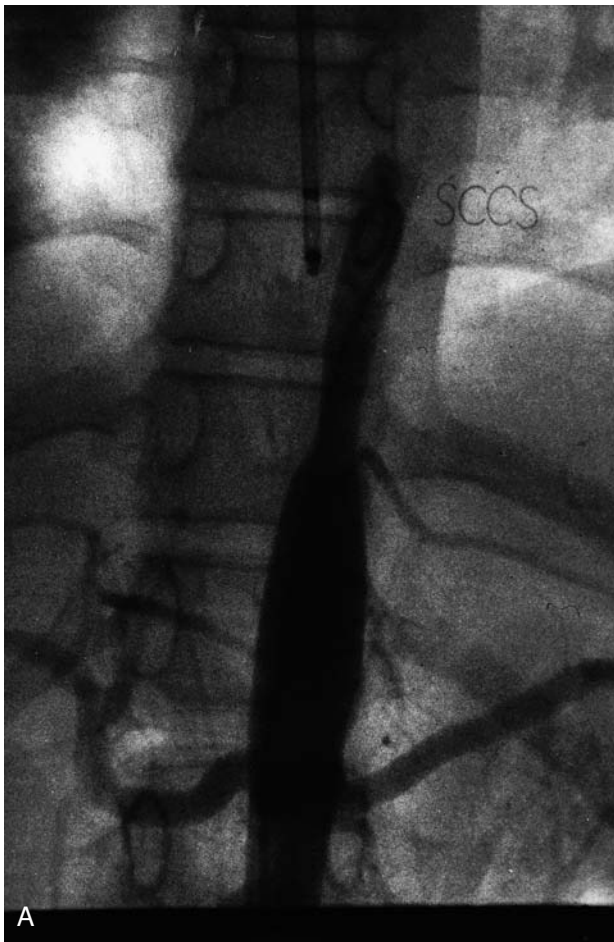


Fig. 1. A: Aortogram reveals a large stenotic segment in the thoracic aorta located in the diaphragm. **B:** Aortogram after the implantation of 2 superimposed stents.

All clinical and angiographic data confirmed the diagnosis of Takayasu disease affecting the mid-aorta. Some of these lesions were initially treated with therapeutic catheterization. Heparin at a dose of 100 U/kg was administered to the patient. Angioplasty with a 4 mm diameter Tacker balloon at 20 atm pressure was performed on the stenosis of the right renal artery, with clear improvement obtained. Later, an 8 Fr Mullins catheter was introduced into the right femoral artery and 3

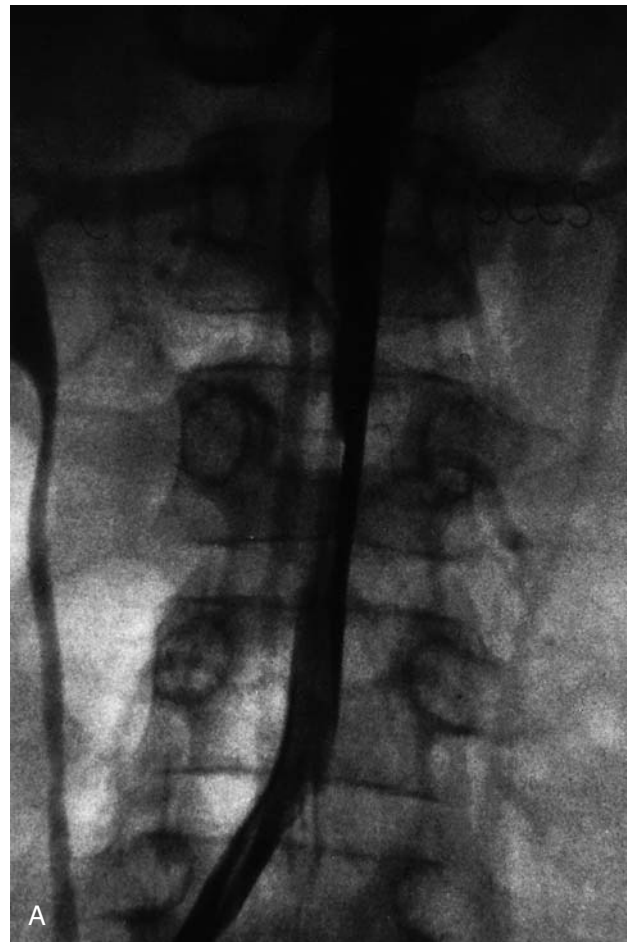

Fig. 2A. Aortogram reveals stenosis of the abdominal aorta between the origin of the renal arteries and the iliac bifurcation. The left iliac artery is not visible.

Palmaz stents (P-308 Johnson & Johnson) were implanted to dilate the stenotic segments of the mid and descending aorta. Two superimposed implanted stents were expanded sequentially in the diffuse stenosis of the diaphragm (Figure 1B), utilizing a Powerflex 10 mm diameter by 4 cm long balloon for its implantation and dilatation. The third stent was implanted in the stenosis of the abdominal aorta (Figure 2B), using a similar balloon measuring 8 mm in diameter by 4 cm long. Immediately following the implant, the aortic pressure gradient disappeared, achieving a decrease in systemic arterial pressure (from 210/160/180 to 140/90/105 mm Hg). The superior stenotic segment diameter increased from 5 to 10 mm and the inferior diameter from 3 to 8 mm. After the procedure, acetylsalicylic acid at a dose of 5 mg/kg was administered for 3 months.

Immunodepressor treatment with steroids and azathioprine was initiated for treatment of Takayasu disease that continues to the present time. A general improvement in hypertension was achieved (130/80/98 mm Hg, associated with nifedipine and enalapril treatment)

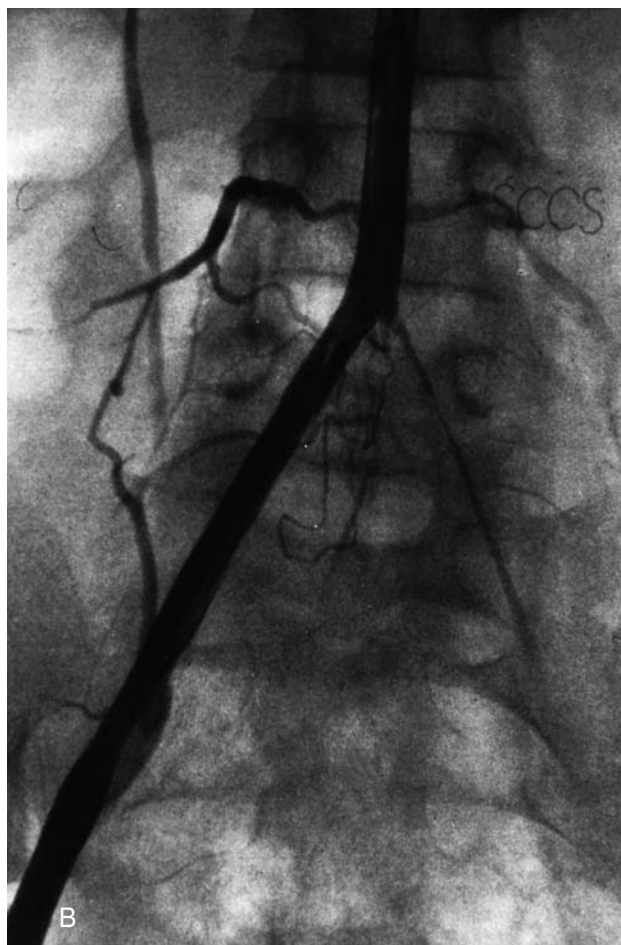


Fig. 2B. Aortogram after the implantation of the stent in the stenotic segment of the abdominal aorta. Very severe stenosis of the left iliac artery is seen.

with better exercise tolerance. At 6 months, the child's parents refused a repeat catheterization to re-dilate the stents. Instead, computerized helicoidal tomography with contrast was performed at 1- and 2-year-follo-wup, and similar results were obtained on both studies. The images confirmed the permeability of the stents and revealed a new, very severe, area of stenosis just below the renal arteries (Figure 4). At present, the patient is in a good state of health, with arterial pressure of 121/55 mm Hg, according to the latest Holter monitor, and continues with enalapril and nifedipine treatment.

DISCUSSION

Aortic arteritis is a chronic inflammatory disease of unknown etiology that affects the aorta and its branches. In children, it is an aggressive and frequently lethal disease, with a mortality rate according to one study of 35% during 5-year observation period.³ The mechanical obstruction appears to be the predominant cause of hypertension in patients with significant ste-

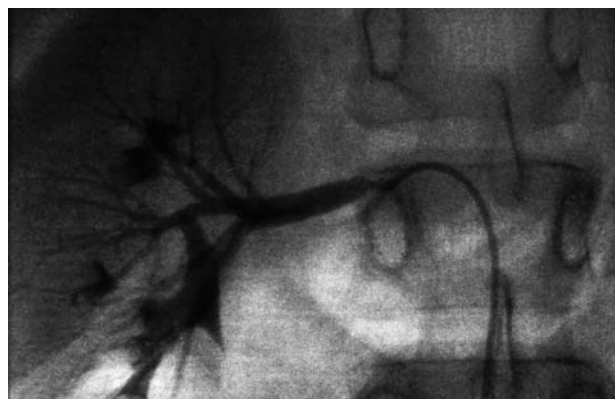

Fig. 3. Right renal arteriogram that shows stenosis at its origin.

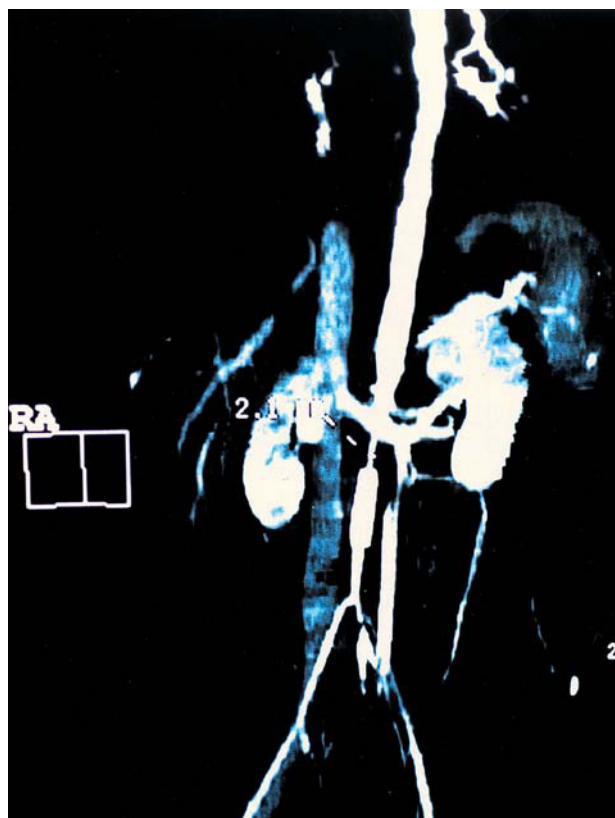


Fig. 4. Computerized helicoidal tomography on which the permeability of the implanted stents can be seen, as can new stenotic segments in the abdominal aorta located in the renal arteries.

nosis in the aorta. Takayasu disease with congestive cardiac insufficiency has been found more frequently in children than adults.⁴ In these circumstances, the initial diagnosis may be difficult because of the absence of hypertension and weak peripheral pulses caused by congestive cardiac insufficiency.

The characteristic clinical picture (hypertension of the upper extremities with weak or absent femoral pulses) may, as in our patient, appear after initial treatment of cardiac insufficiency. The anatomy of the ste-

notic segments may reveal circumscribed or diffuse lesions located in the thoracic or abdominal aorta. Treatment consists of attempts to dilate with balloon in cases of localized stenosis^{4,5} or surgery, interposing a bypass with conduit when a very long segment is affected.² As in our patient, balloon angioplasty may be especially effective in decreasing circumscribed stenosis of the renal artery.⁶ In the case of diffuse aortic obstructions, there is a greater risk of uncontrolled dissection of the aortic wall or post-dilation re-stenosis, and implantation of stents may be more useful and provide greater treatment safety.^{7,8} In our patient, treatment was planned in stages and stents were electively dilated at a suboptimum diameter that was less than that of a normal aorta in the stenotic areas, in an attempt to avoid over-dilation. A decision to re-dilate at a later date was rejected by the child's parents. Therefore, we were obliged to control the progression of the disease with helicoidal tomography with contrast and 3-dimensional image reconstruction. We had the same experience as Quanadil et al⁹ in the use of non-invasive monitoring in this disease. At medium-term follow-up, we detected disease progression in spite of continued immunodepressor treatment.

CONCLUSION

Our experience confirms that the mid-aorta syndrome caused by Takayasu disease progresses in severity.

Stent implantation may be palliative, and continuous follow-up with computerized helicoidal tomography is necessary both short- and long-term.

BIBLIOGRAFÍA

1. Sumboonnanonda A, Robinson BL, Gedroyc WM. Middle aortic syndrom: clinical and radiological findings. *Arch Dis Child* 1992; 67:501-5.
2. Pagni S, Denatale RW, Boltax RS. Takayasu's arteritis: the middle aortic syndrome. *Ann Surg* 1996;62:409-12.
3. Morales E, Pineda C, Martinez-Lavin M. Takayasu's arteritis in children. *J Rheumatol* 1991;18:1081-4.
4. Tyagi S, Khan AA, Kaul UA, Arora KR. Percutaneous transluminal angioplasty for stenosis of the aorta due to aortic arteritis in children. *Ped Cardiol* 1999;20:404-10.
5. Kashani IA, Skalansky MS, Movahed H. Successful balloon dilatation of abdominal coarctation of the aorta in patient with presumed Takayasu's aortitis. *Cathet Cardiovasc Diagn* 1996;38:406-9.
6. Tyagi S, Kaul UA, Satsangi DK, Arora R. Percutaneous transluminal angioplasty for renovascular hypertension in children: initial and long term results. *Pediatrics* 1997;99:44-9.
7. Brzezinska Rajszyz G, Quereshi SA, Ksiazek J, Zubrzycka M, Kosciesza A, Kubicka K, et al. Middle aortic syndrom treated by stent implantation. *Heart* 1999;81:166-70.
8. Tyagi S, Sharama VP, Arora R. Stenting aorta for recurrent, long stenosis due to Takayasu's arteritis in a child. *Pediatr Cardiol* 1999;20:215-7.
9. Quanadli SD, Sissakian JF, Rocha P, Piette AM, Lacombe P. Takayasu's arteritis: Spiral CT angiography findings. *Circulation* 2000;101:345-7.