

ECHOCARDIOGRAPHY-DOPPLER

Assesment of Right Ventricular Function Using Contrast Echocardiography in Patients with Myocardial Infarction

Gabriela Borrayo, Guillermo Careaga, Carlos J. Muro, Alonzo Autrey, Pascual Pérez, Raúl Yáñez, Gerardo Espínola and Rubén Argüero

Unidad de Cuidados Intensivos Coronarios. Hospital de Cardiología Centro Médico Nacional Siglo XXI. Instituto Mexicano del Seguro Social. México DF. México.

Objective. To evaluate right ventricular size, motility, and ejection fraction (RVEF) by contrast echocardiography.

Methods. We studied consecutive patients admitted to the coronary intensive care unit with acute inferior myocardial infarction, without prior infarction and with or without right ventricle involvement, according to accepted electrocardiographic findings. Polygelin, 3.5% solution, was used for contrast echocardiography. The reference standard was equilibrium radionuclide angiography.

Results. We studied 44 patients using contrast echocardiography, average patient age 60.8 ± 10.6 years, 38 men and 6 women. Abnormal right ventricular size (more than 25 mm) yielded a sensitivity of 79%, specificity of 87%, positive and negative predictive values of 92 and 68%, respectively, and a likelihood ratio of 6. Abnormal right ventricular motility had a sensitivity of 70%, specificity of 94%, positive and negative predictive values of 95 and 67%, respectively, and a likelihood ratio of 11.6. Right ventricular ejection fraction $< 30\%$ with contrast echocardiography had a sensitivity of 69%, specificity of 97%, positive and negative predictive values of 90 and 88% respectively, and a likelihood ratio of 6.9.

Conclusion. In patients with acute inferior myocardial infarction, contrast echocardiography with the area-length method is a valid and reproducible technique for evaluating right ventricular ejection fraction, which is easy to perform and can be done at the patient's bedside.

Key words: *Contrast echocardiography. Myocardial infarction. Right ventricular function.*

Full English text available at: www.revespcardiol.org

Correspondence: Dra. G. Borrayo.
Unidad de Cuidados Intensivos Coronarios. Hospital de Cardiología Centro Médico Nacional Siglo XXI. Instituto Mexicano del Seguro Social. Avda. Cuauhtémoc, 330, Colonia Doctores. Delegación Cuauhtémoc. 06720 México DF. México.
E-mail: gborrayos@hotmail.com.mx

Received 19 November 2002.

Accepted for publication 23 September 2002.

Valoración de la función ventricular derecha mediante ecocardiografía de contraste en pacientes con infarto agudo de miocardio

Objetivo. Evaluar el valor diagnóstico del tamaño, la motilidad y la fracción de eyección del ventrículo derecho (FEVD) con ecocardiografía de contraste (EC).

Métodos. Incluimos a pacientes consecutivos con el primer acontecimiento de infarto agudo de miocardio inferior con o sin extensión eléctrica al ventrículo derecho. Usamos solución de poligelina al 3,5% para la EC y se comparó con la angiografía de equilibrio con radionúclidos (AER).

Resultados. Estudiamos con EC a 44 pacientes, 38 varones y 6 mujeres, con una edad promedio de $60,8 \pm 10,6$ años. Para el tamaño anormal del ventrículo derecho (más de 25 mm) encontramos una sensibilidad del $79 \pm 4\%$ y especificidad del $87 \pm 3\%$, los valores predictivos positivo y negativo fueron del 92 ± 3 y el $68 \pm 4\%$, respectivamente, y el cociente de probabilidad fue de 6. Para la motilidad alterada del ventrículo derecho la sensibilidad fue del $70 \pm 5\%$ y la especificidad del $94 \pm 2\%$, los valores predictivos positivo y negativo fueron del 95 ± 2 y el $67 \pm 5\%$, respectivamente, y el cociente de probabilidad fue de 11,6. Para la fracción de eyección del ventrículo derecho (FEVD) menor del 30% con EC, la sensibilidad fue del $69 \pm 3\%$ y la especificidad del $97 \pm 2\%$, mientras que los valores predictivos positivo y negativo fueron del 90 ± 2 y el $88 \pm 4\%$, respectivamente, con un cociente de probabilidad de 6,9.

Conclusión. En los pacientes con infarto agudo de miocardio inferior la EC con el método de área longitud es una técnica válida y reproducible para evaluar la función ventricular derecha, es simple de realizar, segura y se puede hacer en la cabecera del paciente.

Palabras clave: *Ecocardiografía de contraste. Infarto de miocardio. Función ventricular derecha.*

INTRODUCTION

The complex and mutable form of the right ventricle makes it difficult to use a simple geometric model to evaluate its function, as is possible with the left ventricle. Various techniques have been used to this end

ABBREVIATIONS

ERA: equilibrium radionuclide angiography.
CE: contrast echocardiography.
RVEF: right ventricular ejection fraction.
RVF: right ventricular function.

–initially, conventional angiography, followed by nuclear medicine, echocardiography, and recently, magnetic resonance (MR), with no gold standard yet established. It is accepted that nuclear medicine studies, specifically equilibrium radionuclide angiography, avoids dealing with the problem of the complexity of the cavity to a certain degree, although it has the disadvantage of exposing the patients to radiation and is not always available. Echocardiography, in its various forms, has been explored as a better method for studying right ventricular function. There are currently 4 imaging that try to imitate a geometric model (single plane, Simpson's rule, area-length method, and geometric contour models), which have been compared with angiographic studies, nuclear medicine studies, and hemodynamic monitoring.¹ The area-length method is thought to have the greatest practical application and some studies with MR have confirmed the validity of this method.²

The literature has described 68% sensitivity and 82% specificity when the area-length method is compared to 2-dimensional echocardiography and conventional angiography.³ Two-dimensional echocardiography has also been compared to first-transit radionuclide angiography to estimate right ventricle ejection fraction (RVEF), noting a correlation of between 0.74 and 0.784.

The first transit equilibrium radionuclide angiography study (ERA) established the presence of a right ventricular infarct with hemodynamic repercussions.⁵

Right ventricular function (RVF) is important in the clinical course of some diseases, as is the case in patients with an acute myocardial infarct and right ventricle damage in whom evaluation of RVF at various time intervals is crucial, given its prognostic and therapeutic value.⁶

The aim of our study was to evaluate the diagnostic value of RVF with the parameters of size, motility, and RVEF in patients with an acute inferior myocardial infarct with or without electrical spread to the right ventricle using contrast echocardiography (CE).

METHODS

We studied 44 consecutive patients admitted to the Coronary Intensive Care Unit in the Hospital de Cardiología del Centro Médico Nacional Siglo XXI with an acute inferior myocardial infarction with or without involvement of the right ventricle. The inclu-

sion criteria were:

- Patients identified as having acute myocardial infarction, based on 2 of the following criteria: *a*) oppressive precordial pain equal to 30 minutes duration; *b*) ST segment elevation equal to 1 mm in at least 2 continuous leads in the inferior area; in order to establish a diagnosis of involvement of the right ventricle, an ST segment elevation greater than 1 mm in right V3 or V4, or both, and *c*) an enzyme creatinphosphokinase elevation of twice or more its normal value.
- Patient consensus.

We did not include patients with previous myocardial infarction, a history of chronic serious pneumonopathy requiring hospitalization or oxygen therapy, congenital cardiopathy or previous valve disease, constrictive pericarditis, or pulmonary arterial hypertension.

We used the ERA as a standard of reference to compare with CE in accordance with the opinion of a group of experts from the hospital. All patients underwent both studies, with an average of 4 hours (range, 1 to 12 hours) between the 2 tests. The studies were performed and interpreted blindly and independently. We evaluated the size, motility, and the RVEF in order to evaluate RVF.

Equilibrium radionuclide angiography

ERA was performed by marking erythrocytes with radioactive material and administration of stannous pyrophosphate and 35 minutes later technetium 99m (20 millicuries-mCi) intravenously. Fifteen minutes after reaching intravascular radioactivity equilibrium, emission left anterior oblique projection, left lateral, and anteroposterior images were acquired. In the first projection a caudal inclination of approximately 10° was made to achieve adequate separation of the cavities. The images were acquired on a gamma camera (Elscint Apex Cardial) via the Elscint Gated module. Each cardiac cycle was divided into 24 quadrants and stored on a 64×64 pixel matrix for automatic, semi-automatic, and manual processing by medical software, with which we created a volume curve, with calculation of the first curve made to obtain the systole and diastole intervals and in order to calculate the ejection fraction of both ventricles (Figure 1), as well as the regional motility of the walls.⁷ In order to evaluate the size of the right ventricle this was done qualitatively whether there was a change or not.

Conventional echocardiography

Before or after the nuclear medicine study (less than 12 hours before or after) a 2-dimensional transthoracic study was performed on a Toshiba model Sonolayer SSA-270 unit, with a 2.5 MHz transducer. The size

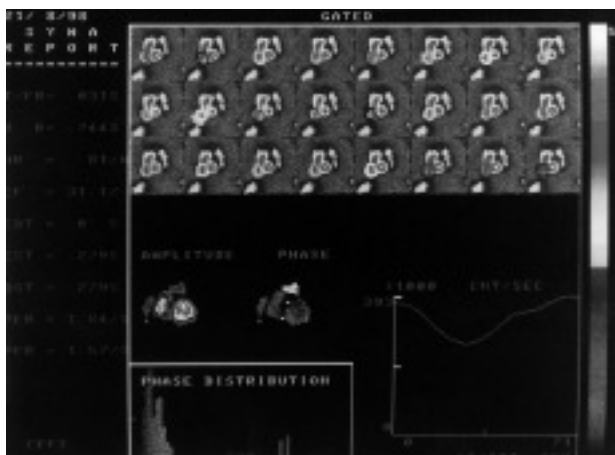


Fig. 1. Equilibrium radionuclide angiography. Note in the left anterior oblique projection the images acquired with the calculation of the right ventricle ejection fraction.

and motility of both ventricles were evaluated with the patient in the left lateral decubitus position in the left longitudinal and transverse parasternal axis planes. The apical axis 4-chamber plane was also used to evaluate the motility of the ventricles and to calculate the area of the right and left ventricles. In the dorsal decubitus position with the knees flexed at subxiphoid height in the sub costal axis plane for the outlet tract of the right ventricle, we measured the length in both systole and diastole and calculated the RVEF by the area-length method (Figure 2).

Contrast echocardiogram

A contrast echocardiogram was performed after the standard echocardiogram. In order to calculate the RVEF in the 4-chamber apical axis, we traced the areas of the right ventricle in systole and diastole (Figure 3), after introduction of a 3.5% polygeline solution manually recorded by the Tei technique⁸ via the venous approach and we measured the length of the outlet tract (Figure 4). With the coefficient of the difference in volumes we calculated the percentage of the corresponding RVEF in each case. We considered a contrast image to be adequate when the grey scale was greater than 70 pixels in a graphic design program (Corel 8; Figure 3).

Contrast preparation

We prepared 10 solutions normally reserved for treating hospitalized patients to evaluate which would be the best echocardiography contrast material, evaluating the homogeneity of the micro bubbles, their distribution, and life in suspension under examination with a Reichert Polivar brand microscope at 100× magnification after manual agitation in two 5-mL syringes using the Tei technique.⁸ The solutions tested were: a)

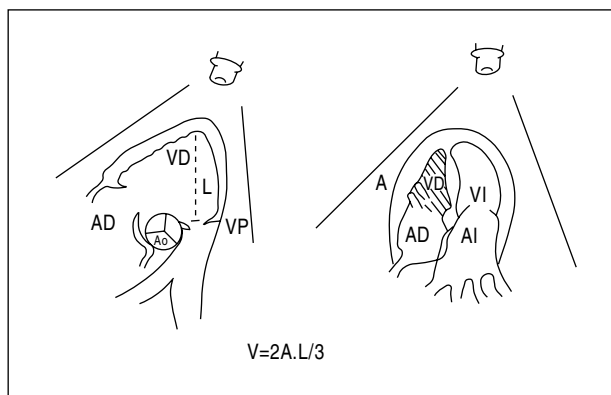


Fig. 2. Calculation of right ventricular volume using the area-length method. The image shows, on the left, the subxiphoid projection of the length (L) of the outlet tract of the right ventricle, measured from the apical region to the pulmonary valve (PV); the right side shows the apical 4-chamber projection the area (A) of the right ventricle (RV). RA indicates right atrium; LA, left atrium; AV, aortic valve; LV, left ventricle.

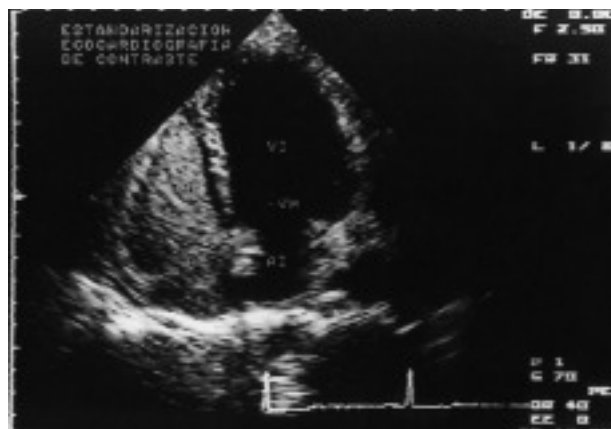

Fig. 3. Note the evident delineation of the right ventricle in the 4-chamber apical projection with contrast echocardiography, which facilitates the measurement of its area in the different phases of the cardiac cycle. LA indicates left atrium; LV, left ventricle; MV, mitral valve.

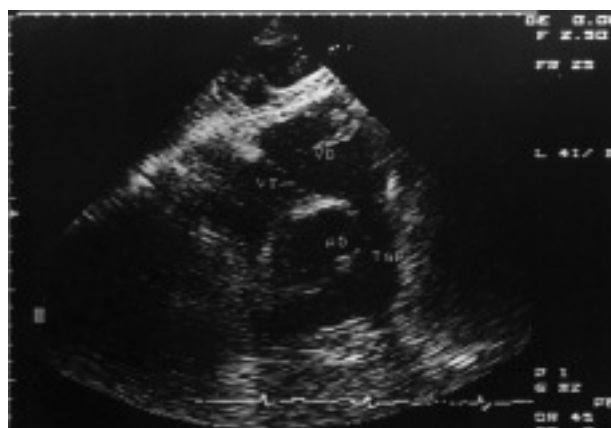

Fig. 4. The outlet tract of the right ventricle can be seen from the apical region to the pulmonary valve in the subxiphoid projection. AV indicates aortic valve; TPA, trunk of the pulmonary artery; RV, right ventricle; TV, tricuspid valve.

a 3.5% polygeline solution; b) Hartman solution; c) 50% glycosylated solution; d) 10% glycosylated solution; e) human albumin; f) vascoray; g) 20% manitol; h) Optiray; i) 5% glycosylated solution, and j) 0.9% sodium chloride solution. We found that the 3.5% polygeline solution had a more homogeneous distribution, as well as a longer life in suspension. We observed afterwards that the 3.5% polygeline solution and the human albumin solution were better visualized on echocardiography and had less reverberation; we therefore decided to use the 3.5% polygeline solution as echocardiography contrast.

Statistical analysis

Quantitative variables were expressed as mean \pm standard deviation and qualitative variables in percentages. Intra- and inter-observer concordance was evaluated with the Kappa index. We determined a cut-off point for the RVEF with a COR curve so that it could be used as a line of demarcation for important change in the RVF. We calculated the sensitivity (a/a+c), specificity (d/d+b), positive predictive values (a/a+b), and negative predictive values (d/d+c) with a 95% confidence interval (CI) and probability quotient. We also evaluated the correlation of the RVEF with the CE and the ERA. We used the SPSS statistical package, version 10.

RESULTS

We studied 44 patients with ERA and CE, 38 men (86%) and 6 women (14%), with a mean age of 60.8 years \pm 10.6 years. Mean time elapsed between the acu-

TABLE 1. General data on patients with acute inferior myocardial infarction with or without involvement of the right ventricle studied with contrast echocardiography and equilibrium radionuclide angiography

Variable	Frequency
Age, years \pm SD	60.8 \pm 10.6
Sex, male	38/44 (86%)
Risk factors	
Diabetes mellitus	13/44 (30%)
Systemic arterial hypertension	25/44 (57%)
Smoking	33/44 (75%)
Dyslipemia	9/44 (21%)
Clinical data	
Right ventricular infarct	24/44 (55%)
Jugular inguritation	17/44 (39%)
Pulmonary rales	3/44 (7%)
Hepatomegaly	5/44 (11%)
Echocardiography data	
FEV1, % \pm SD	48.8 \pm 6.8
RVEF, % \pm SD	38.6 \pm 9.6
Pericardial hemorrhage	18/44 (41%)
Paroxysmal septal movement	6/44 (14%)
Permeable fossa ovale	7/44 (16%)

SD indicates standard deviation; LVEF, left ventricle ejection fraction; RVEF, right ventricle ejection fraction.

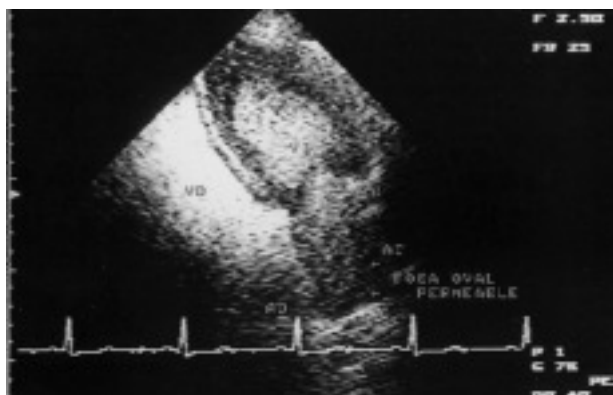


Fig. 5. Note that upon introducing the contrast medium into the right cavities, it passed into the left cavities via the permeable fossa ovale. RA indicates right atrium; LA, left atrium; RV, right ventricle; LV, left ventricle.

te myocardial infarct and the performance of the studies was 3.8 days \pm 1.7 days. Both studies were performed on the same day less than 12 hours apart.

We observed involvement of the right ventricle in 24 patients (55%). The left ventricular ejection fraction was 48.8% \pm 6.8%, and for the right ventricle it was 38.6% \pm 9.6%. In 18 patients (41%) we observed pericardial hemorrhage with no signs indicative of cardiac tamponade (Table 1).

In 7 cases (16%) we corroborated permeability of the fossa ovale which indirectly indicated an elevation in the right atrium and ventricle pressures (Figure 5).

Intra- and inter-observer concordance of the echocardiographic studies was evaluated by the kappa index in 22 patients. Regarding size, they were 0.84 and 0.84, respectively, and for the altered motility of the right ventricle they were 0.84 and 0.79. For RVEF they were 0.94 and 0.84, respectively. For improved visualization of the endocardium, the kappa index was 0.84 and 0.79, respectively. The best cut-off point for RVEF with CE was 30% (Figure 6).

Conventional echocardiography

For abnormal size of the right ventricle (>25 mm), we found a sensitivity of 79% \pm 4% and a specificity of 87% \pm 3%. The positive and negative predictive values were 92% \pm 3% and 68% \pm 4%, respectively. The probability quotient was 6. For changed motility of the right ventricle we found a sensitivity of 70% \pm 5% and specificity of 94% \pm 2%, and the positive and negative predictive values were 95% \pm 2% and 67% \pm 5%, respectively. The probability quotient was 11.6 (Table 2).

Contrast echocardiography

Using the area-length method, RVEF of less than 30% with CE we found a sensitivity of 69% \pm 3% and a specificity of 97% \pm 2%; the positive and negative pre-

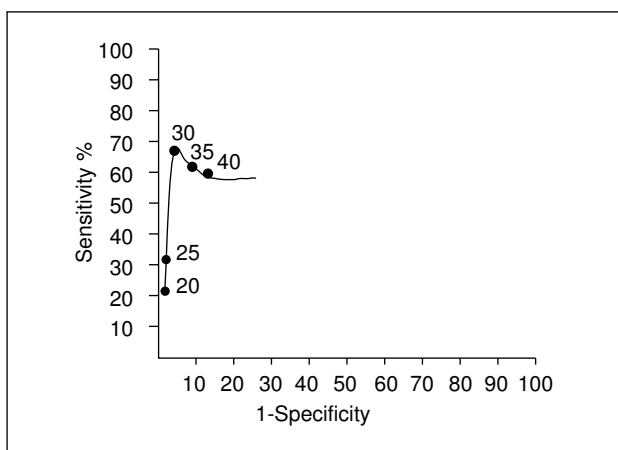


Fig. 6. Receptor operative characteristics curve (ROC) of the right ventricular ejection fraction (RVEF) with contrast echocardiography (CE) compared to equilibrium radionuclide angiography.

dictive values were $90\% \pm 2\%$ and $88\% \pm 4\%$, respectively. The probability quotient was 6.9 (Table 2). The correlation between CE and equilibrium angiography for RVEF was 0.529 (Spearman r), and $P = .0001$.

Additionally, the CE improved in a semi-quantitative manner the visualization of the right ventricular endocardium. We established a scale of 0 when there was no improvement, 1 if the improvement was suboptimal, and 2 if it was optimal. We studied 176 segments from 44 patients: the anterior segment (41 with a scale of 2 and 3 with a scale of 1), the lateral segment (39 with a scale of 2 and 5 with a scale of 1), the posterior segment (36 with a scale of 2 and 8 with a scale of 1), and the outlet tract segment (34 with a scale of 2 and 10 with a scale of 1). The total was 150 segments (85.2%) achieving optimal visualization of the endocardium and 26 segments (14.8%), suboptimal visualization.

DISCUSSION

Evaluating the right ventricle is a challenge given its complex and variable morphology, depending on the volume. Nevertheless, its clinical importance requires assiduous study, which results in the continuous creation of new techniques aimed at improving existing

techniques. At present, these improved methods do not include silicone molds or radiograph angiographic studies whose use has now been surpassed by other techniques. In nuclear medicine studies ventricular geometry does not have much of an impact,^{4-6,9} and may be considered as more of a reference guide given that with such studies a time-activity curve in systole and diastole can be obtained independently of the type of right ventricle studied. Nuclear medicine studies, however, have some technical limitations that require strict quality control in addition to experience, including the transfer of the patient to a special room at a specific time, even in third tier hospitals, which makes this type of study somewhat difficult. Conventional echocardiography, on the other hand, has been widely used for the study of the right ventricle because it provides accessibility and reproducible results, although this technique also has limitations. The primary limitation is that it does not have a geometric model as the left ventricle does, so that ventricular volumes are underestimated because the outlet tract is not taken into account as it is in single plane, Simpson's, and geometric contour methods.¹ Another limitation is the difficulty in visualizing the endocardium and, consequently, the difficulty in adequately tracing the ventricular area in the various phases of the cardiac cycle.^{8,10} In our study, the use of contrast semi-quantitatively improves the visualization of the endocardium and the delineation of the 3 parts of the right ventricle (inlet tract, body, and outlet tract). This facilitates the measurement of the ventricle areas in systole and diastole, as well as the outlet tract, without excluding patients who have a poor acoustic window,¹¹ and provides a real estimate of the ventricular volumes when used with the method based on area-length of a pyramid, which is the most accepted and has the broadest clinical application.¹ This method was initially used by Ferlinz et al,¹² Levine et al,¹³ and Gibson et al,¹⁰ although with the change of taking a subcostal image (designed specially for this purpose) of the entire length of the outlet tract (Figure 2). The visualization of the endocardium of the right ventricle was optimal in 85.2% of the segments with EC, which to a certain degree avoids the problem of a poor echocardiographic window; although it would be of greater help to

TABLE 2. Diagnostic value of right ventricular function on contrast echocardiography in patients with acute inferior myocardial infarction with or without involvement of the right ventricle, compared with equilibrium radionuclide angiography

Variable	Sensitivity (%) (95% CI)	Specificity (%) (95% CI)	PPV (%) (95% CI)	NPV (%) (95% CI)	PQ
Size of the RV > 25 mm	79 ± 4	87 ± 3	92 ± 3	68 ± 4	6.0
Altered motility	70 ± 5	94 ± 2	95 ± 2	67 ± 5	11.6
RVEF on EC < 30%	69 ± 3	97 ± 2	90 ± 2	88 ± 4	6.9

CI indicates confidence interval; PPV, positive predictive value; NPV, negative predictive value; PQ, probability quotient; RV, right ventricle; RVEF, right ventricular ejection fraction; CE, contrast echocardiography.

perform the study quantitatively with second harmonic and contrast imaging, as has been done in the left ventricle.¹⁴ The contrast study allows us to evaluate the 3 parameters that we consider adequate for RVF (size, motility, and RVEF) in all the patients included in the study. In addition, there are other important findings, such as the movement of the interventricular septum (which is relevant in the evaluation of ventricular interdependence), the presence of pericardial hemorrhage, and, above all, the permeability of the fossa ovale, which indirectly reveal a final elevated diastolic pressure of the right ventricle (Figure 5). The sensitivity and specificity obtained for RVEF are better than those reported by Niederle et al,³ but this is not true of those reported by Dell'Italia et al.¹⁵

Recently, 3-dimensional echocardiography¹¹ has been used to evaluate the right ventricle, and this technique could be the future gold standard. In contrast to other studies with CE,¹⁶⁻¹⁸ our study included a specific group of patients in whom the clinical application of CE was very valuable; we determined the diagnostic value of CE with the area-length method vs ERA.

In patients with acute inferior myocardial infarction and its affect on the right ventricle, it is important to control the clinical and hemodynamic status, which varies according to resistance and degree of involvement; as has been observed experimentally. An unaffected right ventricle can change its peristaltic contraction to contractile synchronization, as is true of the left ventricle, when its load is increased,^{19,20} but when there is damage we still have a long way to go. CE can be helpful during the first week postinfarct, given that right ventricular function can be evaluated thoroughly without the need for transferring patients from the coronary intensive care unit to a special unit to perform a nuclear medicine study, particularly if they require breathing support, a temporary pacemaker, or hemodynamic monitoring.

The use of this technique may be useful in other illnesses in which establishing the RVF is indispensable, such as in congenital cardiopathy that requires surgical repair.

CONCLUSION

In patients with acute inferior myocardial infarction, CE using the area-length method is a valid and reproducible technique for evaluating RVF, is simple to perform, is safe, and can be performed out at the patient's bedside.

ACKNOWLEDGMENTS

We are grateful to the Instituto Mexicano del Seguro Social (IMSS): registry FP-0038/256, and to the Comisión Nacional de Ciencia y Tecnología (CONACYT), grant 116517. We are also grateful to Mario Alberto Arévalo Pérez, who helped with the creation of the drawings.

REFERENCES

- Jiang L, Levine R, Weyman AE. Echocardiographic assessment of right ventricular volume and function. *Echocardiography* 1997;14:189-205.
- Helbing W, Bosch H, Maliepaard C, Rebergen S, Geest R, Hansen B, et al. Comparison of echocardiographic methods with magnetic resonance imaging for assessment of right ventricular function in children. *Am J Cardiol* 1995;76:589-94.
- Niederle P, Jezek V, Jezkova J, Michaljanic A. Three echocardiographic methods in right ventricular function evaluation. *Cardiology* 1991;78:334-9.
- Panidis I, Ren J, Kotler M, Mintz G, Iskandrian A, Ross J, et al. Two-dimensional echocardiographic estimation of right ventricular ejection fraction in patients with coronary artery disease. *J Am Coll Cardiol* 1983;2:911-8.
- Starling M, Dell'Italia L, Chaudhuri T, Boros B, O'Rourke R, Heyl B, et al. First transit and equilibrium radionuclide angiography in patients with inferior transmural myocardial infarction: criteria for the diagnosis of associated hemodynamically significant right ventricular infarction. *J Am Coll Cardiol* 1984;4:923-30.
- Zehender M, Kasper W, Kauder E, Schonthaler M, Geibel A, Olschewski M, et al. Right ventricular infarction as an independent predictor of prognosis after acute inferior myocardial infarction. *N Engl J Med* 1993;328:981-8.
- Ritchie JL, Bateman TM, Bonow RO, Crawford MH, Gibbons RJ, Hall RJ, et al. Guidelines for clinical use of cardiac radionuclide imaging. *J Am Coll Cardiol* 1995;25:521-47.
- Tei C, Sakamaki T, Shah P. Myocardial contrast echocardiography: a reproducible technique of myocardial opacification for identifying regional perfusion defects. *Circulation* 1983;67:585-93.
- Holman L, Wynne J, Zielonka J, Idoine J. A simplified technique for measuring right ventricular ejection fraction using the equilibrium radionuclide angiocardiogram and the slant-hole collimator. *Radiology* 1981;138:429-35.
- Gibson T, Miller S, Aretz T, Hardin N, Weyman AE. Method for estimating right ventricular volumen by planes applicable to cross-sectional echocardiographic: correlation with angiographic formulas. *Am J Cardiol* 1985;55:1584-8.
- Espinosa RA, Yong R, Enciso R, Baduñ E. Evaluación de la fracción de expulsión del ventrículo derecho por ecocardiografía. *Arch Inst Mex* 1991;61:157-61.
- Ferlinz J, Gorlin R, Cohn P, Herman M. Right ventricular performance in patients with coronary artery disease. *Circulation* 1975; 52:608-15.
- Levine R, Gibson T, Aretz T, Gillan L, Guyer D, King M. Echocardiographic measurement of right ventricular volume. *Circulation* 1984;69:497-505.
- Fernández J, García M, Moreno M, González M, Placer J, Allue C, et al. Utilidad de las nuevas técnicas de imagen, segundo armónico y contraste en la visualización del borde endocárdico. Análisis de la reproducibilidad en la valoración de la contracción segmentaria. *Rev Esp Cardiol* 2000;53:1459-66.
- Dell'Italia LJ, Satarling MR, Crawford MH, Boros BL, Chaudhuri TK, O'Rourke RA, et al. Right ventricular infarction: Identification by hemodynamic measurements before and after volume loading and correlation with noninvasive techniques. *J Am Coll Cardiol* 1984;4:931-9.
- Wann L, Stickels K, Bamrah V, Gross C. Digital processing of contrast echocardiograms: a new technique for measuring right ventricular ejection fraction. *Am J Cardiol* 1984;53: 1164-8.
- Lange P, Seiffert P, Pries F, Wassel A, Onnasch D, Hahne H. Value of image enhancement and injection of contrast medium for right ventricular volume determination by two-dimensional echocardiography in congenital heart disease. *Am J Cardiol* 1985;55: 152-7.
- Tokgozoglul SL, Caner B, Kabakci G, Kes S. Measurement of right ventricular ejection fraction by contrast echocardiography. *Int J Cardiol* 1997;59:71-4.
- Gines F, Grignola J. Sincronización de la contracción del ventrículo derecho frente a un aumento agudo de su poscarga «izquierdización» del comportamiento mecánico del ventrículo derecho. *Rev Esp Cardiol* 2001;54:973-80.
- Zarco P. El ventrículo derecho revisitado. *Rev Esp Cardiol* 2001; 54:938-40.