

Percutaneous Coronary Intervention in Bifurcation Lesions. Does Classification Aid Treatment Selection?

Alfonso Medina and Javier Suárez de Lezo

Servicio de Cardiología, Hospital Universitario de Gran Canaria Dr. Negrín, Las Palmas de Gran Canaria, Las Palmas, Spain

Coronary bifurcation lesions are a challenge for percutaneous treatment.¹⁻⁵ How big a challenge depends on the complexity of the bifurcation. In general, drug-eluting stents are indicated in this type of coronary lesion because they can help reduce the restenosis rate and, in turn, the need for a second intervention, with the technical difficulties which that involves.

Types of Bifurcations

Simple bifurcations are those which respect side branch (SB) origins ($\{110\}$, $\{100\}$, $\{010\}$ in Medina's classification⁶). Their treatment is simple; it is often sufficient to simply implant a stent in the main vessel (MV), as long as it covers the SB origin. Interventions should only be performed on the SB if the ostium is compromised. This can be done in 2 ways: via angioplasty alone when the SB is small in comparison to the main vessel or using simultaneous angioplasty with 2 balloons (kissing balloons) if the SB is a similar size to the distal segment of the main vessel. Use of the latter procedure is justified by the need to adapt the stent to the greater diameter of the proximal component of the bifurcation. An additional objective of this technique is to optimize scaffolding at the SB ostium as well as preventing a reduction in the luminal area of the stent below the SB origin.

In the majority of cases, both maneuvers are adequate to correct focal damage to the SB ostium. Figure shows an example of a simple bifurcation $\{110\}$. In the ultrasonic image, the carina shows a pointed morphology which may lead to ostial SB

compromise if displacement occurs due to stent implantation in the MV. In these circumstances, angioplasty can help to reposition the carina and correct ostial SB compromise. The use of a protective guidewire for the SB in this type of bifurcation is optional but, from our point of view, desirable in 2 cases: when the angles are very open, which may complicate access to the target vessel should that be necessary and, independently of the angle, when the SB is large. When the SB diameter is small and its contribution to myocardial perfusion relatively insignificant (short epicardial trajectory), it is sufficient to aim to maintain permeability. We therefore agree with other authors³ that, in these cases, an intervention on the SB can be avoided, even if ostial compromise was produced after stent implantation in the MV, as long as the flow is adequate for the intervention. This strategy is known as KIO (*keep it open*).

In complex bifurcations, in which the proximal $\{101\}$, distal $\{011\}$, or both $\{111\}$ components of the SB origin and the MV are involved, published randomized trials (Table)⁷⁻¹⁰ have shown treatment with a temporary stent to be effective. Of these studies, only 2^{8,10} clearly specified the type of bifurcation involved. The temporary stent combines 2 types of endoluminal treatment: a stent for the main vessel and angioplasty, with its limitations, for the side branch. Furthermore, opening the stent's lateral cell provides a certain degree of scaffolding for the SB ostium.

In patients assigned to the simple strategy, crossover to 2 stents occurs in between 2% and 51% of cases. This variability can be explained by the high frequency of suboptimal SB angiographic outcomes. These poor outcomes are even more notable when compared to the excellent angiographic outcomes obtained with the stent in the main vessel (oculostenotic reflex). The differences between the series almost certainly derive from how strictly the criteria of residual SB stenosis $>50\%$ was applied when deciding on the need for a second stent. An important feature of our study⁸ was the decision to avoid implantation of a second stent (in most

SEE ARTICLE ON PAGES 606-14

Correspondence: Dr. A. Medina.
Servicio de Cardiología.
Hospital Universitario de Gran Canaria Dr. Negrín.
Barranco de la Ballena, s/n. 35010 Las Palmas de Gran Canaria.
Las Palmas, España.
E-mail: alfmedina1@yahoo.es

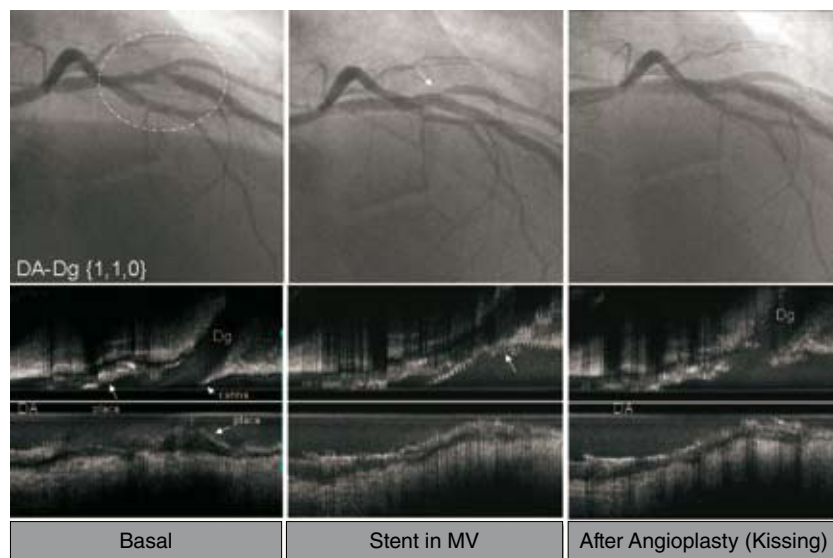


Figure. AD-lesion bifurcation Dg {110}. The longitudinal intracoronary ultrasound examination shows plaque proximal and distal to the SB origin, which is free of disease. The carina has a pointed morphology and is free of plaque. After implanting the stent in the MV, angiography shows SB ostium compromise (arrow) due to displacement of the carina (arrow). After simultaneous angioplasty with 2 balloons, the carina is repositioned (arrow) to correct ostial SB compromise. AD indicates anterior descending; Dg, diagonal; MV, main vessel; SB, side branch.

TABLE . Randomized Trials of Treatment for Lesions in Coronary Bifurcations

	Patients	Type of Bifurcation	Crossover Rate to 2 Stents in Temporary Stenting	SB Diameter, mm	Type of Complex Technique	Follow-up, mo	MACE, Temporary Stent	MACE, Complex Technique
Colombo et al (2004) ⁷	86	Not available	51%	2.6 (0.5)	Crush	6	Very high crossover rate 8%	24%
Pan et al (2004) ⁸	91	111, 82%; 011, 5%; others, 13% ^a	2%	2.3 (0.5)	T stent	6		7%
Nordic (2006) ⁹	413	Not available	4%	2.6 (0.4)	Crush, 50%; culotte, 21%; others, 29%	6	2.9%	3.4%
CACTUS (2009) ¹⁰	350	111, 75%; 101, 3%; 011, 16%; others, 6%	31%	2.16 (0.3)	Crush	6	15%	15.8%

MACE indicates major adverse cardiovascular events; SB: side branch.

^aAdapted from the Medina classification.

lesions with SB disease). In fact, although in the Nordic study⁹ crossover to 2 stents occurred in 4% of cases, the percentage of bifurcations with baseline SB disease was not specified. Complementary techniques (determination of fractional flow reserve, intracoronary ultrasound, and optical coherence) have substantially improved knowledge of the degree of SB compromise after treatment with a temporary stent, though their complexity limits their use in daily clinical practice.

In patients assigned to treatment with 2 stents (complex strategy), in spite of the excellent immediate angiographic outcome, the rate of adverse events during follow-up was similar to that observed in patients treated with a temporary stent. In our view,

this is a consequence of several characteristics of the intervention, including the impossibility of adapting 2 stents to a bifurcation because of a gap in stent coverage at some points of the bifurcation as well as the overlapping occurring between one or more layers of metal at certain points of the treated lesion. It may also be due to the impossibility of optimizing the stent at the SB ostium (difficulty in performing the final kissing balloon), because of the difficulty of maintaining the geometry of the expanded stent in the MV and / or SB, and probably because of the impossibility of preventing damage to the non-visible components of the drug-eluting stent (polymer and drug), which are a direct result of the manipulation required in these techniques.

Complex Bifurcation Techniques Using 2 or More Stents

Recently, the European Bifurcation Club proposed a means of classifying multiple bifurcation techniques using 2 or more stents.⁴ The categories are based on the sequence of stent implantation, which facilitates understanding. We believe that complex techniques should be reserved for cases in which the SB ostium is affected, where the disease extends for at least 10 mm, and where 1 or 2 components of the MV are affected ($\{111\}$, $\{101\}$, $\{011\}$). These techniques should only be performed by experienced interventionists, as even seemingly simple techniques involve difficulties which can make their execution, and the post-intervention assessment of the bifurcation, problematic. The complex techniques also pose problems which may require further revascularization at the bifurcation. In all cases, the interventionist should provide an accurate description of the technique used in anticipation that subsequent revascularization may be required.

Currently, no studies are available to clarify whether any of the techniques described is superior to the others according to bifurcation anatomy and site.

Devices for the Treatment of Bifurcation Lesions Using Stents

A number of devices have been designed specifically for the treatment of bifurcation lesions and represent a range of approaches to overcoming the difficulties associated with providing optimal scaffolding at bifurcations.¹¹ There are, for example, devices which employ a stent with an additional balloon (for temporary stenting) in order to improve access to the SB during stent deployment in the MV. They also aim to ensure optimal distribution of the stent for greater coverage of the SB ostium. Other designs include dedicated stents for SB treatment at the beginning or end of the procedure, and devices using a bifurcated stent.

The enormous variety of coronary bifurcations, in terms of anatomy, vessel size, and the angles between the 3 components, and the possible coexistence of tortuosity proximal to the bifurcation and/or of more advanced coronary disease (calcification)—means that these devices have not yet met expectations. In any case, interventions using non-dedicated stents have significantly improved due to the growing expertise of the operators and refinement of the different elements contributing to the success of the intervention. The latter include new generations of coronary guidewires, minimal balloon profile, and a considerable improvement in fluoroscopy quality.

Considerations Regarding the Present Study

Revista Española de Cardiología has echoed the importance that the treatment of bifurcations has acquired among interventionists by publishing contributions of interest in recent years.^{6,12,13}

The article by Todaro et al⁴ in this number of the Journal is a creative attempt to validate the selection of a therapeutic strategy based on the complexity of the lesion at the coronary bifurcation. The authors compare use of a temporary stent in bifurcations in which at least one of its components is respected (bifurcations labeled as ‘other types’ in the Medina classification—Medina $\{101\}$, $\{001\}$, $\{011\}$, $\{110\}$, $\{100\}$, $\{010\}$ —[MO group]) to treatment with 2 stents in maximally complex lesions, $\{111\}$ Medina group 3 (M3). Our first point refers to the appropriateness of this grouping, given that it has not been confirmed that lesions $\{101\}$ and $\{011\}$, which are considered by many to be true bifurcations, are more “benign” than $\{111\}$. Nevertheless, the study design is justified by the increased plaque burden of $\{111\}$ lesions. However, given that in the series analyzed, the number of patients with an SB condition pertaining to the MO group is very small (8 patients), the study cannot shed any light in this regard.

Patients assigned to temporary stenting for less complex bifurcation lesions (MO group) had a high angiographic success rate in the SB (residual stenosis of 12%) as a second stent was only necessary in 3% of cases. These data indicate that temporary stenting is the optimal therapeutic strategy for this group of lesions. We agree with the authors that conventional stents should not be used in bifurcation lesions, even in less complex lesions, since they were the primary cause of adverse events observed in the series.

Regarding the question that we pose in the title of this editorial, we consider it useful to pay more attention to the baseline anatomical characteristics of coronary bifurcation lesions, based on the currently available simplified classification. This will help us to answer important questions such as that arising from the difference in immediate and long-term outcomes in the treatment of $\{111\}$ lesions compared to those in which the SB is diseased but neither of the 2 MV components is affected $\{011\}$ $\{101\}$.

ACKNOWLEDGMENTS

We would like to thank Charina Medina for her help in preparing and correcting the article.

REFERENCES

1. Pan M, Suárez de Lezo J, Medina A, Romero M, Hernández E, Segura J, et al. Simple and complex stent strategies for

- bifurcated coronary arterial stenosis involving the side branch origin. *Am J Cardiol.* 1999;83:1320-5.
- Lefèvre T, Louvard Y, Morice MC, Dumas P, Loubeyre C, Benslimane A, et al. Stenting of bifurcation lesions: classification, treatments, and results. *Catheter Cardiovasc Interv.* 2000;49:274-83.
 - Iakovou I, Ge L, Colombo A. Contemporary stent treatment of coronary bifurcations. *J Am Coll Cardiol.* 2005;46:1446-55.
 - Louvard Y, Thomas M, Dzavik V, Hildick-Smith D, Galassi AR, Pan M, et al. Classification of coronary artery bifurcation lesions and treatments: time for a consensus! *Catheter Cardiovasc Interv.* 2008;71:175-83.
 - Botas J. Lesiones en bifurcación: la última gran frontera del intervencionismo coronario. *Rev Esp Cardiol.* 2008;61:911-3.
 - Medina A, Suárez de Lezo J, Pan M. Una clasificación simple de las lesiones coronarias en bifurcación. *Rev Esp Cardiol.* 2006;59:183.
 - Colombo A, Moses JW, Morice MC, Ludwig J, Holmes DR, Spanos V, et al. Randomized study to evaluate sirolimus-eluting stents implanted at coronary bifurcation lesions. *Circulation.* 2004;109:1244-9.
 - Pan M, Suárez de Lezo J, Medina A, Romero M, Segura J, Pavlovic D, et al. Rapamycin-eluting stents for the treatment of bifurcated coronary lesions: a randomized comparison of a simple versus complex strategy. *Am Heart J.* 2004;148:857-64.
 - Steigen TK, Maeng M, Wiseth R, Erglis A, Kumsars I, Narbute I, et al; Nordic PCI Study Group. Randomized study on simple versus complex stenting of coronary artery bifurcation lesions: the Nordic bifurcation study. *Circulation.* 2006;114:1955-61.
 - Colombo A, Bramucci E, Saccà S, Violini R, Lettieri C, Zanini R, et al. Randomized study of the crush technique versus provisional side-branch stenting in true coronary bifurcations: the CACTUS (Coronary Bifurcations: Application of the Crushing Technique Using Sirolimus-Eluting Stents) Study. *Circulation.* 2009;119:71-8.
 - Latib A, Colombo A, Sangiorgi G. Bifurcation stenting: current strategies and new devices. *Heart.* 2009;95:495-504.
 - Suárez de Lezo J, Medina A, Martín P, Amador C, Delgado A, Suárez de Lezo J, et al. Hallazgos ultrasónicos durante el tratamiento percutáneo de lesiones coronarias en bifurcaciones. *Rev Esp Cardiol.* 2008;61:930-5.
 - Díaz de la Llera LS, Ballesteros SM, Guisado A, Aguilera A, Campos A, Sánchez A, et al. Tratamiento de las lesiones bifurcadas mediante técnica de crush T stenting: resultados inmediatos y a medio plazo. *Rev Esp Cardiol.* 2006;59:458-64.
 - Todaro D, Burzotta F, Trani C, Brugaletta S, de Vita M, Talarico GP, et al. Evaluación de una estrategia de implantación de stent único o doble para tratar lesiones bifurcadas basada en la clasificación de Medina. *Rev Esp Cardiol.* 2009;62:606-14.