

**Table**

Echocardiographic Parameters of Right Ventricular Function Prior to Implantation, at Hospital Discharge and After 1 Month and 6 Months of Follow-up in Patients Who Had Undergone Transcatheter Aortic Valve Implantation

|            | Baseline   | Discharge  | P     | 1 month    | P    | 6 months   | P  |
|------------|------------|------------|-------|------------|------|------------|----|
| TAPSE, mm  | 17.2 (2.5) | 17.6 (2.3) | .010  | 17.8 (2.4) | ns   | 17.8 (2.6) | ns |
| TDI, cm/s  | 12.2 (2)   | 12.9 (1.7) | <.001 | 13 (1.6)   | ns   | 13.2 (1.8) | ns |
| TAM, mm    | 15.6 (4.6) | 17.6 (4.4) | <.001 | 18.1 (4.8) | <.05 | 17.1 (7.3) | ns |
| RV strain  | -29 (6)    | -34 (4)    | <.001 | -36 (5)    | <.01 | -36 (5)    | ns |
| PASP, mmHg | 48 (12)    | 38 (9)     | <.001 | 40 (6)     | ns   | 38 (8)     | ns |

ns, not significant; PASP, pulmonary artery systolic pressure; RV strain, myocardial deformation measured by 2-dimensional speckle tracking echocardiography; TAM, tricuspid annular motion measured by 2-dimensional speckle tracking echocardiography; TAPSE, tricuspid annular plane systolic excursion using M mode echocardiography; TDI, tricuspid annular velocity measured using tissue Doppler imaging.

series would help to determine whether there are other factors, such as pacing, that could influence RVF during follow-up. The small number of patients and the lack of hemodynamic data obtained during the follow-up period, for the purpose of assessing their relationship to the echocardiographic measurements, would be limitations to the study.

In conclusion, there is an early, and significant, improvement in RVF, quantified by all the echocardiographic techniques, and that 2DSTE parameters show a further improvement throughout the first month, possibly due to the greater accuracy of this technique for the quantification of changes in ventricular function.

Miguel Puentes,\* Dolores Mesa, Martín Ruiz Ortiz, Mónica Delgado, Francisco Mazuelos, and Javier Suárez de Lezo

*Servicio de Cardiología, Hospital Universitario Reina Sofía, Córdoba, Spain*

\*Corresponding author:

E-mail address: [mpchiachio@hotmail.com](mailto:mpchiachio@hotmail.com) (M. Puentes).

Available online 11 May 2012

**REFERENCES**

1. Ewe SH, Ajmone Marsan N, Pepi M, Delgado V, Tamborini G, Muratori M, et al. Impact of left ventricular systolic function on clinical and echocardiographic outcomes following transcatheter aortic valve implantation for severe aortic stenosis. *Am Heart J*. 2010;160:1113-20.
2. León C, Suárez de Lezo J, Mesa D, Pan M, Ruiz M, Delgado M, et al. Evolución precoz de fugas en prótesis aórtica percutánea CoreValve: valoración ecocardiográfica. *Rev Esp Cardiol*. 2011;64:67-70.
3. Forsberg LM, Tamás E, Vánky F, Nielsen NE, Engvall J, Nylander E. Left and right ventricular function in aortic stenosis patients 8 weeks post-transcatheter aortic valve implantation or surgical aortic valve replacement. *Eur J Echocardiogr*. 2011;12:603-11.
4. Zhao Y, Lindqvist P, Nilsson J, Holmgren A, Näslund U, Henein MY. Trans-catheter aortic valve implantation-early recovery of left and preservation of right ventricular function. *Interact Cardiovasc Thorac Surg*. 2011;12:35-9.
5. Jurcut R, Giusca S, La Gerche A, Vasile S, Ghingina C, Voigt JU. The echocardiographic assessment of the right ventricle: what to do in 2010? *Eur J Echocardiogr*. 2010;11:81-96.
6. Ahmad H, Mor-Avi V, Lang RM, Nesser HJ, Weinert L, Tsang W, et al. Assessment of right ventricular function using echocardiographic speckle tracking of the tricuspid annular motion: comparison with cardiac magnetic resonance. *Echocardiography*. 2011. doi: 10.1111/j.1540-8175.2011.01519.x.

doi:10.1016/j.rec.2012.02.010

### **Percutaneous Treatment of Superior Vena Cava Syndrome After Pacemakers Electrodes Implantation and/or Surgical Correction of Congenital Heart Disease**

#### **Tratamiento percutáneo del síndrome de vena cava superior tras implantación de electrodos y/o cirugía de cardiopatías congénitas**

#### **To the Editor,**

Superior vena cava (SVC) syndrome arises when there is decreased or obstructed blood flow through the SVC.

Depending on the severity of the symptoms and the etiology, the treatment indicated can be surgery, at times with a venous-venous shunt. Balloon angioplasty and stenting have also been developed as an alternative to conventional surgery.

From January 1993 through December 2011, 5 patients presented in our hospital with this syndrome and all were treated percutaneously without any complications: 1 with balloon angioplasty,<sup>1</sup> 1 with a conventional stent, and 3 with polytetrafluoroethylene-coated stents. Table summarizes the main characteristics of patients and the treatment given.

With regard to the technique used, in cases with antegrade flow, approach was via the jugular vein with 5 or 6 Fr multipurpose

catheters (Cordis), through which a straight 260 cm straight guidewire of 0.035" diameter (Boston) was introduced. This in turn was snared in the right atrium (RA) by means of a 15-mm Goose Neck<sup>®</sup> loop (ev3). Venous-venous flow was established with a femoral approach.

In 2 patients with complete obstruction, we positioned a 15-mm Goose Neck<sup>®</sup> loop with a femoral approach at the base of the RA and introduced an inverted 0.014" diameter PT Graphix<sup>®</sup> coronary guidewire (Boston) through a multipurpose catheter. The guidewire was advanced with 2D angiographic guidance parallel to the pacemaker electrode. Once passed the obstruction, we snared the rigid end of the guidewire with the loop and lowered it to the RA (Fig. A). We then dilated with 2-, 3-, and 4-mm Maverick<sup>®</sup> coronary balloons (Boston) (Fig. B and C) before advancing the multipurpose catheter through the tunnel created and replaced the coronary guidewire with a 0.035" guidewire that was extracted via the femoral vein to establish the jugulofemoral bypass (Fig. D).

In the case of simple angioplasty, we used Balt<sup>™</sup> 7- and 15-mm balloons, introduced via the femoral artery. For stenting procedures, a femoral approach was also used. In all cases, predilatation was performed with 8- and 15-mm balloons (Fig. E and F) to introduce the 9 and 14 Fr Mullins sheaf (Cook) until reaching the SVC (Fig. G). Three 45-mm polytetrafluoroethylene coated stents

**Table**  
Baseline Clinical Characteristics and Angiographic Parameters for the Patients

|   | Patient 1  | Patient 2  | Patient 3  | Patient 4                                  | Patient 5   |
|---|--|--|--|--|---|
| Sex   | Male   | Male   | Male   | Male                                       | Female  |
| Age   | 12   | 47   | 68   | 74   | 10  |
| Clinical symptoms                                   | Jugular distension and severe superficial thoracic circulation | AVB; Edema of the neck and collateral venous circulation                     | AVB; facial congestion and collateral venous circulation | Brugada; impossible to place new electrode | Edema of the neck and collateral venous circulation                           |
| Obstruction   | Subtotal   | Long total (3 cm)  | Short total (2 cm)                                       | Subtotal                                   | Subtotal  |
| SVC/RA gradient                                     | 17   | 7  | 11   | 3  | 7   |
| Etiology  | APPVD  | APPVD; PM electrode  | PM electrode   | ICD electrode                              | APPVD   |
| Time from intervention until percutaneous treatment | 6 months   | 6 years since surgery and 4 months since PM                                  | 9 years 1 month  | 6 years 10 months                          | 8 years   |
| Type of surgery/PM                                  | Opening of atrial septum and tunneling with patch              | Widening of SVC with patch and drainage of anomalous veins via an AS; PM DDD | PM DDD   | ICD  | Widening of SVC with patch and opening atrial septum and tunneling with patch |
| Balloon   | Match® 7×40  | Balt® 20×50  | BiB® 18×50/9×40  | Maxi LD 14 × 30                            | Optapro 12×30   |
| Stenting  | No   | Covered Stent Numed 8Z 45 mm   | Covered Stent Numed 8Z 35 mm                             | Covered Stent Numed 8Z 45 mm               | Palmaz XD 29  |
| Post-dilatation balloon                             | Monofoil 15×40   | Mullins 18×30  | No   | Mullins 16×30 y 18×30                      | No  |

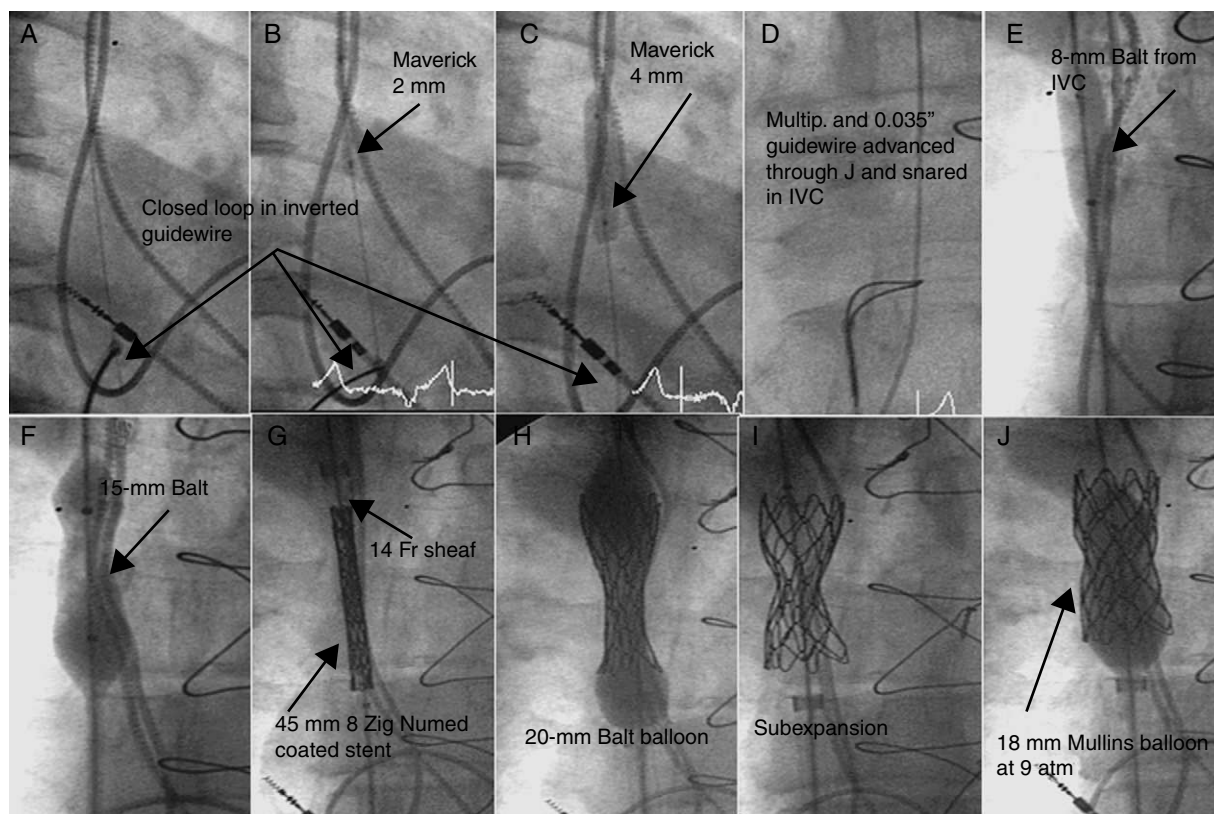
APPVD, abnormal partial pulmonary vein drainage; AS, atrial shunting; AVB, atrioventricular block; ICD, implantable cardioverter/defibrillator; PM, pacemaker; RA, right atrium; SVC, superior vena cava.

and 8 Zig® (Numed) and 1 Palmaz® XD 29 (Cordis) stents were used. These were mounted in their own balloons with the balloon/SVC ratio =1 (Fig. H, Table). In 2 cases, the underexpanded stent was redilated at high pressure (9 atm) with the Mullins balloon (Fig. I and J).

In all cases, the obstruction was completely removed and all patients were discharged from hospital after 24 h with antiplatelet

treatment for patients 1, 2, 4, and 5, and anticoagulant therapy for patient 3.

All patients have remained asymptomatic since the procedure, with a mean follow-up of 46.6 months (range, 9-120 months). After 1 year, the patency of the coated stent was confirmed by magnetic resonance imaging in patient 1 and chest computed tomography in patients 2 and 3. The pacemakers implanted in



**Figure.** Angiographic images of the procedure to remove the obstruction of the superior vena cava. IVC, inferior vena cava.

patients 2 and 3 were checked in the arrhythmia unit, and they were found to be working properly.

There is limited existing experience in the treatment of SVC obstruction, with an initially positive hemodynamic outcome in all patients treated by stenting and 78% of those treated by balloon angioplasty, without any long-term differences in outcome between the 2 percutaneous options.<sup>2</sup>

In patients who are also bearers of a cardiac pacing electrode, 3 strategies have been considered: simple balloon angioplasty, with the risk of restenosis due to recoil; initial withdrawal of the lead followed by removal of the obstruction by implantation of a coated or conventional stent; or placement of a new pacemaker.<sup>3,4</sup> This last option reduces the risk of restenosis and electrode damage, but it requires a new pacemaker to be placed.

One final measure consists of implanting a stent without removing the lead, which remains trapped between the venous wall and the stent.<sup>5</sup> With this strategy though, there is a risk of immediate pacemaker dysfunction due to the metallic scaffold, although there is now some experience on this point that shows normal function of pacemakers immediately after the procedure. However, the long-term effects arising because the electrode comes into repeated contact with the end of the stent are unknown. Cardiac motion itself could generate a point of fatigue because the lead is fixed by the stent.<sup>6</sup> It is also difficult to remove in the event of infection or thrombosis. This last approach could be of interest in patients in whom it is impossible or very difficult to remove the lead and/or in very elderly patients or those with a short life expectancy.

Our group proposes the use of coated stents in order to avoid possible acute and chronic deterioration of the electrode, given that the coating itself could help cushion the compression of the lead until neoendothelization has occurred.

Koldobika Garcia-San Roman,<sup>a,\*</sup> Juan Alcibar-Villa,<sup>a</sup>  
Roberto Blanco-Mata,<sup>a</sup> Natividad Peña-López,<sup>a</sup>  
Josune Arriola-Meabe,<sup>a</sup> and Iñigo Sainz-Godoy<sup>b</sup>

<sup>a</sup>Sección de Hemodinámica, Servicio de Cardiología, Hospital Universitario de Cruces, Baracaldo, Vizcaya, Spain

<sup>b</sup>Unidad de Arritmias, Servicio de Cardiología, Hospital Universitario de Cruces, Baracaldo, Vizcaya, Spain

\* Corresponding author:

E-mail address: [koldobika.garciasanroman@osakidetza.net](mailto:koldobika.garciasanroman@osakidetza.net)  
(K. Garcia-San Roman).

Available online 28 May 2012

## REFERENCES

1. Alcibar J, Oñate A, Cabrera A, Pastor E, Galdeano J, Inguanzo R, et al. Angioplastia de la obstrucción postquirúrgica de la vena cava superior. *Rev Esp Cardiol.* 1994;47:195–7.
2. Sánchez A, Gutiérrez F, Aroca A, Oliver JM. Tratamiento percutáneo de la obstrucción de vena cava superior tras cirugía de comunicación interauricular tipo seno venoso con drenaje venoso pulmonar anómalo parcial. *Rev Esp Cardiol.* 2010;63:748–50.
3. Chan AW, Bhatt DL, Wilkoff BL, Roffi M, Mukherjee D, Gray BH, et al. Percutaneous treatment for pacemaker-associated superior vena cava syndrome. *Pacing Clin Electrophysiol.* 2002;25:1628–33.
4. Bolad I, Karanam S, Mathew D, John R, Piemonte T, Martin D. Percutaneous treatment of superior vena cava obstruction following transvenous device implantation. *Catheter Cardiovasc Interven.* 2005;65:54–9.
5. Teo N, Sabharwal T, Rowland E, Curry P, Adam A. Treatment of superior vena cava obstruction secondary to pacemaker wires with balloon venoplasty and insertion of metallic stents. *Eur Heart J.* 2002;23:1465–70.
6. Slonim SM, Semba CP, Sze DY, Dake MD. Placement of SVC stents over pacemaker wires for the treatment of SVC syndrome. *J Vasc Interv Radiol.* 2000;11:215–9.

doi:10.1016/j.rec.2012.02.011