

Original article

Correlation Between Intracoronary Ultrasound and Fractional Flow Reserve in Long Coronary Lesions. A Three-dimensional Intracoronary Ultrasound Study

Ramon Lopez-Palop,^{a,*} Pilar Carrillo,^a Pilar Agudo,^a Araceli Frutos,^a Alberto Cordero,^a Miguel Angel López-Aranda,^b and David Ramos^c

^aUnidad de Hemodinámica, Sección de Cardiología, Hospital Universitario de San Juan de Alicante, San Juan de Alicante, Alicante, Spain

^bSección de Cardiología, Hospital Marina Baixa, Villajoyosa, Alicante, Spain

^cUnidad de Hemodinámica, Sección de Cardiología, Hospital General de Elche, Elche, Alicante, Spain

Article history:

Received 10 January 2013

Accepted 29 April 2013

Available online 25 July 2013

Keywords:

Coronary disease

Coronary angiography

Coronary angioplasty

Intracoronary ultrasound

Fractional flow reserve

Palabras clave:

Enfermedad coronaria

Angiografía coronaria

Angioplastia coronaria

Ecografía intracoronaria

Reserva fraccional de flujo

ABSTRACT

Introduction and objectives: Intracoronary ultrasound estimation of the functional significance of intermediate angiographic lesions has mainly been based on measuring the minimal lumen area. These estimates take no account of lesion length and pay insufficient attention to long coronary lesions.

Methods: We included 61 lesions with visual angiographic stenosis of 40% to 70% that required treatment with a ≥ 20 mm stent, studied with ultrasound and fractional flow reserve. Three-dimensional analysis of the ultrasound study was conducted offline and blinded to fractional reserve values. Angiographic and ultrasound parameters were correlated with fractional reserve.

Results: From the angiography we obtained data on mean reference diameter (2.87 [0.57] mm), length (29.8 [10.01] mm), and severity of stenosis (50.3% [8.7]%). Mean fractional flow reserve was 0.78 (0.09). We found a weak linear correlation (R) between fractional reserve and the ultrasound parameters that did not include lesion length: fractional reserve–minimal luminal area (R=0.4; P=.003). The correlation was stronger when lesion length was included: fractional reserve–volume of plaque (R=-0.65; P<.0005); fractional reserve–length/mean luminal area (R=0.73; P<.0005). The strongest correlation came from the product of mean stenosis by area multiplied by lesion length (R=-0.78; P<.0005).

Conclusions: In long coronary lesions, the correlation between ultrasound-measured minimal lumen area and functional significance is weak. In these cases, estimates of functional significance should incorporate lesion length or be derived from direct fractional flow reserve measurement.

© 2013 Sociedad Española de Cardiología. Published by Elsevier España, S.L. All rights reserved.

Correlación entre ecografía intracoronaria y reserva fraccional de flujo en lesiones coronarias largas. Un estudio de ecografía intracoronaria tridimensional

RESUMEN

Introducción y objetivos: La estimación mediante ecografía intracoronaria de la repercusión funcional de lesiones angiográficas intermedias se ha basado principalmente en la medición del área luminal mínima. Estas estimaciones no han tenido en cuenta la longitud de la lesión y no han sido estudiadas suficientemente en lesiones coronarias largas.

Métodos: Se incluyen 61 lesiones con un 40-70% de estenosis angiográfica visual y necesidad de stent ≥ 20 mm para su tratamiento, que se estudiaron con ecografía y reserva fraccional de flujo. Se realizó un análisis tridimensional *offline* del estudio de ecografía, ciego al valor de reserva fraccional. Se correlacionaron los parámetros angiográficos y ecográficos con la reserva fraccional obtenida.

Resultados: Se obtuvieron por angiografía valores medios de diámetro de referencia (2,87 \pm 0,57 mm; longitud, 29,8 \pm 10,01 mm) y grado de estenosis (50,3 \pm 8,7%). El valor medio de reserva fraccional de flujo fue 0,78 \pm 0,09. Se obtuvo una pobre correlación lineal (R) entre la reserva fraccional y los parámetros de ecografía que no incluían la longitud de la lesión: reserva fraccional–área luminal mínima (R = 0,4; p = 0,003); y mejor cuando se la tenía en cuenta: reserva fraccional – volumen de la placa (R = -0,65; p < 0,0005); reserva fraccional – longitud/área luminal media (R = 0,73; p < 0,0005). La mejor correlación se obtuvo con el producto estenosis media por área \times longitud de la lesión (R = -0,78; p < 0,0005).

Conclusiones: En las lesiones coronarias largas, el área luminal mínima medida por ecografía no tiene buena correlación con su repercusión funcional. En estos casos, la estimación de la repercusión funcional debe tener en cuenta la longitud de la lesión o realizarse por medición directa de la reserva fraccional de flujo.

© 2013 Sociedad Española de Cardiología. Publicado por Elsevier España, S.L. Todos los derechos reservados.

* Corresponding author: Vía Láctea 38, Urbanización La Glorieta, 30110 Churra, Murcia, Spain.

E-mail address: mlopezs@meditex.es (R. Lopez-Palop).

Abbreviations

FFR: fractional flow reserve
 IVUS: intracoronary ultrasound
 MLA: minimal lumen area
 QCA: quantitative coronary angiography

INTRODUCTION

The percentage of stenosis as obtained by angiography and the angiographic characteristics of the lesion continue to be useful and constitute the most commonly-used method of deciding on the revascularization of a coronary lesion. Their limitations are known, especially in the presence of complex anatomy and, above all, when the degree of angiographic stenosis is in the intermediate value range.^{1,2} The validity of fractional flow reserve (FFR)—measured by using an intracoronary pressure wire to determine the need to revascularize dubious or intermediate angiographically significant lesions—has been proven,^{3,4} leading to its increased use in recent years.⁵ The usefulness of intracoronary ultrasound (IVUS), also typically used to decide on revascularization when angiographic measures are unclear, has been questioned in recent studies that have compared IVUS with FFR.^{6–8}

Both coronary angiography (>70% stenosis by diameter) and IVUS⁹ (>4 mm² minimal lumen area [MLA] or >2 mm² minimal lumen diameter), the most frequently-used criteria to defer or to indicate revascularization, are based on measurements taken at a specific point on the lesion and take no account of lesion length. This is at odds with the classic flow dynamics equation, in which the resistance to flow across stenosis depends on length as well as stenosis diameter or significance.^{10,11} Neither does the decision based on focal measures of diameter or minimum areas take into account the existence of tandem lesions or diffusely-diseased segments that might condition flow, independently or in addition to the maximum degree of stenosis measured at a specific point.

In a series of long lesions, the present study compares IVUS parameters obtained using automatic withdrawal and 3-dimensional reconstruction with the FFR value determined in the same lesion.

METHODS

Design and Patients Enrolled

Prospective observational cohort study of patients undergoing coronary angiography for suspected coronary disease between 1 January 2009 and 31 May 2010. In all patients, a pressure wire and IVUS were used for decision-making on revascularization of a coronary lesion of intermediate severity (visually-estimated 40%–70% diameter stenosis) and long enough to require a ≥ 20 mm stent, if treatment was indicated.

We excluded lesions in a vessel irrigating the previously-infarcted zone, clearly unstable lesions (presence of thrombus, ulcerations, or <3 thrombolysis in myocardial infarction flow), patients contraindicated for adenosine, and those declining to give written informed consent. We also excluded patients in whom the lesion under study had other proximal or distal lesions with >20% visual stenosis. Finally, we excluded lesions that might trigger ST-segment elevation acute coronary syndrome, as a pressure wire is not normally used to evaluate this type of lesion in our laboratory.

Procedure

On deciding to perform the invasive study, the diagnostic catheter used for coronary angiography was replaced by a 6 Fr catheter guidewire. With this catheter, we repeated the projections that had obtained the best possible view of the lesion, showing the most visible stenosis with no superimposed branches or length loss due to curvature. Before introducing the intracoronary guidewire, all patients received intravenous sodium heparin at 100 UI/kg weight, if this had not previously been administered. Functional measurement was with a 0.014" intracoronary pressure wire (Pressure Wire, Radi Medical Systems; Uppsala, Sweden or PrimeWire, Volcano Corp.; San Diego, California, United States). The guidewire was calibrated externally and then advanced to the distal tip of the guiding catheter, checking the balance between the pressure curves in the catheter and in the FFR measuring system required it. After administering 200–300 μ g intracoronary d pressure wire, equalizing them as needed or with nitroglycerine, the guidewire was advanced until the sensor was at least 20 mm distal of the lesion under study. We measured FFR by administering 300–1200 μ g intracoronary adenosine, taking special care to avoid wedging the catheter in the coronary ostium after bolus injection of the drug. We determined FFR using the ratio, beat by beat, between mean aortic pressure at the tip of the guidewire catheter and mean pressure distal to the lesion recorded with the pressure wire, in maximum hyperemia. We measured FFR at least 3 times and used the lowest of the readings. We attempted a >600 μ g dose of intracoronary adenosine if a smaller amount failed to produce asystole ≥ 6 s.

Following the pressure wire study, we administered another 200–300 μ g intracoronary nitroglycerin and introduced the IVUS catheter (Atlantis Pro, Boston Scientific Co.; Boston, Massachusetts, United States) through the same intracoronary guidewire until it was at least 20 mm distal of the target lesion. We then performed automatic withdrawal at 0.5 mm/s, ending in the guiding catheter when <100 mm withdrawal length permitted this. Any decision on revascularization was at the discretion of the operator, based on functional and ultrasound study data.

Quantitative Coronary Angiography

Angiographic and ultrasound records were assessed offline by 2 experienced interventional cardiologists (RL and PC) who, although they might have participated in the procedures, were blinded to the functional assessment results when they were measured. Quantitative coronary angiography (QCA) was conducted with a contrast-filled catheter for calibration. Reference segments and percent stenosis were measured at end-diastole, in the projection showing the highest degree of severity. Lesion length was determined in the projection showing least shortening. Following a previous study,¹¹ we used direct measurements of length (L_{QCA}), proximal and distal reference diameter (obtained in the 5 mm adjacent to the proximal and distal limits of the lesion), minimal lumen diameter, (MLD_{QCA}), and mean lesion lumen diameter ($MLLD_{QCA}$) to calculate the following indices: reference diameter ($REFD_{QCA}$) = mean of the proximal and distal reference diameters; percent stenosis by maximum diameter ($\%S_{MAXD_{QCA}}$) = $100 \times (REFD_{QCA} - MLD_{QCA}) / REFD_{QCA}$; percent stenosis by mean diameter ($\%S_{MEDD_{QCA}}$) = $100 \times (REFD_{QCA} - MLLD_{QCA}) / REFD_{QCA}$; $\%S_{MAXD_{QCA}} \times L_{QCA}$; $\%S_{MEDD_{QCA}} \times L_{QCA}$; L_{QCA} / MLD_{QCA} ; and $L_{QCA} / MLLD_{QCA}$. Analysis was with QAngio XA 7.1.43.0 software (Medis Medical Imaging Systems; Leiden, The Netherlands).

Intracoronary Ultrasound Quantification Study

Three-dimensional quantification of the IVUS images was also blind to the functional assessment results. After automatic tracing of the vessel areas and artery lumen, frame-to-frame correction was performed. We considered the proximal and distal reference areas to be the mean areas of the 5 mm adjacent to the proximal and distal edges of the lesion. The points at which the lesion began and ended were judged by the interventional cardiologist taking the measurement, using angiographic anatomy references in the few cases when this was considered necessary.

The software automatically determined MLA after corrections were made for the intima and external elastic lamina edges. The software automatically calculates lesion plaque volume (vessel volume–lumen volume) and mean lumen area. For each lesion, we calculated theoretical conus truncus volume corresponding to the proximal and distal reference areas and lesion length (VOLTCONO_{IVUS}). We used direct measurements of length (L_{IVUS}), proximal and distal reference areas (MLA_{IVUS}), mean lesion lumen area (MLLA_{IVUS}), vessel volume in the lesion segment (VESVLS_{IVUS}), and lumen volume in the lesion segment (LVOLLS_{IVUS}) to calculate the following indices: reference area (REFA_{IVUS}) = mean proximal and mean distal reference areas; percent stenosis by maximum area (%SMAXA_{IVUS}) = 100 × (REFA_{IVUS} – MLLA_{IVUS})/REFA_{IVUS}; percent stenosis by mean area (%MEALS_{IVUS}) = 100 × (REFA_{IVUS} – MLLA_{IVUS})/REFA_{IVUS}; L_{IVUS}/MLA_{IVUS}; L_{IVUS}/MLLA_{IVUS}; %SMAXA_{IVUS} × L_{IVUS}; %MEALS_{IVUS} × L_{IVUS}; LVOLLS_{IVUS}/VESVLS_{IVUS}; and LVOLLS_{IVUS}/VOLTCONO_{IVUS}. Analysis was done with QCU-CMS 4.1 software (Medis Medical Imaging Systems; Leiden, The Netherlands).

Statistical Analysis

Quantitative variables are expressed as mean (standard deviation) and qualitative variables as absolute values and percentage. We performed several linear correlation studies to determine the Pearson correlation coefficient between observed FFR and the angiography and IVUS-derived indices. The predictive value of FFR <0.80 for the angiographic and ultrasound indices was estimated with the corresponding receiver operating characteristic (ROC) curve. From this, we estimated the best cutoff points for each parameter, with their corresponding sensitivity, specificity, and positive and negative predictive values. We chose the cutoff points for which the sum of the sensitivity and specificity values was highest. Analysis was with SPSS 15.0 for Windows (SPSS Inc.; Chicago, Illinois, United States) and SigmaPlot for Windows 11.0 (Systat Software Inc.; Chicago, Illinois, United States).

RESULTS

During the study period, our laboratory conducted 282 intracoronary pressure wire studies. Of these, 191 failed to meet the inclusion criteria, 18 presented several lesions in the vessel where the pressure wire study was performed, and in 12 patients the operator decided to perform only the pressure wire study. We finally included 61 lesions studied in 61 patients. Baseline patient characteristics are presented in Table 1. Up to 70% of patients had diabetes mellitus. In most of the patients, coronary angiography was indicated for acute coronary syndrome. In 69% of patients, we found angiographically significant lesions in a vessel other than that under study. In 43% of the lesions studied, FFR was <0.75; in 49%, FFR was <0.80.

Angiographic and ultrasound characteristics of the lesions, in general and according to whether or not they presented FFR <0.80, are shown in Table 2. Mean angiographic reference diameter was

2.87 (0.70) mm, with mean length of 29.80 (10.01) mm and mean degree of stenosis 50.25% (8.68)%. Lesions with <0.80 FFR had significantly smaller reference diameters, smaller minimum lumen diameters, and greater length. However, maximum and mean degree of stenosis were not significantly greater.

Mean ultrasound lesion MLA was 2.68 (1.06) mm², with mean length 34.39 (14.51) mm. Lesions with <0.80 FFR presented significantly smaller MLA, greater length, higher plaque volume, and other parameters associated with a higher degree of stenosis and greater length.

Length measured by IVUS was a mean 4.16 (12.8) mm greater than length measured by QCA (P=.025).

In linear regression models, linear correlation with FFR was weak for all the angiographic parameters analyzed (Table 3), although it was comparatively stronger in those that include the length of the lesion studied. Parameters including length also showed the best predictive values with FFR cutoff point <0.80, according to the corresponding ROC curves (Table 3). The best cutoff value for angiographically-derived percent stenosis was 45.6% stenosis (sensitivity, 86.2%; specificity, 48.3%) and 26.5 mm lesion length (sensitivity, 86.2%; specificity, 58.6%).

In linear regression models using the IVUS parameters analyzed and FFR value obtained (Table 4 and Fig. 1), the linear correlations were also weak, although they were stronger than those observed using the angiographic parameters. The strongest linear correlations and best predictive values with the ROC curve-derived FFR cutoff point <0.80 were found—as with the angiographic parameters—in

Table 1
Baseline Characteristics of Patients (n=61)

Age, years	69.7±10.3
Women	19 (30.0)
High blood pressure	47 (77.0)
Diabetes mellitus	43 (70.5)
Tobacco use	27 (44.3)
Hyperlipidemia	41 (67.2)
Previous infarction	12 (19.7)
Previous coronary revascularization	16 (23.0)
Percutaneous	15 (24.6)
Surgical	1 (1.2)
Previous CVA	2 (3.3)
Indication for coronary angiography	
STEACS	11 (18.0)
NSTEACS	31 (50.8)
Stable angina/silent ischemia	19 (31.1)
Number of diseased vessels*	0.89±0.80
No angiographically significant lesions	21 (34.4)
One diseased vessel	28 (45.9)
Two diseased vessels	10 (16.4)
Three diseased vessels	2 (3.3)
Diseased vessel other than the vessel under study*	
Left coronary artery	1 (1.6)
Left anterior descending artery	15 (24.6)
Circumflex artery	15 (24.6)
Right descending coronary artery	24 (39.3)
Angioplasty performed during the procedure	43 (70.5)
Lesions studied with FFR <0.75	26 (42.6)
Lesions studied with FFR <0.80	30 (49.2)

CVA, cerebrovascular accident; FFR, fractional flow reserve; NSTEACS, non-ST segment elevation acute coronary syndrome; STEACS, ST-segment elevation acute coronary syndrome.

Data are expressed as no. (%) or mean±standard deviation.

* Visual angiographic stenosis >70% in vessel other than the vessel being studied.

Table 2
Angiographic Characteristics of Lesions According to Fractional Flow Reserve Cutoff Point at 0.80

	Total	FFR \geq 0.80	FFR<0.80	P
<i>Patients</i>	61	31	30	
<i>Vessel studied</i>				
Left anterior descending artery	35 (57.4)	12 (38.7)	23 (76.7)	.003
Circumflex	17 (27.9)	13 (41.9)	4 (13.3)	.013
Right descending coronary artery	9 (14.8)	6 (19.4)	3 (10)	.303
<i>FFR</i>	0.78 \pm 0.09	0.85 \pm 0.04	0.71 \pm 0.05	<.0005
<i>Quantitative coronary angiography</i>				
Proximal reference diameter, mm	3.16 \pm 0.70	3.38 \pm 0.60	2.94 \pm 0.73	.015
Distal reference diameter, mm	2.58 \pm 0.56	2.78 \pm 0.57	2.39 \pm 0.48	.006
Reference diameter, mm	2.87 \pm 0.57	3.08 \pm 0.52	2.67 \pm 0.56	.005
Minimal lumen diameter, mm	1.43 \pm 0.38	1.59 \pm 0.38	1.27 \pm 0.31	.001
Mean lumen diameter, mm	2.25 \pm 0.46	2.42 \pm 0.45	2.09 \pm 0.43	.006
Length, mm	29.80 \pm 10.01	26.52 \pm 34.42	34.42 \pm 10.61	.003
Stenosis by maximum diameter, %	50.25 \pm 8.68	48.26 \pm 9.63	52.23 \pm 7.25	.082
Stenosis by mean diameter, %	21.37 \pm 7.27	21.42 \pm 7.35	21.32 \pm 7.32	.961
Length/minimal lumen diameter	22.93 \pm 10.33	17.53 \pm 7.23	28.32 \pm 10.23	<.0005
Length/mean lumen diameter	13.88 \pm 4.99	11.02 \pm 3.23	16.74 \pm 4.82	<.0005
<i>Ultrasound quantification</i>				
Proximal reference lumen area, mm ²	10.52 \pm 5.18	11.21 \pm 5.33	9.75 \pm 4.95	.309
Distal reference lumen area, mm ²	6.24 \pm 2.66	6.88 \pm 2.45	5.51 \pm 2.72	.061
Reference area, mm ²	8.38 \pm 3.68	9.05 \pm 3.66	7.63 \pm 3.63	.163
Minimal lumen area, mm ²	2.68 \pm 1.06	3.17 \pm 1.46	2.13 \pm 0.63	<.0005
Mean lumen area, mm ²	5.25 \pm 1.95	6.05 \pm 1.99	4.35 \pm 1.48	.001
Vessel volume (lesion), mm ³	411.88 \pm 211.16	349.11 \pm 178.20	482.19 \pm 226.14	.020
Lesion length, mm	34.39 \pm 14.51	27.14 \pm 11.81	42.50 \pm 13.01	<.0005
Lumen volume (lesion), mm ³	175.28 \pm 84.23	164.89 \pm 85.27	186.93 \pm 83.22	.347
Plaque volume, mm ³	236 \pm 137.41	184.21 \pm 97.24	295.26 \pm 153.26	.002
Mean stenosis (area), %	56.08 \pm 7.99	52.64 \pm 6.53	59.93 \pm 7.82	.001
Maximum stenosis (area), %	65.84 \pm 11.54	63.27 \pm 11.51	68.73 \pm 11.09	.086
Lumen volume/vessel volume (lesion)	0.44 \pm 0.08	0.48 \pm 0.06	0.40 \pm 0.08	<.0005
Lumen volume/cono trunk volume	0.66 \pm 0.14	0.70 \pm 0.12	0.62 \pm 0.15	.034
Mean stenosis (area) \times length	19.69 \pm 9.74	14.33 \pm 6.53	25.69 \pm 9.31	<.0005
Maximum stenosis (area) \times length	23.19 \pm 12.30	17.73 \pm 8.99	29.05 \pm 12.81	<.0005
Length/minimal lumen area	15.41 \pm 9.73	9.96 \pm 6.35	21.51 \pm 9.29	<.0005
Length/mean lumen diameter	7.61 \pm 4.44	4.93 \pm 2.94	10.62 \pm 3.90	<.0005

FFR, fractional flow reserve.

Data are expressed as no. (%) or mean \pm standard deviation.

those including lesion length: L_{IVUS} , $L_{IVUS}/MLA_{IVUS} \times L_{IVUS}/MLLA_{IVUS}$, $\%SMA_{IVUS} \times L_{IVUS}$, $\%MEALS_{IVUS} \times L_{IVUS}$. None of the volumetric parameters analyzed showed a strong correlation with the FFR values obtained.

The best cutoff points for each ultrasound parameter analyzed are shown in Table 5. Figure 2 shows the classification power of the angiographic ($\%SMA_{QCA}$ and L_{QCA}) and ultrasound (MLA_{IVUS} and L_{IVUS}) cutoff points, which were better for the ultrasound parameters chosen. Joint use of the two angiographic cutoff points (maximum degree of stenosis and length) to predict <0.80 FFR showed a sensitivity of 72.4%; specificity, 79.3%; positive predictive value, 77.8%; and negative predictive value, 74.2%. Joint use of the two ultrasound cutoff points ($MLA_{IVUS} <3.1$ mm² and $L_{IVUS} >32.5$ mm) had a sensitivity of 84.0%; specificity, 85.7%; positive predictive value, 84.0%; and negative predictive value, 85.7%.

DISCUSSION

The present study shows the limitations of IVUS to determine the functional significance of long coronary lesions that are

angiographically moderate and the importance of considering length as one of the most significant parameters when estimating the functional significance of this lesion type. Our observation of almost 50% of lesions with FFR <0.80 contrasts with the nearly 30% of functionally significant lesions observed in published series^{12,13} even though the lesions included have similar degrees of stenosis. These data alone underline the importance of lesion length to functional significance.

We have recently published a study showing the limitation of angiography and the importance of coronary lesion length for functional significance in a subgroup of lesions selected in exactly the same way as in the present study: angiographically moderate lesions of a length requiring the implantation of >20 mm stents should percutaneous treatment be undertaken.¹⁴ One limitation of this study derives from the inherent limitation of angiography to correctly determine degree of stenosis and extent of coronary disease. The IVUS increases the accuracy with which we can determine lesion diameter and minimum lesion area, the reference data needed to assess degree of stenosis and coronary lesion length.¹⁵⁻¹⁷ The present study shows that the predictive

Table 3

Analysis of Linear Correlation Between Angiographic Parameters and Fractional Flow Reserve Value. Areas Under the Receiver Operating Characteristic Curve for <0.80 Fractional Flow Reserve Cutoff Point

	Coefficient B	R	P	Area under ROC curve (95%CI)	P
Minimal lumen diameter	0.092±0.027	0.42±0.08	.001	0.72 (0.59-0.85)	.003
Mean lumen diameter	0.059±0.023	0.33±0.09	.030	0.71 (0.58-0.85)	.005
Length	-0.004±0.001	0.59±0.07	<.0005	0.77 (0.64-0.89)	.001
Stenosis by maximum diameter	-0.003±0.001	0.28±0.08	.034	0.64 (0.50-0.79)	.065
Stenosis by mean diameter	-0.003±0.002	0.42±0.08	.002	0.53 (0.38-0.67)	.74
Length/mean lumen diameter	-0.005±0.001	0.65±0.07	<.0005	0.84 (0.65-0.89)	<.0005
Length/mean lumen diameter	-0.011±0.002	0.69±0.06	<.0005	0.86 (0.76-0.95)	<.0005
Length×stenosis by maximum diameter	-0.007±0.007	0.62±0.07	<.0005	0.77 (0.65-0.94)	<.0005
Length×stenosis by mean diameter	-0.01±0.004	0.36±0.08	.006	0.69 (0.56-0.83)	<.0005

95%CI, 95% confidence interval; ROC, receiver operating characteristic.

Table 4

Analysis of Linear Correlation Between Ultrasound Parameters and Fractional Flow Reserve Value. Areas Under Receiver Operating Characteristic Curve for <0.80 Fractional Flow Reserve Cutoff Point

	Coefficient B	R	P	Area under ROC curve (95%CI)	P
Minimal lumen area	0.033±0.011	0.40±0.08	.003	0.77 (0.64-0.89)	.001
Mean lumen area	0.013±0.006	0.30±0.09	.030	0.76 (0.63-0.89)	.001
Length	-0.005±0.001	0.75±0.06	<.0005	0.86 (0.75-0.96)	<.0005
Stenosis by maximum area	-0.002±0.001	0.28±0.09	.046	0.65 (0.50-0.80)	.061
Stenosis by mean area	-0.005±0.001	0.42±0.08	.002	0.78 (0.65-0.90)	.001
Length/minimum lumen area	-0.006±0.001	0.71±0.06	<.0005	0.88 (0.78-0.97)	<.0005
Length/mean lumen diameter	-0.014±0.002	0.73±0.06	<.0005	0.89 (0.80-0.98)	<.0005
Length×stenosis by maximum area	-0.005±0.001	0.65±0.07	<.0005	0.83 (0.72-0.94)	<.0005
Length×stenosis by mean area	-0.007±0.001	0.78±0.06	<.0005	0.86 (0.77-0.96)	<.0005
Plaque volume	-0.0004±0	0.65±0.07	<.0005	0.71 (0.57-0.85)	.008
Lumen volume/vessel volume	0.481±0.136	0.44±0.08	.001	0.79 (0.66-0.92)	<.0005
Lumen volume/volume conus truncus	0.156±0.084	0.25±0.08	<.068	0.67 (0.52-0.82)	.034

95%CI, 95% confidence interval; ROC, receiver operating characteristic.

value of ultrasound parameters including lesion length can correlate better than angiography with intracoronary pressure wire-derived functional significance but they also present numerous classification errors, especially false positives.

The IVUS was proposed as a reliable means of estimating the functional significance of a coronary lesion. The most frequently used ultrasound parameter is MLA, with cutoff points that vary according to the type of lesion involved and the study.^{9,18-20} More recent studies point to IVUS limitations in determining functional significance of angiographically intermediate lesions with stenosis, although most center on focal ultrasound parameters (principally MLA) without taking account of lesion length. These studies include lesions of a mean length <15 mm^{7,8,21,22} and, reasonably enough in such short lesions, MLA may not be as important as in longer lesions and the linear correlation with FFR may be weak or nonexistent.

This deficient correlation between MLA_{IVUS} and FFR has been explained in different ways. Lesion length is one reason different FFR values occur despite identical MLA. The effect of length, of limited relevance in <15 mm lesions, can increase when assessing long coronary stenoses such as those in the present study. Other factors involved in direct functional assessment using FFR^{23,24} (myocardial territory size, microvascular disease, or vessel size) and not involved in purely anatomic assessment using IVUS may determine the deficient IVUS-FFR correlation despite their taking lesion length into account. For example, the existence of microvascular damage can limit maximum achievable coronary

flow in a specific myocardial territory because it impedes vasodilation, hence the possibly minimal contribution of stenosis (despite reduced MLA) to limiting maximum blood flow reaching this myocardial zone.

In a recent study, Lee et al.²⁵ established a length of 20 mm, together with an MLA value, as a cutoff point to estimate FFR <0.80 for <3 mm arteries. The predictive value of length in their study was lower than that found in ours, although the authors included lesions with a mean length of 17.9 mm, whereas in our study the lesions measured >34 mm. In the same study, a combination of focal parameters (MLA) with others that included lesion length (plaque burden and length itself) presented the best predictive value, as it did in our study.

We have found that a combination of the ultrasound parameters of <3.1 mm² MLA with >32.5 mm length was associated with >80% sensitivity, specificity, and predictive values. It is beyond the scope of the present study to analyze whether this cutoff point, composed of 2 joint measures, is equally valid for the 3 coronary vessels and all their segments. We believe the relatively high measures of diagnostic validity found for this composite cutoff point further underline the importance of taking lesion length into account if it is decided not to use the functional measure to indicate for revascularization of this lesion type.

Our study has failed to find a volumetric parameter that correlates well with FFR. Volume of plaque was the best parameter, ahead of those in which length intervened. The volumetric relations of lumen volume/vessel volume and

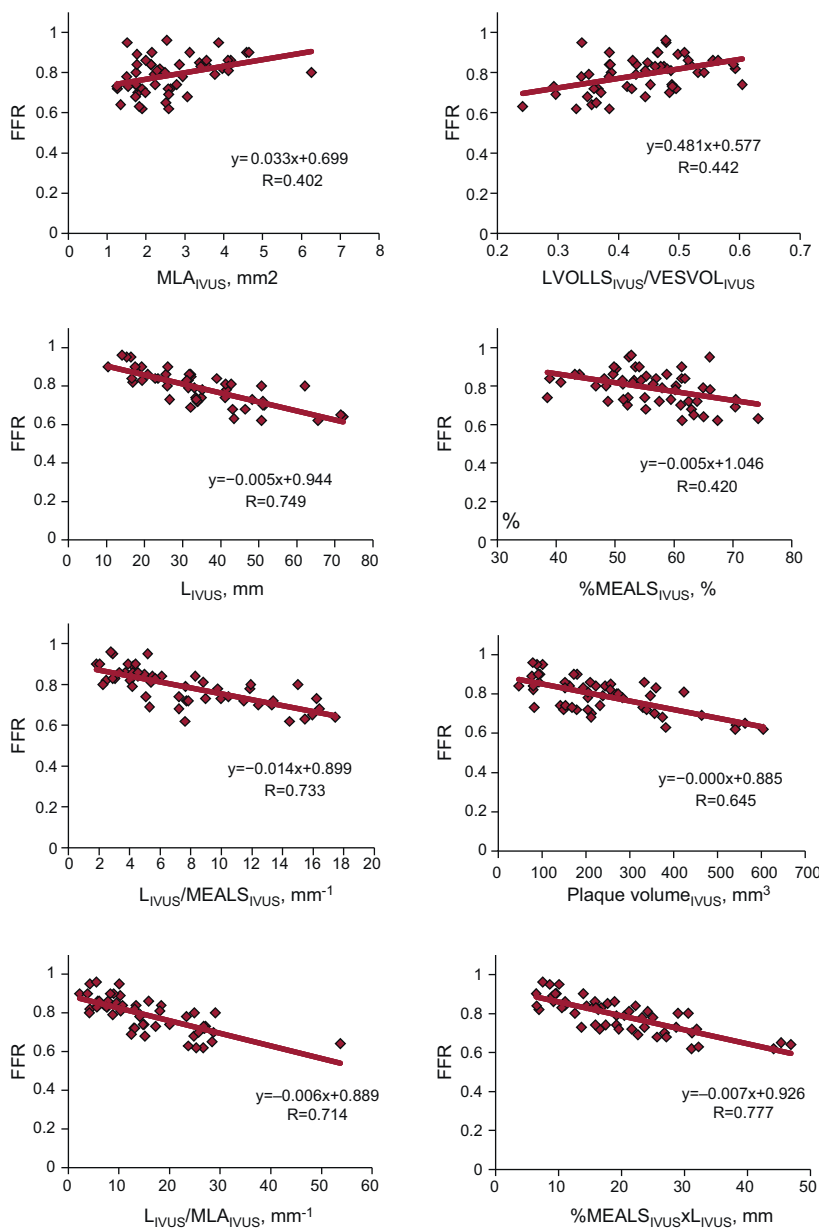


Figure 1. Graph of linear correlation between intracoronary ultrasound parameters and fractional flow reserve value. %MEALS, percentage by mean area of lesion stenosis; FFR, fractional flow reserve; IVUS, intracoronary ultrasound; L, lesion length; LVOLLS, lumen volume for lesion length; MLA, minimal lumen area; MLLA, mean lesion lumen diameter; VESVOL, vessel volume for lesion length.

lumen volume/theoretical conus truncus volume had a weak correlation with FFR. The presence of different degrees of artery remodeling can mean relations between volumes do not associate with increased deterioration of coronary flow. This weak correlation can even be considered as an expression of the adaptive significance of coronary artery remodeling in response to growth of atheromatous plaque.^{15,26}

Limitations

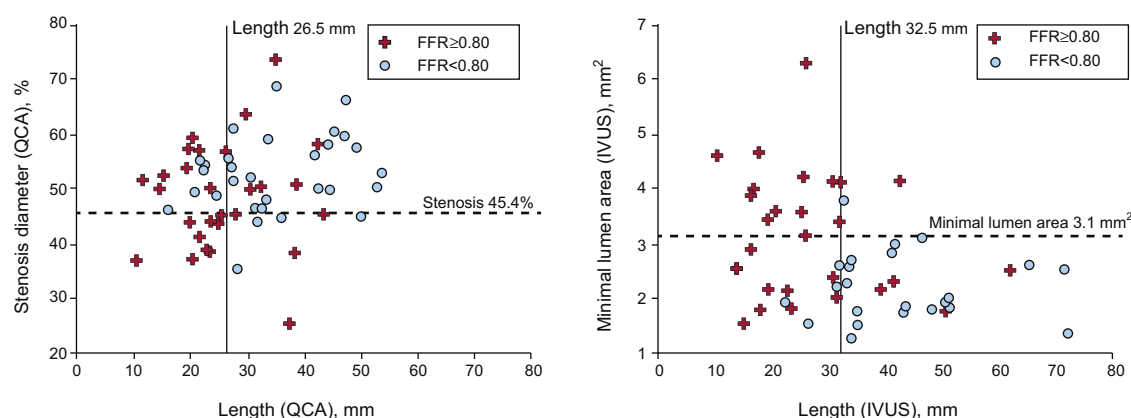
This single-center study only included long lesions, in the absence of other visible lesions proximal and distal to the lesion being studied, so the number of lesions included is small. Even so, we believe it is sufficient to show both the importance of

considering lesion length when estimating the functional significance of a lesion from ultrasound data and the limitations of IVUS for this type of estimate. The scarce number of lesions included prevents us from analyzing specific anatomic factors that could cause differences in the functional significance of lesions (proximal, medial or distal location, risk territory, etc.). Assessment of these anatomic factors requires a larger, and probably multi-center, study. Although lesion length was measured by experienced IVUS interventional cardiologists following the standard technique for this type of analysis, the sometimes diffuse character of coronary disease means a certain degree of variability or inaccuracy can arise in assessing where the lesion starts and finishes. We believe that being blinded to the FFR results when conducting IVUS analysis can compensate for the influence of the results on any possible measurement inaccuracy.

Table 5Best Cutoff Points to Obtain <0.80 Fractional Flow Reserve for Intracoronary Ultrasound Parameters Derived From Receiver Operating Characteristic Curves

	Cutoff point	Sensitivity, %	Specificity, %	PPV, %	NPV, %
Minimum lumen area	3.1 mm ²	96.0	53.6	67.4	93.1
Mean lumen area	4.6 mm ²	72.0	78.6	77.1	73.7
Length	32.1 mm	88.0	78.6	80.4	86.8
Stenosis by maximum area	71.8%	52.0	78.6	70.8	62.1
Stenosis by mean area	57.2%	68.0	78.6	76.0	71.1
Length/minimum lumen area	10.5 mm ⁻¹	96.0	71.4	77.1	94.7
Length/mean lumen area	6.7 mm ⁻¹	88.0	85.7	86.0	87.7
Length \times stenosis by maximum area	18 mm	92.0	64.3	72.0	88.9
Length \times stenosis by mean area	19 mm	80.0	82.1	81.8	80.4
Plaque volume	278.6 mm ³	48.0	89.3	81.8	63.2
Lumen volume/vessel volume	0.38	56.0	96.4	94.0	68.7
Lumen volume/volume conus truncus	0.56	44.0	89.3	80.4	61.5

NPV, negative predictive value; PPV, positive predictive value.

**Figure 2.** Graph of dispersion between most frequently used angiographic parameters (left panel) and ultrasound parameters (right panel), with the cutoff points for each parameter. Crosses, lesions with fractional flow reserve ≥ 0.80 ; circles, lesions with fractional flow reserve < 0.80 ; FFR, fractional flow reserve; IVUS, intracoronary ultrasound; QCA, quantitative coronary angiography.

CONCLUSIONS

In angiographically moderate lesions of >20 mm, IVUS-derived length is a parameter we should consider when estimating functional significance. This estimate should combine focal parameters of maximum stenosis and length, although the correlation with intracoronary pressure wire-derived FFR values is low. The joint selection of <3.1 mm² MLA and >32.5 mm length associates with a <0.80 FFR cutoff point with the best sensitivity and specificity values. When the principle object of study of an angiographically dubious lesion is to learn its possible functional significance, it seems advisable to use a direct FFR-derived measurement rather than an estimate based on anatomic data.

CONFLICTS OF INTEREST

None declared.

REFERENCES

1. Topol EJ, Nissen SE. Our preoccupation with coronary luminology: the dissociation between clinical and angiographic findings in ischemic heart disease. *Circulation*. 1995;92:2333-42.
2. Park SJ, Kang SJ, Ahn JM, Shim EB, Kim YT, Yun SC, et al. Visual-functional mismatch between coronary angiography and fractional flow reserve. *JACC Cardiovasc Interv*. 2012;5:1029-36.
3. Tonino PA, De Bruyne B, Pijls NH, Siebert U, Ikeno F, Veer M, et al. Fractional flow reserve versus angiography for guiding percutaneous coronary intervention. *N Engl J Med*. 2009;360:213-24.
4. De Bruyne B, Pijls NHJ, Kalesan B, Barbato E, Tonino PAL, Piroth Z, et al. Fractional flow reserve-guided PCI versus medical therapy in stable coronary disease. *N Engl J Med*. 2012;367:991-1001.
5. Diaz JF, De la Torre JM, Sabate M, Goicolea J. Registro Español de Hemodinámica y Cardiología Intervencionista. XXI Informe Oficial de la Sección de Hemodinámica y Cardiología Intervencionista de la Sociedad Española de Cardiología (1990-2011). *Rev Esp Cardiol*. 2012;65:1106-16.
6. Kang SJ, Lee JY, Ahn JM, Mintz GS, Kim WJ, Park DW, et al. Validation of intravascular ultrasound-derived parameters with fractional flow reserve for assessment of coronary stenosis severity. *Circ Cardiovasc Interv*. 2011;4:65-71.
7. Kang SJ, Ahn JM, Song H, Kim WJ, Lee JY, Park DW, et al. Usefulness of minimal luminal coronary area determined by intravascular ultrasound to predict functional significance in stable and unstable angina pectoris. *Am J Cardiol*. 2012;109:947-53.
8. Koo BK, Yang HM, Doh JH, Choe H, Lee SY, Yoon CH, et al. Optimal intravascular ultrasound criteria and their accuracy for defining the functional significance of intermediate coronary stenoses of different locations. *JACC Cardiovasc Interv*. 2011;4:803-11.
9. Abizaid AS, Mintz GS, Mehran R, Abizaid A, Lansky AJ, Pichard AD, et al. Long-term follow-up after percutaneous transluminal coronary angioplasty was not performed based on intravascular ultrasound findings: importance of lumen dimensions. *Circulation*. 1999;100:256-61.
10. Jaffe R, Halon DA, Roguin A, Rubinshtein R, Lewis BS. A Poiseuille-based coronary angiographic index for prediction of fractional flow reserve. *Int J Cardiol*. 2012 [Epub ahead of print] PII: S0167-5273(12)00133-7. doi:10.1016/j.ijcard.2012.01.100.

11. López-Palop R, Carrillo P, Cordero A, Frutos A, Mateo I, Mashlab S, et al. Effect of lesion length on functional significance of intermediate long coronary lesions. *Catheter Cardiovasc Interv.* 2013;81:E186-94.
12. Legalery P, Schiele F, Seronde MF, Meneveau N, Wei H, Didier K, et al. One-year outcome of patients submitted to routine fractional flow reserve assessment to determine the need for angioplasty. *Eur Heart J.* 2005;26:2623-9.
13. Lopez-Palop R, Carrillo P, Torres F, Lozano I, Frutos A, Avanzas P, et al. Resultados del empleo de la reserva fraccional de flujo en la valoración de lesiones no causales en el síndrome coronario agudo. *Rev Esp Cardiol.* 2012;65:164-70.
14. López-Palop R, Carrillo P, Cordero A, Frutos A, Mateo I, Mashlab S, et al. Effect of lesion length on functional significance of intermediate long coronary lesions. *Catheter Cardiovasc Interv.* 2013;81:E186-94.
15. Nissen SE, Yock P. Intravascular ultrasound: novel pathophysiological insights and current clinical applications. *Circulation.* 2001;103:604-16.
16. Tobis J, Azarbal B, Slavin L. Assessment of intermediate severity coronary lesions in the catheterization laboratory. *J Am Coll Cardiol.* 2007;49:839-48.
17. McDaniel MC, Eshthardi P, Sawaya FJ, Douglas Jr JS, Samady H. Contemporary clinical applications of coronary intravascular ultrasound. *JACC Cardiovasc Interv.* 2011;4:1155-67.
18. Takagi A, Tsurumi Y, Ishii Y, Suzuki K, Kawana M, Kasanuki H. Clinical potential of intravascular ultrasound for physiological assessment of coronary stenosis: relationship between quantitative ultrasound tomography and pressure-derived fractional flow reserve. *Circulation.* 1999;100:250-5.
19. Nishioka T, Amanullah AM, Luo H, Berglund H, Kim CJ, Nagai T, et al. Clinical validation of intravascular ultrasound imaging for assessment of coronary stenosis severity: comparison with stress myocardial perfusion imaging. *J Am Coll Cardiol.* 1999;33:1870-8.
20. Briguori C, Anzuini A, Airoldi F, Gimelli G, Nishida T, Adamian M, et al. Intravascular ultrasound criteria for the assessment of the functional significance of intermediate coronary artery stenoses and comparison with fractional flow reserve. *Am J Cardiol.* 2001;87:136-41.
21. Ben-Dor I, Torguson R, Gaglia Jr MA, Gonzalez MA, Maluenda G, Bui AB, et al. Correlation between fractional flow reserve and intravascular ultrasound lumen area in intermediate coronary artery stenosis. *EuroIntervention.* 2011;7:225-33.
22. Koh JS, Koo BK, Kim JH, Yang HM, Park KW, Kang HJ, et al. Relationship between fractional flow reserve and angiographic and intravascular ultrasound parameters in ostial lesions: major epicardial vessel versus side branch ostial lesions. *JACC Cardiovasc Interv.* 2012;5:409-15.
23. De Bruyne B, Sarma J. Fractional flow reserve: a review: invasive imaging. *Heart.* 2008;94:949-59.
24. Pijls NHJ, Sels JW. Functional measurement of coronary stenosis. *J Am Coll Cardiol.* 2012;59:1045-57.
25. Lee CH, Tai BC, Soon CY, Low AF, Poh KK, Yeo TC, et al. New set of intravascular ultrasound-derived anatomic criteria for defining functionally significant stenoses in small coronary arteries (results from Intravascular Ultrasound Diagnostic Evaluation of Atherosclerosis in Singapore [IDEAS] study). *Am J Cardiol.* 2010;105:1378-84.
26. Nissen SE. Application of intravascular ultrasound to characterize coronary artery disease and assess the progression or regression of atherosclerosis. *Am J Cardiol.* 2002;89:B24-31.