

**Poor Knowledge of Potentially Lethal Electrocardiographic Patterns in Asymptomatic Patients Among Noncardiologist Physicians, and Underestimation of Their Seriousness**



**Escaso conocimiento entre los médicos no cardiólogos de patrones electrocardiográficos asintomáticos potencialmente letales y subestimación de su gravedad**

**To the Editor,**

Correct electrocardiography (ECG) interpretation is essential to accurately diagnose cardiovascular disease.<sup>1,2</sup>

In everyday clinical practice, medical practitioners are faced with asymptomatic patients, in whom ECG findings play a critical role.<sup>4</sup> This is particularly relevant at the first medical contact, when the treating physician may not be a cardiologist.<sup>2,3</sup> The diagnostic capacity of ECG for detecting serious clinical conditions has been extensively validated, but no study has analyzed physicians' abilities to interpret the ECGs.

Our objective was to investigate the ability of noncardiologist specialist physicians and residents to interpret potentially fatal ECG tracings, taking into account their diagnosis and their subjective perception of the seriousness of the findings.

We distributed a questionnaire to the participants of an electrocardiography course for physicians from different health-care facilities and specialties, which took place in a tertiary hospital. The questionnaire was distributed arbitrarily, following the layout of the classroom. The questionnaire contained 10 diagnostic tracings of potentially fatal conditions that can present with different signs and symptoms, although all patients were asymptomatic at the time of recording. The ECGs had been selected by a group of clinical cardiologists in advance. There were several different questionnaire models, with the tracings arranged in a different order to avoid potential exchange of information between participants.

We asked attendees for their diagnosis and a subjective evaluation of the seriousness of the ECG findings, on a scale of 0 (benign) to 100 (fatal). Prior to this, 2 specialist cardiologists had assessed the possible diagnoses and their seriousness. Concordance was excellent between the cardiologists for the subjective evaluation of seriousness, as demonstrated by the intraclass correlation coefficient (0.92; confidence interval, 0.66-0.98) (Figure).

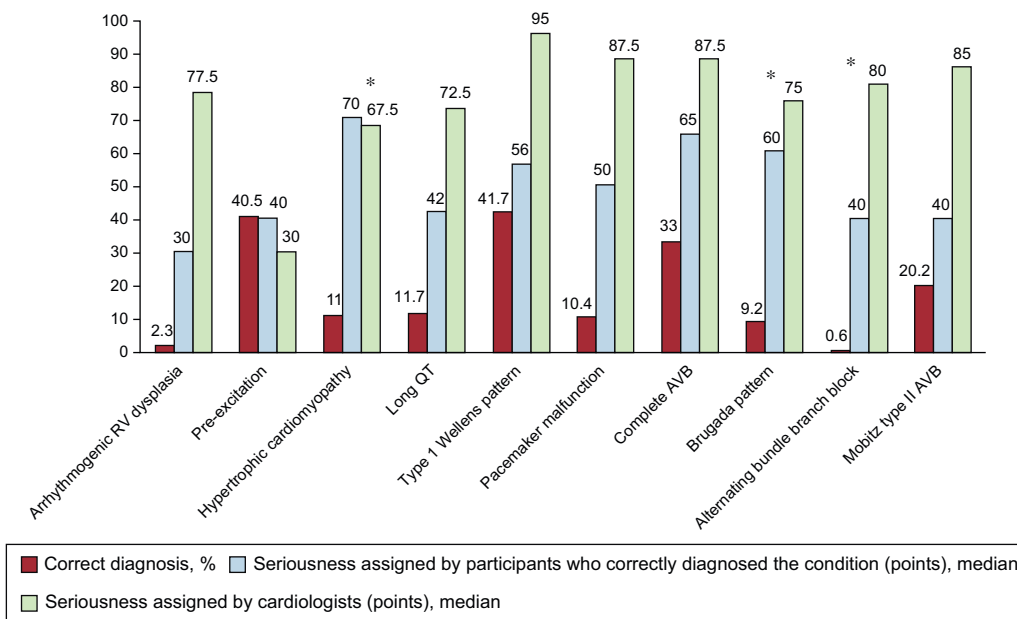
For each ECG, 2 points were awarded to each participant who correctly identified the condition, 1 point was awarded to those who accurately evaluated the seriousness, and 0 points were awarded to those with completely incorrect responses. Consequently, each participant could score a possible maximum of 30 points (3 for each ECG multiplied by 10 ECG in total).

In total, 163 physicians participated in the study: 117 were women (71.8%), 112 were residents (68.7%), and the median age was 27 years. Of the residents, 56 (50%) were second-year residents, and 31 (27.6%) were third-year residents. Twenty-eight (17.2%) were primary care physicians and 23 (14.1%) were emergency physicians (in these last 2 groups, the median age was 44 years).

The mean participant score for correct diagnosis was remarkably low at 6 points. There were no differences between the sexes ( $P = .47$ ) or type of physician (residents, primary care physicians, and emergency physicians) ( $P = .21$ ).

The percentage of correct diagnoses was extremely low for all 10 ECGs. It ranged from 0.6% for alternating bundle branch block to 41.7% for the classic pattern of Wellens syndrome (which signifies a critical lesion in the left anterior descending artery).

Figure shows the percentage of correct diagnoses. It also shows the median score assigned to each ECG by the physicians who correctly diagnosed the condition, based on their subjective perception of seriousness, as well as the median score assigned by the cardiologists, for comparison. The correlation was zero for the subjective evaluation of seriousness between the cardiologists



**Figure.** Percentage of correct diagnoses, median seriousness score assigned by the participants who correctly diagnosed the condition, and median seriousness score assigned by the cardiologists. AVB, atrioventricular block; RV, right ventricular.\*Insignificant differences between the median seriousness score assigned by the participants and by the cardiologists ( $P > .05$ ).

and the participants that correctly diagnosed the condition (-0.09; confidence interval, -0.24 to 0.33).

There were statistically significant differences in the subjective perception of seriousness between the participants and the experts for most of the ECGs. The exceptions were the ECGs showing hypertrophic cardiomyopathy, Brugada pattern, and alternating bundle branch block (Figure).

Of note was a tracing with a QT interval of 580 ms, which received a median seriousness score of 42 (0–100) from the participants who diagnosed it correctly, compared with 72.5 (70–75) from the cardiologists.

For Wellens syndrome, the median seriousness score from the participants was 56 (20–100), while the cardiologists assigned a score of 90.

Of the bradyarrhythmias, 2 deserve comment: complete atrioventricular block and Mobitz type II second degree atrioventricular block. Complete atrioventricular block was correctly identified by just 33%, with a median seriousness score of 65 (20–100) vs 87.5 (85–90) according to the experts. Mobitz type II was correctly diagnosed by 20.2% of participants, with a median seriousness score of 40 (10–90) compared with 85 (80–90) from the cardiologists.

Figure shows how similar discrepancies occurred in the interpretation of all 10 ECG tracings.

Despite the fundamental role played by ECG in the diagnosis of cardiovascular disease, these findings demonstrate that ECG interpretation is in need of remedial action, particularly for physicians who are the first medical contact. This conclusion is in line with the findings of other available studies.<sup>3</sup>

Our study shows an extremely low percentage of correct diagnoses and poor recognition of electrocardiographic patterns in the population analyzed.

Another even more shocking finding of this study is the incorrect perception of seriousness for several potentially fatal cardiovascular conditions that are diagnosed primarily from ECG. On many occasions, these were considered harmless, highlighting

the need for training programs for such physicians on the correct interpretation of ECGs.

Juan Carlos Gómez-Polo,<sup>a,\*</sup> Javier Higuera Nafria,<sup>a</sup> Pedro Martínez-Losas,<sup>a</sup> Victoria Cañadas-Godoy,<sup>b</sup> Ramón Bover-Freire,<sup>c</sup> and Julián Pérez-Villacastín<sup>b</sup>

<sup>a</sup>Servicio de Cardiología, Hospital Clínico San Carlos, Madrid, España

<sup>b</sup>Unidad de Electrofisiología y Arritmias, Servicio de Cardiología, Hospital Clínico San Carlos, Madrid, España

<sup>c</sup>Unidad de Insuficiencia Cardiaca, Servicio de Cardiología, Hospital Clínico San Carlos, Madrid, España

\*Corresponding author:

E-mail address: [jc.gomezpolo@gmail.com](mailto:jc.gomezpolo@gmail.com) (J.C. Gómez-Polo).

Available online 27 October 2016

## REFERENCES

- Martínez-Losas P, Higuera J, Gómez-Polo JC, Cañadas-Godoy V. The influence of clinical information in electrocardiogram interpretation. *Rev Clin Esp.* 2016; 216:171–172.
- Retana-Puigmartí M, De Frutos-Echaniz E, Castro-Acuña-Baixaui I, Val-Jimenez A. Diagnosticar un síndrome de Brugada: el papel de la atención primaria. *Semergen.* 2011;37:569–572.
- Borrás X, Murga N, Fiol M, Pedreira M. Novedades en cardiología clínica: electrocardiografía de superficie, enfermedad vascular y mujer y novedades terapéuticas. *Rev Esp Cardiol.* 2010;63(Supl 1):3–16.
- Kadish AH, Buxton AE, Kennedy HL, Knight BP, Mason JW, Schuger CD, et al. ACC/AHA clinical competence statement on electrocardiography and ambulatory electrocardiography. *Circulation.* 2001;104:3169–3178.

<http://dx.doi.org/10.1016/j.rec.2016.09.021>  
1885-5857/

© 2016 Sociedad Española de Cardiología. Published by Elsevier España, S.L.U. All rights reserved.

## Subacute Retrograde TAVI Migration Successfully Treated With a Valve-in-valve Procedure



### Migración retrógrada subaguda de TAVI solucionada con un procedimiento valve-in-valve

#### To the Editor,

A 65-year-old man with severe degenerative aortic stenosis (Figures 1A and 2A) and preserved systolic function was evaluated by the Heart Team of our institution for surgical aortic valve replacement vs transcatheter aortic valve implantation (TAVI). A TAVI procedure was chosen because he had a heavily calcified aorta. He underwent a preprocedure computed tomography angiography to select the route, prosthesis type and prosthesis size for the procedure. He had no significant peripheral artery disease, and we therefore chose a transfemoral route. His aortic root area measured 430 mm<sup>2</sup> on computed tomography angiography. The aortic root diameter measured on 2-dimensional transesophageal echocardiography was 24 mm. We therefore chose an Edwards Sapien XT 26 mm valve. The TAVI procedure was undertaken (under transesophageal echocardiography) with balloon predilation, and no postdilation, without immediate complications. The balloon was prepared according to the

manufacturer's recommendations (ie, no soft preparation, by using a lower amount of balloon saline, was undertaken). Fluoroscopy (Figure 1A and Figure 1B, and video 1 and video 2 of the supplementary material), and transesophageal and transthoracic echocardiography (Figure 2A and Figure 2B, and video 3 and video 4 of the supplementary material) confirmed appropriate prosthetic positioning with a mean gradient of 9 mmHg and absence of relevant paravalvular leaks. However, 24 hours after the procedure, a follow-up transthoracic echocardiogram was performed and a de novo mean aortic gradient of 42 mmHg was revealed (Figure 2C). The prosthetic valve had migrated retrogradely into the outflow tract, thereby uncovering the native valve, which was functioning again (Figure 1C and Figure 2D, video 5 and video 6 of the supplementary material). We reviewed the case and concluded that the prosthetic valve might have been positioned slightly too low and might have suboptimally expanded during the procedure. After discussion of the case in the Heart Team, a valve-in-valve procedure with a second 26-mm Edwards Sapien XT valve was chosen (Figure 1D and video 7 of the supplementary material). This enabled successful treatment of the aortic stenosis and prevented further migration of the original prosthesis. The patient was discharged 3 days after the second procedure and at 1 year of follow-up he is free of heart failure and the prosthesis is working adequately.