

## Scientific letters

### Effects of Ivabradine on Heart Rate and Hemodynamic Parameters in a Swine Model of Cardiogenic Shock



#### *Efectos de la ivabradina en la frecuencia cardíaca y los parámetros hemodinámicos en un modelo porcino de shock cardiogénico*

#### To the Editor,

Cardiogenic shock (CS) after myocardial infarction is associated with elevated mortality.<sup>1</sup> There are few specific treatment options. Catecholamine administration may worsen tachycardia because decreased tissue perfusion may lead to reduced ventricular efficiency and increased oxygen consumption.<sup>2</sup> Preliminary data indicate that ivabradine may offer a benefit in situations of severe tachycardia and shock, probably as a result of lower oxygen consumption and oxidative stress,<sup>2</sup> although the hemodynamic effects of the drug in this context are unknown. For this reason, prior to administration of the drug in a clinical setting, we deemed it appropriate to study whether ivabradine administration may induce hemodynamic changes in a porcine model of CS after myocardial infarction.

Ten female large white pigs (mean weight, 32.8 [2.2] kg) were included. The animals were anesthetized with propofol and fentanyl and the anterior descending artery was occluded for 45 minutes by inflation of an angioplasty balloon. To simulate CS after infarction, noradrenalin, dobutamine, and saline solution were administered until a postreperfusion heart rate (HR) of  $\geq 90$  bpm and a pulmonary wedge pressure  $> 18$  mmHg were achieved. Amiodarone was also administered at the same dose in both study groups to prevent ventricular fibrillation, which is a frequent occurrence in porcine models of acute ischemia. Hemodynamic parameters (blood pressure, HR, cardiac output, pulmonary artery pressure, pulmonary wedge pressure, and central venous pressure) were monitored with Swan-Ganz catheters inserted into the aorta via the carotid and jugular approach. After balloon deflation, each animal was stabilized for 15 minutes prior to subsequent open-label randomization to the control group ( $n = 5$ ) or ivabradine group ( $n = 5$ ). Ivabradine was administered intravenously as a slow intravenous bolus at a dose of 0.3 mg/kg and was diluted in distilled water at a concentration  $\geq 12$  mg/mL.<sup>3</sup> The placebo group received the equivalent volume of saline solution. The aforementioned hemodynamic parameters were then measured at 15-minute intervals after infusion of drug/placebo. The study variables are

expressed as mean  $\pm$  SD. The means were compared with the Student *t* test for independent data with a normal distribution and with the Fisher-Pitman test for independent variables with a nonparametric distribution.

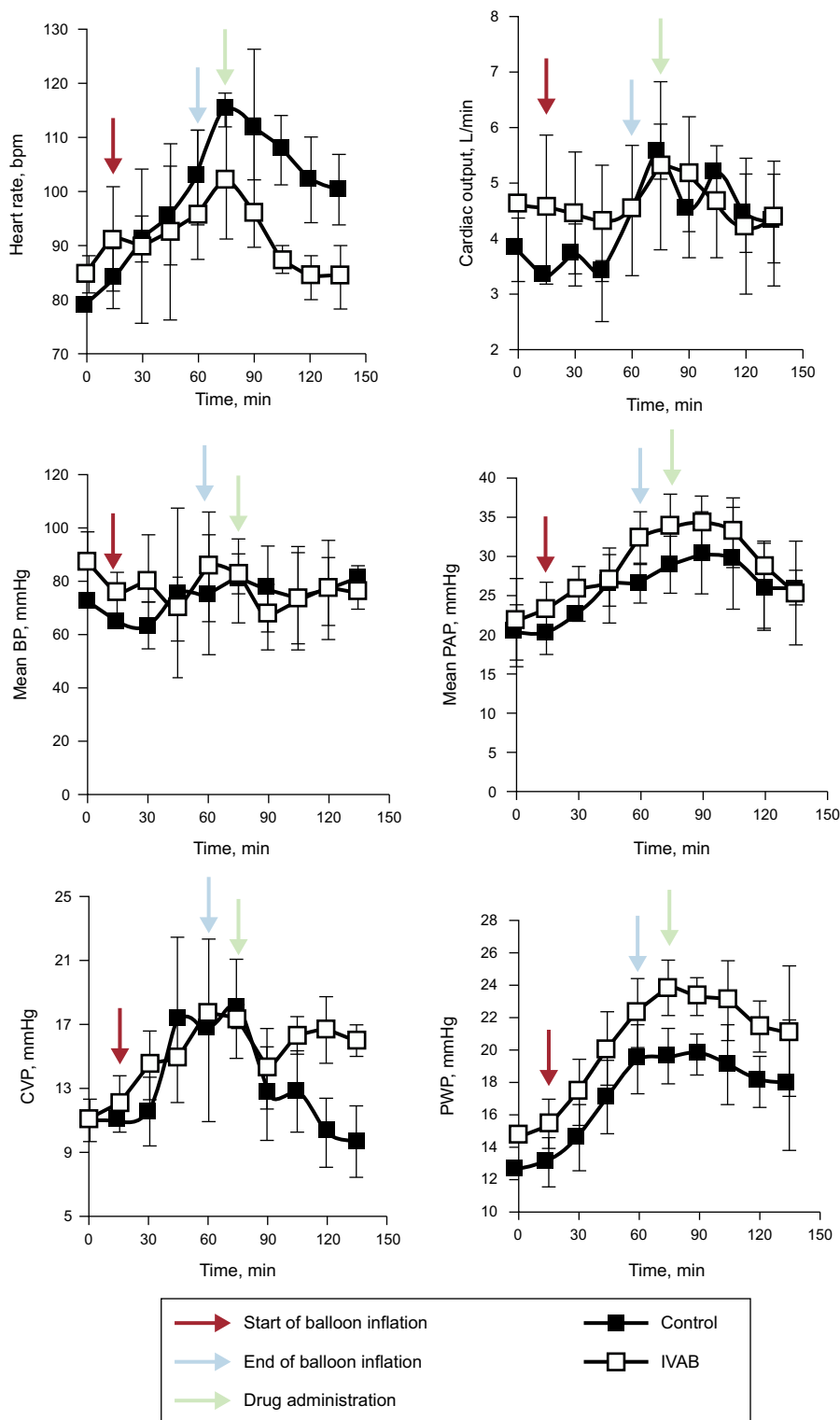
Ivabradine administration was associated with a significant decrease in HR (Figure 1; median [confidence interval] absolute reduction in HR at 15 minutes, 21 [21 to 25] vs  $-1$  [ $-5$  to 0] bpm;  $P = .04$ ), with no change in blood pressure, pulmonary artery pressure, or cardiac output. Tidal volume significantly increased in the ivabradine group (Figure 2; tidal volume at 15 minutes, 63.7 [5.7] vs 43.7 [7.5] mL;  $P < .01$ ). However, the decrease in HR was not accompanied by a reduction in pulmonary wedge pressure, and an increase in central venous pressure was observed compared with the control group (Figure 1). The numerical differences recorded in the 2 groups before administration of the study drug were not significant for any variables.

Although findings indicative of the efficacy and safety of ivabradine in acute heart failure after infarction have been reported,<sup>4,5</sup> the hemodynamic impact of reducing HR in CS is not known. Our results are in agreement with those of Bakkehaug et al.<sup>6</sup> in a porcine model of CS. The model used by those authors, however, was more invasive than ours—medial sternotomy was performed—and is thus less readily applicable in clinical practice. An additional consideration, at least as important as the type of model, is that the animals in that study were not randomized; rather, the animals were their own control. An effect of spontaneous improvement occurring after induction of ischemia and reperfusion of the infarction cannot therefore be ruled out.

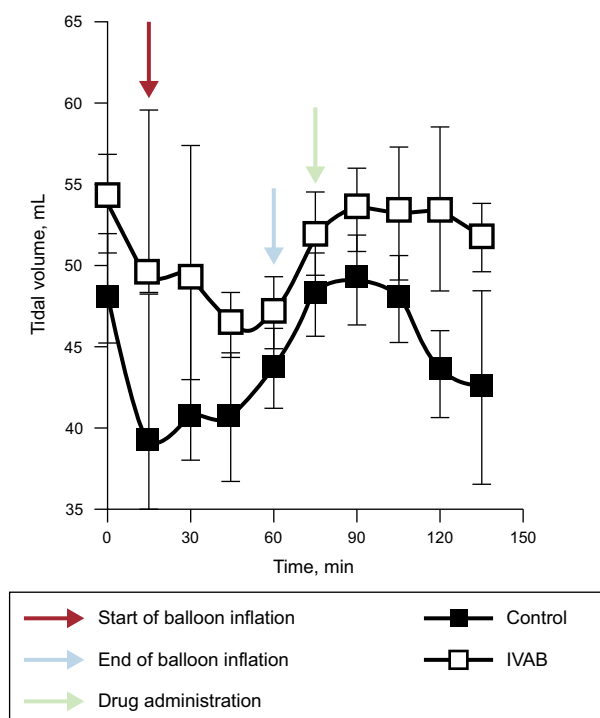
In conclusion, ivabradine administered in a porcine model of CS induced by ischemia/reperfusion can reduce HR without significantly compromising cardiac output and can therefore increase tidal volume. However, this reduction in HR does not appear to reduce filling pressures. Before randomized clinical studies are conducted, we believe broader knowledge is required, in particular with a view to establishing whether this pharmacological strategy is of any value in reducing oxidative stress and myocardial damage in CS after myocardial infarction.

#### FUNDING

This study received a grant from the Spanish Society of Cardiology project for Basic Research in Cardiology in 2015.



**Figure 1.** Change in hemodynamic parameters in ivabradine and control groups. Black arrows represent the start of coronary occlusion; blue arrows the end of occlusion; and red arrows the start of drug or placebo infusion. BP, blood pressure; bpm, beats per minute; CVP, central venous pressure; IVAB, ivabradine; PAP pulmonary artery pressure; PWP, pulmonary wedge pressure.



**Figure 2.** Change in tidal volume in ivabradine and control groups. IVAB, ivabradine.

## CONFLICTS OF INTEREST

Servier provided ivabradine in powder for intravenous administration free of charge.

## Prevention of Cardiac Adverse Events Associated With the Use of Drugs in Patients With Severe Mental Illness: Case Report



### Prevención de eventos adversos cardiacos relacionados con el uso de fármacos en pacientes con trastorno mental grave: a propósito de un caso

#### To the Editor,

Patients with severe mental disorders often have several comorbidities and are prescribed a large number of drugs, making them susceptible to the development of medication-related problems.<sup>1</sup> Care of their physical health should form part of the overall therapeutic approach used in this population. Preventive measures should be established to avert risk situations, such as the development of potentially life-threatening adverse events, including those associated with the use of medication that affects cardiac conduction. It is important for physicians to be aware of the adverse cardiovascular events associated with drugs used for cardiac and noncardiac diseases, as well as their potential interactions.<sup>2</sup>

Conduction changes can manifest as an acquired prolongation of the QT interval on electrocardiography (ECG), the most common cause of which is drug-related. This abnormality is a recognized risk factor for sudden death secondary to ventricular arrhythmias such as *torsade de pointes*.<sup>3</sup> In addition, conduction blocks can occur, as has been described with lithium use.<sup>4</sup> Complete left

Marina Pascual Izco,<sup>a</sup> Borja Castejón,<sup>b</sup> María José Piedras,<sup>b</sup> José Luis Zamorano,<sup>a</sup> Marcelo Sanmartín,<sup>a,\*</sup> and Carlos Zaragoza<sup>b</sup>

<sup>a</sup>Servicio de Cardiología, Hospital Universitario Ramón y Cajal (IRYCIS)-Universidad de Alcalá de Henares, Madrid, Spain

<sup>b</sup>Servicio de Cardiología, Unidad de Investigación del Hospital Ramón y Cajal (IRYCIS)-Universidad Francisco de Vitoria, Madrid, Spain

\* Corresponding author:

E-mail address: [msanfer@me.com](mailto:msanfer@me.com) (M. Sanmartín).

Available online 28 March 2017

## REFERENCES

- Núñez-Gil JJ, Martín-Reyes R, Bardají A, et al. Ischemic heart disease and acute cardiac care 2015: a selection of topical issues. *Rev Esp Cardiol.* 2016;69:408–414.
- Roubille F, Lattuca B, Busseuil D, et al. Is ivabradine suitable to control undesirable tachycardia induced by dobutamine in cardiogenic shock treatment? *Med Hypotheses.* 2013;81:202–206.
- Verrier RL, Silva AFG, Bonatti R, et al. Combined actions of ivabradine and ranolazine reduce ventricular rate during atrial fibrillation. *J Cardiovasc Electrophysiol.* 2015;26:329–335.
- Pascual Izco M, Alonso Salinas G, Sanmartín Fernández M, et al. Clinical experience with ivabradine in acute heart failure. *Cardiology.* 2016;134:372–374.
- Barillà F, Pannarale G, Torremeo C, et al. Ivabradine in patients with ST-elevation myocardial infarction complicated by cardiogenic shock: a preliminary randomized prospective study. *Clin Drug Investig.* 2016;36:849–856.
- Bakkehaug JP, Naesheim T, Torgersen Engstad E, et al. Reversing dobutamine-induced tachycardia using ivabradine increases stroke volume with neutral effect on cardiac energetics in left ventricular post-ischaemia dysfunction. *Acta Physiol.* 2016;218:78–88.

<http://dx.doi.org/10.1016/j.rec.2017.03.009>

1885-5857/

© 2016 Sociedad Española de Cardiología. Published by Elsevier España, S.L.U. All rights reserved.

bundle branch block (LBBB) is a potential marker of severe heart disease, although in some cases it is not associated with recognizable structural abnormalities and shows a characteristic ECG pattern.

We describe the case of a 56-year-old man. Strict cardiac monitoring carried out in our center detected a new-onset LBBB during formoterol treatment that resolved following discontinuation of the drug. The ECG monitoring protocol used has been included in the 2015 Best Practice Guidelines of the Spanish Health System, approved by the SHS Interterritorial Council of April 13, 2016.<sup>5</sup>

The patient had no hypertension and no known heart disease. He was diagnosed with paranoid schizophrenia, hyperthyroidism, and chronic obstructive pulmonary disease, and was receiving treatment with clotiapine 40 mg/d, clorpromazine (40 mg/mL) 250 drops/d, levothyroxine 25 µg/d, omeprazole 20 mg/d, acetylcysteine 600 mg/d, calcium/vitamin D 600 mg/1000 IU in 1 tablet/d, and ipratropium bromide 18 µg/d. Follow-up ECGs since admittance had yielded normal results, with the last recordings showing sinus rhythm at 70 bpm, no atrioventricular or branch blocks, and QTc 399 ms.

At 7 months following admittance to our center, the patient was started on treatment with formoterol 12 µg/d because of poor control of his chronic obstructive pulmonary disease, with symptom improvement. At 7 days after initiation of this treatment, ECG examination detected a new-onset LBBB, with sinus rhythm at 70 bpm and QTc 438 ms (Figure). In addition, the patient reported chest pain at rest of 5 minutes' duration on various occasions