

Image in cardiology

Austrian Syndrome Complicated With a Periannular Mitral Abscess



Síndrome de Austrian complicado con absceso perianular mitral

Nina Soto Flores,* Nuria Vallejo Camazón, and Antoni Bayes-Genis

Servicio de Cardiología, Hospital Universitari Germans Trias y Pujol, Centro de Investigación Biomédica en Red de Enfermedades Cardiovasculares (CIBERCV), Badalona, Barcelona, Spain

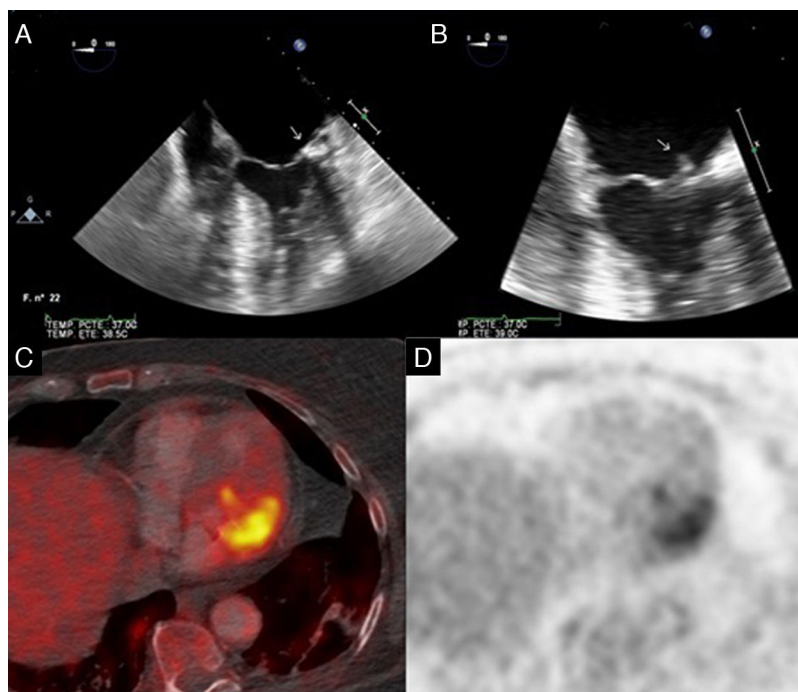


Figure.

A 75-year-old woman with a penicillin allergy was admitted due to a left basal pneumonia and reduced level of consciousness, with blood cultures positive for pneumococcus. Polymerase chain reaction of the cerebrospinal fluid was also positive for pneumococcus. A few days after admission, she had an ischemic stroke of possible cardio-embolic etiology. Transthoracic and transesophageal echocardiography showed an 18×7 mm vegetation at the level of the posterior leaflet (P2 segment) that was causing mild mitral regurgitation, as well as an echodense image at the level of the posterior mitral annulus coinciding with a calcified area, suggestive of a mitral periannular abscess. On the basis of these findings, a diagnosis was made of Austrian syndrome (endocarditis, meningitis, and pneumonia, all caused by *Streptococcus pneumoniae*). The patient received treatment with vancomycin and progressed well. Follow-up echocardiography showed a reduction in the size of the vegetation (Figures A and B), with persistence of the possible abscess and the mild mitral regurgitation. ^{18}F -fluorodeoxyglucose positron emission tomography/computed tomography (PET/CT) was performed (Figures C and D), which confirmed the diagnosis of an abscess extending into the myocardium. It was decided to perform mitral valve replacement with a biological prosthesis, and during the procedure the diagnosis was again confirmed.

We would like to highlight the usefulness of PET/CT in confirming the diagnosis of mitral periannular abscess, a finding that is difficult to evaluate, particularly when there is mitral annulus calcification. In this case, it was especially pertinent because it supported the decision to operate on a clinically stable patient who had progressed well on echocardiography and microbiology.

* Corresponding author:

E-mail address: nina.sotoflores@gmail.com (N. Soto Flores).

Available online 18 May 2017