

Image in cardiology

Prenatal Diagnosis of Anomalous Origin of the Right Pulmonary Artery



Diagnóstico prenatal de origen anómalo de arteria pulmonar derecha

Raquel García-Delgado,^{a,*} Francisco Jiménez,^b and Hipólito Falcón^c

^a Servicio de Obstetricia y Ginecología, Hospital Universitario Materno Infantil de Canarias, Las Palmas de Gran Canaria, Spain

^b Servicio de Cardiología, Hospital Universitario Insular de Gran Canaria, Las Palmas de Gran Canaria, Spain

^c Unidad de Cardiología Pediátrica, Hospital Universitario Materno Infantil de Canarias, Las Palmas de Gran Canaria, Spain

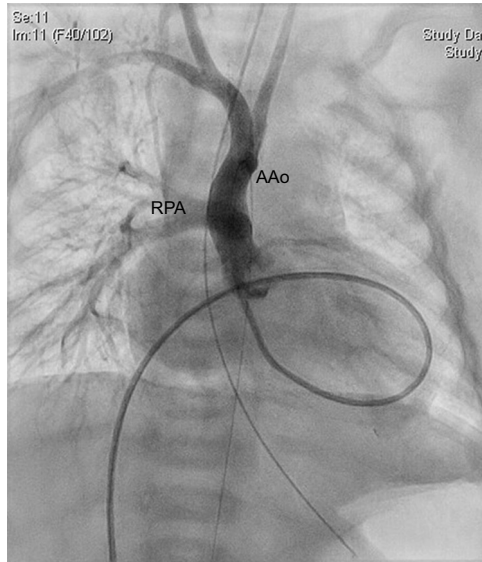


Figure 1.

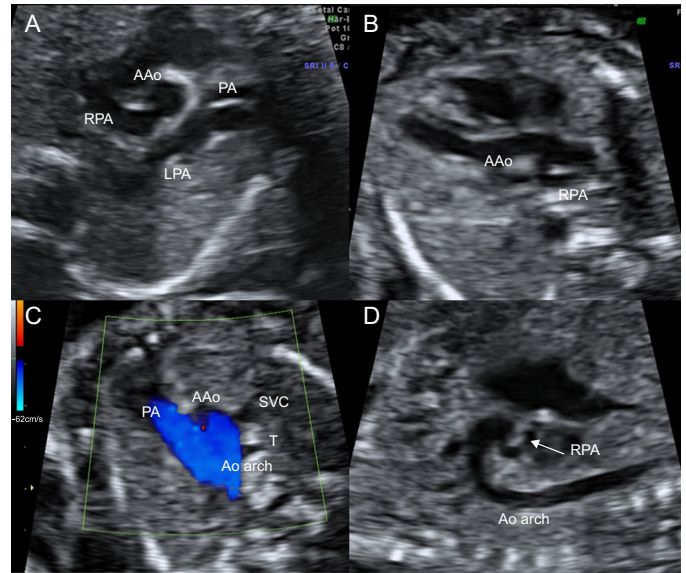


Figure 2.

Anomalous origin of a pulmonary artery (PA) branch in the ascending aorta (AAo) is an extremely rare congenital anomaly. Only 7 cases of prenatal diagnosis of this condition have been published, and it has a high level of morbidity and mortality if not diagnosed and repaired early. Its prenatal diagnosis is therefore essential.

Here, we present the case of a pregnant woman with a mistaken fetal prenatal diagnosis of complete transposition of the great arteries. Postnatal echocardiography revealed an anomalous origin of the right pulmonary artery (RPA) in the AAo, which was confirmed using cardiac catheterization (Figure 1). Surgery was successfully performed when the infant was 1 month old.

A retrospective review of the prenatal ultrasound scans showed that this anomaly was visible in the short-axis view of the right ventricle, the left ventricular outflow tract view, and the sagittal view of the aortic arch (Figure 2). The common PA emerges from the right ventricle and gives rise to the left pulmonary artery (LPA). The RPA originates in the posterior wall of the AAo (Figure 2A), next to the aortic valve (Figure 2B), which leads to the 3 vessel-trachea view (PA, AAo, superior vena cava [SVC], T) being strictly normal in this patient, unlike in most published cases (Figure 2C, SVC). The origin of the RPA in the posterior wall of the AAo is clearly seen in the sagittal view of the aortic arch (Figure 2D). Crossing of the great arteries always rules out a diagnosis of complete transposition of the great arteries. In the case presented here, the absence of clinical suspicion of this condition prevented its correct diagnosis in the prenatal period.

* Corresponding author:
E-mail address: rgdelgado1@hotmail.com (R. García-Delgado).
Available online 17 May 2017