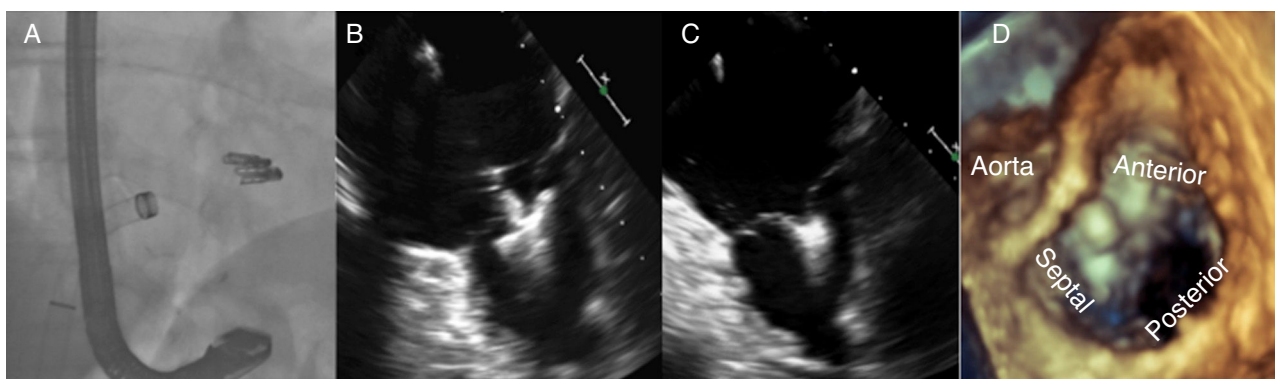

**Figure 2.** Fluoroscopy image sequence and TEE during the procedure. A: final position of the clips on fluoroscopy. B and C: 2D-TEE image at 0° with the clip open and closed after the attachment of the anterior (left) and septal (right) leaflets. D: 3D-TEE image showing the final position of the second clip between the anterior and septal leaflets. 2D, 2-dimensional; 3D, 3-dimensional; TEE, transesophageal echocardiography.

associated with greatest reduction in TR<sup>2,4</sup>; as is the case with the mitral valve, the intervention also aims not to induce moderate or severe valve stenosis (mean gradient > 3 mmHg); b) the second is the tricuspid approach of a 24-Fr system designed to be directed at the mitral valve; although right femoral access is the most frequently-used, transjugular access has been proposed, which, despite being awkward for the operator and the difficulty of controlling hemostasis after the procedure, permits direct access to the valve<sup>2</sup>; and c) imaging assessment of the tricuspid valve with 2-dimensional/3-dimensional (2D/3D) TTE/TEE is another of the major challenges of this technique: the need to learn and obtain planes that allow good visualization of the valve anatomy and provide a reliable guide during the procedure is a crucial element in the development of this technique.

In conclusion, the use of MitraClip in the tricuspid position appears to have promising results, but new registries need to be published to determine whether the treatment is safe and effective in the long-term.

#### CONFLICTS OF INTEREST

M. Hernández-Enríquez has received a training grant in interventional cardiology from the Spanish Society of Cardiology. X. Freixa and M. Sitges are proctors for Abbot Medical.

Xavier Freixa,\* Marco Hernández-Enríquez, Laura Sanchís, Ander Regueiro, Manel Sabaté, and Marta Sitges

Servicio de Cardiología, Instituto Cardiovascular, Hospital Clínic de Barcelona, Universidad de Barcelona, Barcelona, Spain

\* Corresponding author:

E-mail address: [Freixa@clinic.cat](mailto:Freixa@clinic.cat) (X. Freixa).

Available online 13 September 2017

#### REFERENCES

1. Campelo-Parada F. Percutaneous treatment of the tricuspid valve disease: new hope for the forgotten valve. *Rev Esp Cardiol.* 2017;70:856–866.
2. Nickenig G, Kowalski M, Hausleiter J, et al. Transcatheter treatment of severe tricuspid regurgitation with the edge-to-edge MitraClip technique. *Circulation.* 2017;135:1802–1814.
3. Hernández-Enríquez M, Freixa X, Sanchís L, et al. *Concurso de Casos Clínicos en Cardiopatía Estructural para Residentes en Cardiología.* Salamanca: La gótica digital; 2017:161–166.
4. Vismara R, Gelpi G, Prabhu S, et al. Transcatheter edge-to-edge treatment of functional tricuspid regurgitation in an ex vivo pulsatile heart model. *J Am Coll Cardiol.* 2016;68:1024–1103.

<http://dx.doi.org/10.1016/j.rec.2017.08.006>  
1885-5857/

© 2017 Sociedad Española de Cardiología. Published by Elsevier España, S.L.U. All rights reserved.

#### Transcatheter Tricuspid Repair With MitraClip in a Patient With a Failing De Vega Annuloplasty



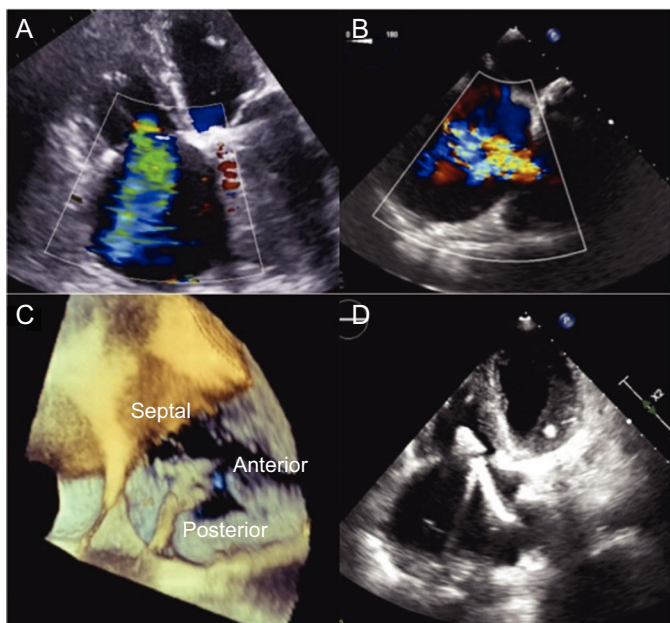
#### Reparación transcatóter de tricúspide con MitraClip en paciente con anuloplastia de De Vega fallida

#### To the Editor,

A 71-year-old woman was admitted to our hospital for right-sided heart failure (HF). The patient had a history of rheumatic disease and 2 surgical interventions. In 1976, she underwent open mitral commissurotomy, and in 2003 she underwent mitral valve replacement with a mechanical prosthesis and De Vega annuloplasty of the tricuspid valve. During follow-up, symptoms and signs of right HF appeared, and echocardiographic studies documented normal functioning of the mitral prosthesis with severe tricuspid regurgitation (TR) due to restriction of the tricuspid valve leaflets (Figure 1A). She was given medical treatment, but after an initial response period, the clinical picture

recurred with severe limitation of quality of life. The multidisciplinary team decided that she was at very high risk for conventional surgery, but offered her the possibility of a MitraClip implant in the tricuspid position to treat her advanced HF symptoms. Prior to the procedure, transesophageal echocardiography (TEE) was performed, confirming the severity of TR and that the tricuspid leaflets were adequate for device implantation (Figure 1B). The catheterization procedure showed only mild pulmonary hypertension and the absence of coronary lesions.

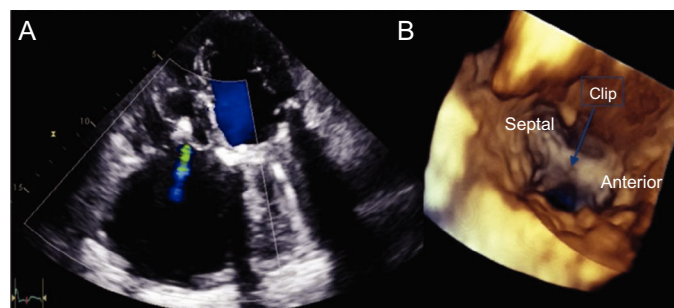
The procedure was performed under general anesthesia and was guided by TEE. The guide catheter was advanced through the femoral vein and was positioned in the lower area of the right atrium. The clip was introduced into the guide catheter using the Munich technique and was then advanced into the atrium to the straddling position. Subsequently, it was deflected toward the tricuspid valve using wheel A and was guided to capture the anterior and septal leaflets. However, as the clip was advanced into the ventricle to capture the leaflets, we could not achieve an



**Figure 1.** Screening echocardiography and procedure. A and B, TTE and TEE show severe TR. C, positioning and orientation of the clip in 3-dimensional TEE to capture the anterior and septal leaflets. D, grasping in TTE. TEE, transesophageal echocardiography; TTE, transthoracic echocardiography; TR, tricuspid regurgitation.

adequate visualization of the clip arms using the acoustic shadow of the mitral prosthesis. To achieve sufficient image quality, we switched to transthoracic echocardiography, and finally grasp was achieved with a significant reduction in TR to grade mild-moderate (Figure 1C-D). After confirmation of adequate leaflet insertion and the tricuspid gradient (1 mmHg), the clip was released. Post-procedural control echocardiography showed that the clip was in position with a double-orifice tricuspid valve and residual mild-moderate TR (Figure 2A-B).

Functional TR comprises more than 90% of cases of TR and is mainly due to annular dilatation and right ventricular growth secondary to left-sided heart disease.<sup>1</sup> Patients with TR and secondary HF are often highly symptomatic because of decreased cardiac output and peripheral and abdominal congestion. In addition, the presence of moderate or severe TR is associated with high mortality, regardless of biventricular function and pulmonary



**Figure 2.** Result of the procedure. A, mild tricuspid regurgitation on pre-discharge echocardiography. B, 3-dimensional TTE showing the bridge formed by the clip between the septal and anterior leaflets. TTE, transthoracic echocardiography.

pressures.<sup>2</sup> Current data support tricuspid repair at the time of surgical intervention on the left heart; however, reintervention for persistent or recurrent TR is associated with high morbidity and mortality.<sup>3,4</sup> Likewise, a significant proportion of patients are left with recurrent TR following tricuspid repair surgery, particularly after De Vega or Peri-Guard annuloplasty.<sup>4</sup> In these cases, transcatheter tricuspid repair techniques have emerged as an alternative to conventional surgery.<sup>1</sup> Of these techniques, that with the greatest clinical experience is MitraClip implantation in the tricuspid position. Several series have shown that its use in this position is associated with high procedural success rates, few complications, and clear symptomatic improvement.<sup>5,6</sup> In the largest series published, the success rate was 97%, with 1 clip in 42% of patients. There were also reductions in the diameter of the tricuspid valve and in pulmonary pressures.<sup>6</sup> Failed annuloplasty may be a suitable niche for the use of this device. The MitraClip increases the area of coaptation and, because the length of the leaflets is usually adequate, the use of even 1 clip can provide satisfactory results, as observed in our case. In conclusion, MitraClip implantation in the tricuspid position in patients with recurrent TR after De Vega annuloplasty is a safe and effective technique to reduce TR.

## CONFLICTS OF INTEREST

R. Estevez-Loureiro is a proctor for MitraClip.

Rodrigo Estévez-Loureiro,<sup>a,\*</sup> Tomás Benito-González,<sup>a</sup> Javier Gualis,<sup>b</sup> Armando Pérez de Prado,<sup>a</sup> Miguel Rodríguez-Santamarta,<sup>a</sup> and Felipe Fernández-Vázquez<sup>a</sup>

<sup>a</sup>Servicio de Cardiología, Complejo Asistencial Universitario de León, León, Spain

<sup>b</sup>Servicio de Cirugía Cardíaca, Complejo Asistencial Universitario de León, León, Spain

\*Corresponding author:

E-mail address: roiestev@hotm@il.com (R. Estévez-Loureiro).

Available online 19 October 2017

## REFERENCES

- Campelo-Parada F, Lairez O, Carrie D. Percutaneous treatment of the tricuspid valve disease: new hope for the “forgotten” valve. *Rev Esp Cardiol.* 2017;70:856–866.
- Nath J, Foster E, Heidenreich PA. Impact of tricuspid regurgitation on long-term survival. *J Am Coll Cardiol.* 2004;43:405–409.
- Kim YJ, Kwon DA, Kim HK, et al. Determinants of surgical outcome in patients with isolated tricuspid regurgitation. *Circulation.* 2009;120:1672–1678.
- McCarthy PM, Bhudia SK, Rajeswaran J, et al. Tricuspid valve repair: durability and risk factors for failure. *J Thorac Cardiovasc Surg.* 2004;127:674–685.
- Braun D, Nabauer M, Massberg S, Hausleiter J. Transcatheter repair of primary tricuspid valve regurgitation using the MitraClip system. *JACC Cardiovasc Interv.* 2016;9:e153–e154.
- Nickenig G, Kowalski M, Hausleiter J, et al. Transcatheter treatment of severe tricuspid regurgitation with the edge-to-edge MitraClip technique. *Circulation.* 2017;135:1802–1814.

<http://dx.doi.org/10.1016/j.rec.2017.09.013>

1885–5857/

© 2017 Sociedad Española de Cardiología. Published by Elsevier España, S.L.U. All rights reserved.